

# Medial Approach for the Mastopexy with Breast Implants. (MAMBI)

Olivares E. Jorge, Martinez B. Luz Ariana

Department of Aesthetic Surgery, Instituto de Estudios Superiores en Medicina, Mexico.

jocirplast@hotmail.com

*\*Corresponding Author: Jorge Olivares E, Instituto de Estudios Superiores en Medicina, Mexico.*

## Abstract

**Background and Objective:** Describes a technique with an initial approach into the breast in the middle line, using the superior pedicle flap narrated by Arie, and the implant is positioned below the muscle producing a greater breast projection, makes the Mastopexy be more durable.

**Methods:** Was performed 77 Mastopexy between 2010 and 2018, with Medial approach for the Mastopexy with breast implants (MAMBI). Twenty eight round retropectoral implants were applied using the superior pedicle flap.

**Results:** Medial approach for the Mastopexy with breast implants in unique time in both breasts, to avoid areolar flap currently not recommended. All of them had ptosis in different degrees. In all cases we obtained good projection and adequate volume increase.

**Conclusions:** The Mastopexy techniques do not have to include the submammary fold, the most compromising is the submammary scar, avoid it with the Medial approach for the Mastopexy with breast implants. And with the technique of superior flap the resultant must be with an increased upper pole, so that during the evolution process it decreases proportionally to the lower pole.

**Keywords:** Mastopexy, Superior flap, Breast implants.

## INTRODUCTION

Mastopexy techniques from my point of view should only be those that do not have to include the submammary fold, since the most compromising is the submammary scar.

Some authors, such as Lassus (1, 2), Lejour (3), Hall-Findley (4) and Arié (5), described Mastopexy techniques, trying to eliminate this annoying scar that really is of reduction and not pexy like in the ptotic breast.

The first description of Mastopexy with implants was related by Gonzalez-Ulloa(6).

In 1976, Regnault (7,8) presented a classification system for breast ptosis, which has seen various modifications over time.

Arie, published a technique for the correction of ptosis and breast hypertrophy. The modification to

the technique of Arié 1957 presented by Pitanguy in 1959, facilitated the mammary reduction surgery in breast of diverse sizes.

The goal of the medial Medial Approach for the Mastopexy with Breast Implants (MAMBI) is to elevate the breast tissue, orient the nipple / areola complex (NAC) and improve breast symmetry to maximize the aesthetics of the breasts.(9)

## PATIENT SELECTION

So that the vertical approach for the Mastopexy with implants is carried out, depending on the individual characteristics of each patient, the following characteristics must be included:

1. Up to Ptosis grade 2, of the Regnault classification.
2. That the distance of the supraexternal hollow to the NAC does not exceed 23 cm.

## Medial Approach for the Mastopexy with Breast Implants. (MAMBI)

### TECHNIQUE

Mastopexy with implants in one surgical time and associating an inferior non-areolar flap currently not recommended is indicated in hypomasty with ptosis to get a good mammary projection and long-term results.

The technique of choice was chosen in relation to four techniques:

- Removal of the areola nipple complex,
  - Periareolar pexy,
  - The Arie's technique.

- And / or variants of techniques (these usually in secondary surgeries).

A vertical incision allows access to the breast and can be easily used so that in this way, develop the pocket and locate the implant. (Figs.1 and 2)

The technique is equally useful for breasts of any size, and even for breasts ptosics, flaccid, not hypertrophic, with hardly any glandular or fatty content, being able to increase its size, with the addition of breast implants. A great advantage of this procedure is that with a single technique the most varied cases can be solved.

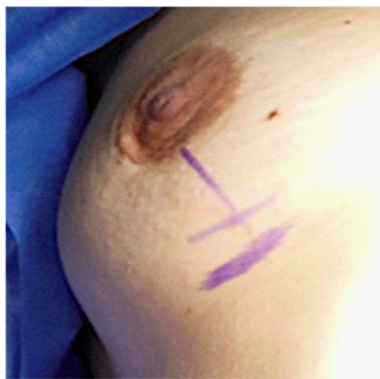


Fig 1

The implant is placed through a medial incision, with transglandular dissection, taking off, dissecting and surrounding the gland until it reaches the pectoral fascia and the edges of the pectoralis major muscle. It is convenient in the cases that we have lesser glandular component to place the implants under the muscle, since this will allow us to be coated.

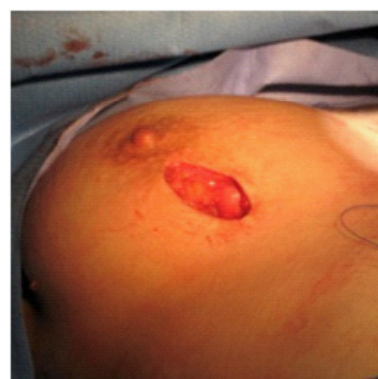

Fig 2

After accessing below the pectoralis major muscle, (retropectoral space), a tunnel is made in relation to the base of the selected implant. (10,11)

Once the implant is placed, sutures are applied in subcutaneous cellular tissue and transient in the skin. To start the marking and start the Mastopexy, it is necessary to know the amount of excess skin. (Fig.3)

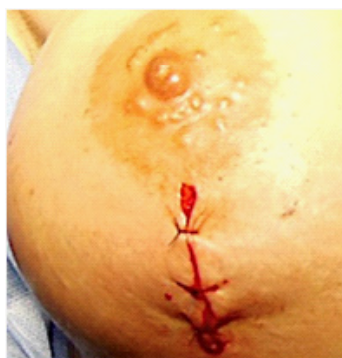
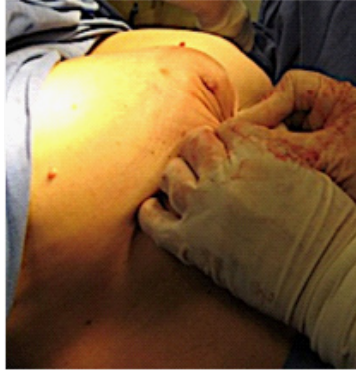
Fig 3

The skin excision and de-epithelialization reference points are made according to the criteria applied in the restoration of mammary hypertrophy, that is, the technique of the

remaining breast. With a double pinching on the skin, both ends are approached assessing the non-tension caused, to program the design of the skin to be resected. (Fig.4)



**Fig 4**

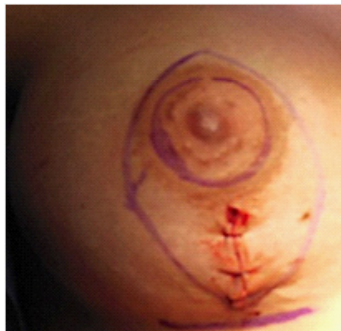
The resection or cutaneous de-epithelialization of the segment corresponds to a triangle with a rather narrow upper base ending in a point 1cm above the future fold, in the form of an acute angle and avoiding the formation of a bag or a fold, as it is usual in vertical techniques. (Fig.1)

Beginning undermining in the submammary fold, the central portion of the gland is dissected, constructing a tunnel of 10 to 12 cm wide on the pectoral, to the third intercostal space.

By pushing the excess tissue from the lower pole, the position and shape of the bulging end of the breast

is brought into better harmony with the position of the NAC. In most cases, the outer boundary is almost tangential to the outer areolar border. The lower areolar point is calculated from the future inframammary fold. To minimize the tension at the height of the infraareolar point, an eyelet-shaped detachment is drawn.

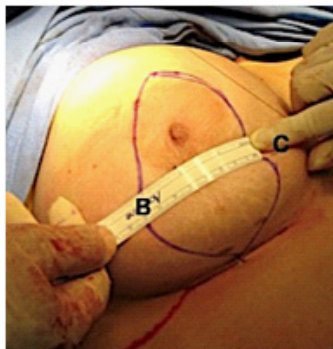A marking of the oblique incision is made to place the implants in the lower pole of the breast, in order to preserve the flap of the internal pedicle that will be made later. (Fig.5)



**Fig 5. Oblique mark**

The distance should not exceed 7 cm in width between the two points B and C. If the distance is

greater, the surgical approach would modify the incision. (Fig.6)



**Fig 6. Seven cm in width between the two points B and C.**

## Medial Approach for the Mastopexy with Breast Implants. (MAMBI)

When concluding the transport of the traces, the CAP is marked bilaterally with an established pattern of 4 cm in diameter.

The surgery begins with the Schwarzmann maneuver (periareolar de-epithelialization preserving the neurovascular supply of NAC).

Followed by an infra-areolar wedge-shaped resection and the transposition of the NAC.

After dissecting the gland and approaching the pectoralis muscle, a retropectoral plane is detached that will serve to accommodate the implant.

Once the skin has been resected and after desepidermizing the areola-nipple complex, the edges are released to facilitate the approach without causing deformation, it is important to limit the cutaneous sacrifice as much as possible in order to avoid excessive tension in the closure of the segment.

This has two planes of detachment: one retropectoral where the implant is lodged and another retroglandular that allows the remodeling

and subsequent fixation of the mammary gland. The complete closure is done with suture by planes without including the area of location of the NAC to be extracted, it is closed with simple points.

The distance from the NAC to the inframammary fold of the NAC to the inframammary fold is 5 cm, the NAC is marked bilaterally with an established pattern of 4 cm in diameter.

The transposition area of the NAC is incised and de-epithelialized.

Exposed the NAC, it is sutured with absorbable material with four cardinal points and the closure is made with 3-0 Nylon with subdermal suture.

In the distance from the NAC to the inframammary fold, sutures are applied in the form of a subdermal mattress.

The resultant must be with an increased upper pole, so that during the evolution process it decreases proportionally to the lower pole. (12)

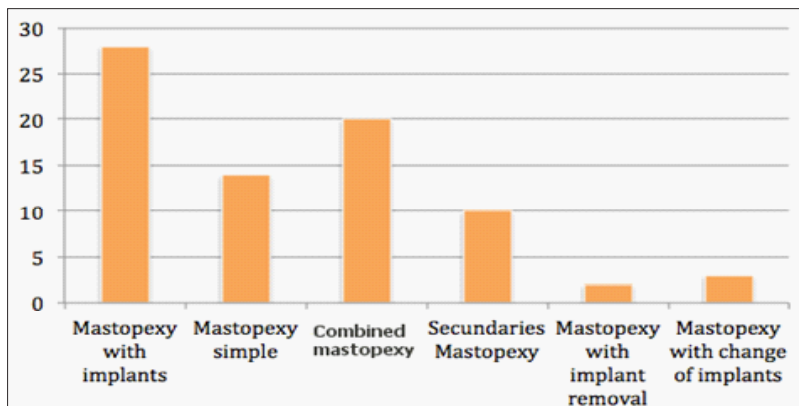


Diagram 1. Between 2010 and 2018 there were 77 Mastopexy surgeries.

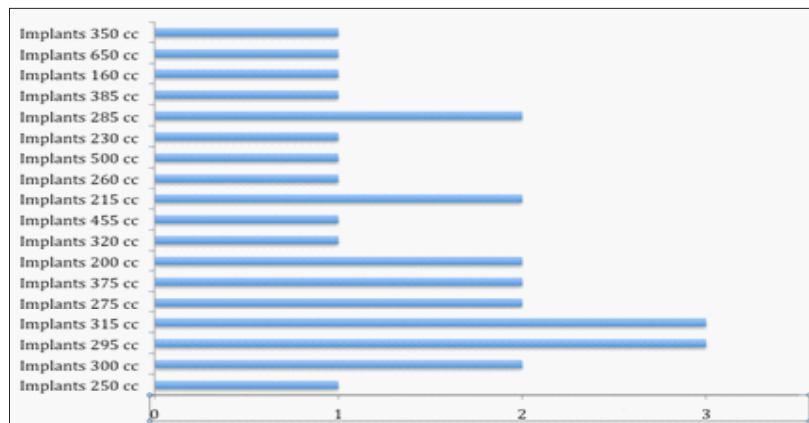
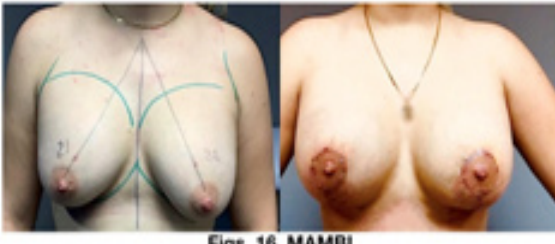
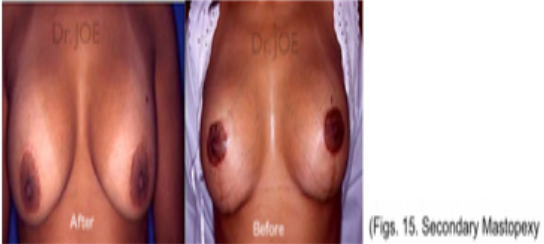
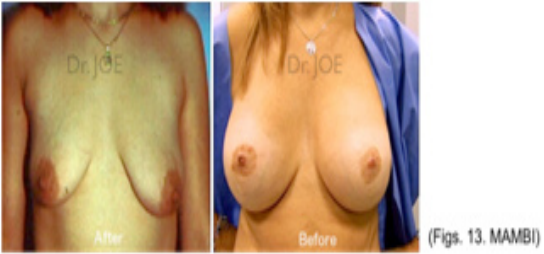
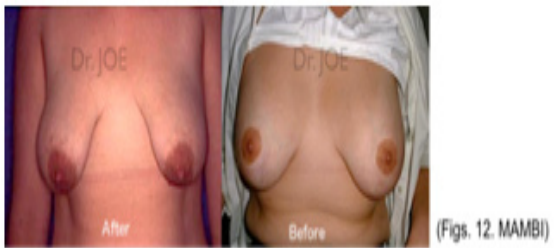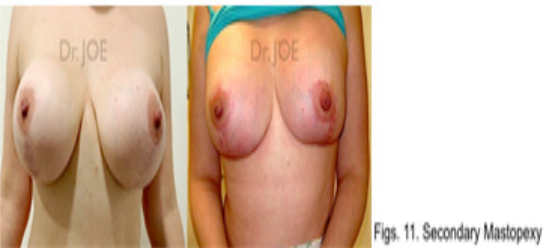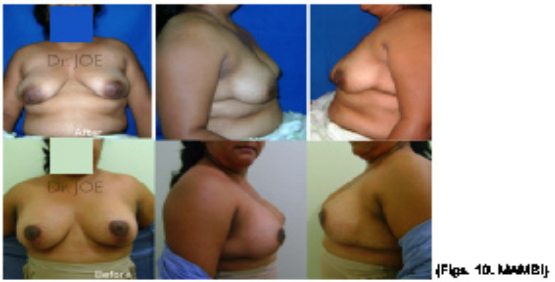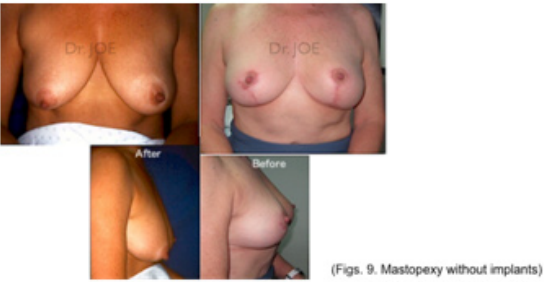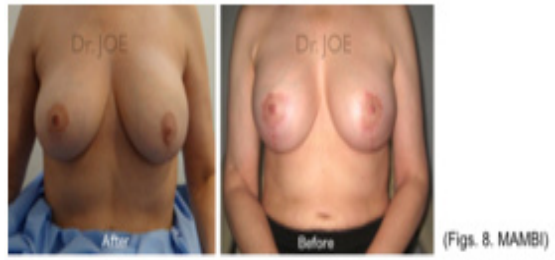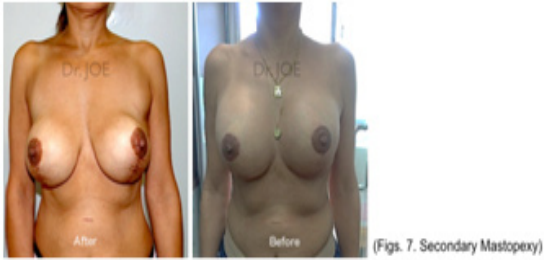Diagram 2. Twenty-eight roundretro pectoral implants were applied, being the smallest of 160 cc and the largest in 650 cc

**Medial Approach for the Mastopexy with Breast Implants. (MAMBI)**



*Clinical Cases (Figs. 7; 8; 9; 10; 11; 12; 13; 14; 15; 16 and 17)*

## Medial Approach for the Mastopexy with Breast Implants. (MAMBI)

### REFERENCES

- [1] Lassus, C.: "A 30-year experience with vertical mammoplasty" *Plast and Reconstr Surg.* 1996; 97(2): 373.
- [2] Lassus, C.: "Update on vertical mammoplasty". *Plast and Reconstr Surg.*1999; 104 (7):2289.
- [3] Lejour M.: "Evaluation of fat in Breast Tissue Removed by vertical mammoplasty". *Plast and Reconstr Surg.*1997; 8(2):386.
- [4] Hall-Findlay EJ. Pedicles in vertical breast reduction and mastopexy. *Clin Plast Surg.* 2002; 29: 379–391.
- [5] Arie G. Una nueva técnica de mastoplastia. *Rev Iberolatinoamericana Cir Plast* 1957; 3:23
- [6] Gonzalez-Ulloa M (1960) Correction of hypertrophy of the breast by exogenous material. *PlastReconstr Surg Transplant Bull* 25:15–26
- [7] Regnault P. Breast ptosis. Definition and treatment. *Clin Plast Surg* 1976; 3:193-203.
- [8] Regnault P (1966) The hypoplastic and ptotic breast: a combined operation with prosthetic augmentation. *PlastReconstrSurg* 37(1):31–37.
- [9] GarciaVelasco M. et.al. Surgical correction of the "small" postpartum ptotic breast. *Aesth. Surg. J.* 24(3) 199-205. 2004 May-Jun.
- [10] Ribeiro L. PedículosEmMamoplastia. Atlas e Texto. Rio de Janeiro, Brazil: Guanabara Koogan; 2005.
- [11] Saldanha O, et al. Mamoplastiareductora com implante de silicone. *Rev Bras Cir Plás.* 2010; 25: 317–324.
- [12] Swanson E. Ideal breast shape: women prefer convexity and upper pole fullness. *PlastReconstr Surg.* 2015; 135: 641e–643e.

**Citation:** Olivares E. Jorge, Martinez B. Luz Ariana. *Medial Approach for the Mastopexy with Breast Implants. (MAMBI).* *Open Journal of Surgery.* 2019; 2(2): 06-11.

**Copyright:** © 2019 Olivares E. Jorge, Martinez B. Luz Ariana. *This is an open access article distributed under the Creative Commons Attribution License, which permits unrestricted use, distribution, and reproduction in any medium, provided the original work is properly cited.*