

Omental Torsion as a Cause of Acute Abdomen

Abdulaziz A Sadeq*, Nasser A Abdelall, Mohammad Al Ghadhban

Department of General Surgery Al-Adan Hospital, Al-Ahmadi, Kuwait.

aziz.sadeq15@icloud.com

**Corresponding Author: Abdulaziz A Sadeq, Department of General Surgery, Al-Adan Hospital, Kuwait.*

Abstract

Omental torsion is a rare cause of acute abdomen, and it can be classified as primary or secondary. Generally, the preoperative diagnosis is challenging because of its nonspecific signs and symptoms, and therefore omental torsion is usually diagnosed intraoperatively. We present a case of a 32-year-old male who presented with sudden onset right iliac fossa pain, which was increasing in severity. He had no previous history of any abdominal surgeries or trauma. The patient was taken for diagnostic laparoscopy where the gangrenous omentum was extracted. The post-operative course was uneventful.

Keywords: omental torsion, acute abdomen, laparoscopy, right iliac fossa

INTRODUCTION

Omental torsion is defined as a twist of the omentum along its long axis with consequent impeding of its vascularity that may mimic acute abdomen [1]. It is classified as either primary or secondary. Primary torsion of the greater omentum, was first reported by Eitel in 1899, and since then, there have been over 250 reported cases in the literature [2,3]. It mainly affects patients in the third to fifth decade of life, involving men twice as frequently as women [4]. Usually no identifiable cause is found for cases of primary omental torsion. However, it may be related to local omental anatomical variations that allow a moveable segment to twist around the proximal fixed point. On the other hand, secondary omental torsion, which is more common than primary omental torsion, occurs due to hernial sacs, surgical scars or wounds, tumours and cysts. The most common cause of omental torsion is secondary to inguinal hernias [5]. Usually, patients present with acute abdominal pain localized in the right iliac fossa, mimicking acute appendicitis or ovarian torsion in female patients. This vague presentation makes preoperative diagnosis difficult leading to most cases being diagnosed intraoperatively; however, the use of computerized tomography (CT) scan and, in some cases, ultrasound scan has made preoperative diagnosis possible. Most cases are managed surgically through omentectomy [6]. In this article we present a case of acute abdomen caused by omental torsion.

CASE

A 32-year-old previously healthy male presented to the Emergency department with a 2-day history of sudden onset right iliac fossa pain, which was increasing in severity. The pain was colicky in nature, non-radiating, and associated with nausea, vomiting, and loss of appetite. It was not associated with fever, change in bowel habits or urinary symptoms. The patient had no history of previous abdominal surgeries or trauma. On examination, the patient's vital signs were within normal limits, and abdominal examination revealed rebound tenderness and guarding in the right iliac fossa, with normal bowel sounds. Laboratory findings showed leukocytosis (WBC: $15.4 \times 10^9/L$) predominantly neutrophilia, with normal renal and liver function tests, and urine routine and microscopy. No abnormalities were detected on abdominal and chest x-rays. The patient was misdiagnosed clinically and admitted as a case of acute appendicitis, and no further imaging studies were performed. Therefore, he was transferred to the emergency operating theatre for laparoscopic appendectomy. Intraoperatively torsion of the omentum was found at the base of the transverse colon with gangrenous omentum herniating into the right deep inguinal ring. The appendix was found to be normal. The gangrenous omentum was dissected until the twist, and endloop was applied for ligation below the twist, followed by extraction through the bag and securing of hemostasis. The postoperative course was uneventful, and the patient was discharged from the hospital on postoperative day 1.

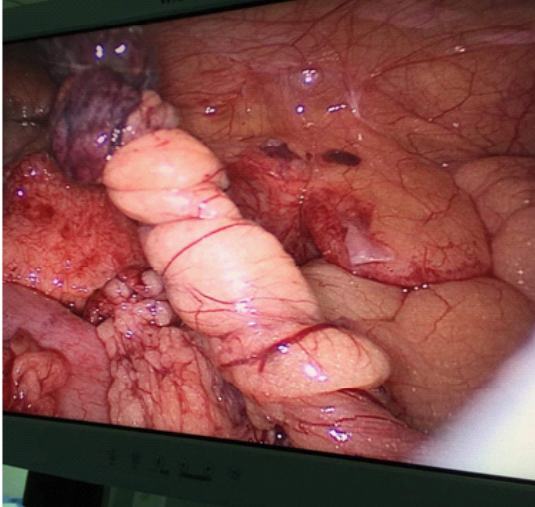


Fig 1. Omental torsion at base of transverse colon

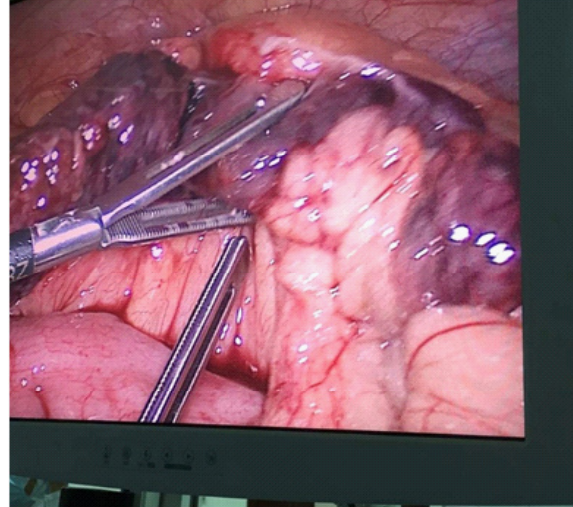


Fig 2. Gangrenous omentum herniating into the right deep inguinal ring

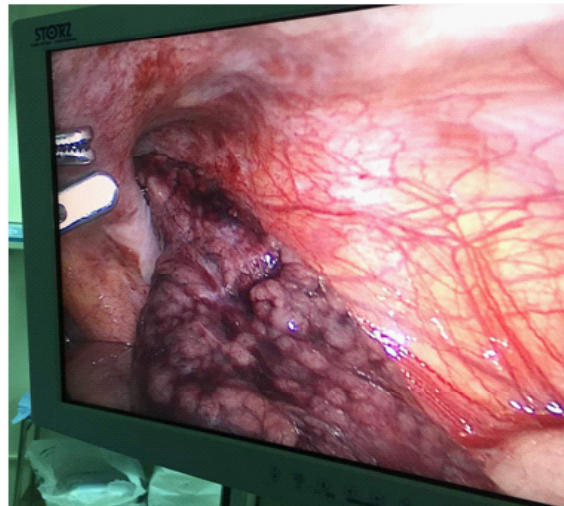


Fig 3. Gangrenous omentum herniating into the right deep inguinal ring

DISCUSSION

The dorsal mesentery is the origin of the greater omentum. It is a sheet made up of four layers of peritoneum, which is attached from the greater curvature, covering the neighboring organs [7]. Due to its very low incidence and vague presenting signs and symptoms, omental torsion is very difficult to diagnose. When compared with appendicitis, torsion has an incidence of 0.0016% to 0.37%, which is a ratio of less than 4 cases per 1000 cases of appendicitis [8]. There is no clear cause of primary omental torsion; however, sometimes a large and mobile omentum that has rotated one or more times around a fixed spot, mainly the right epiploic artery, is appreciated during surgery [9].

Risk factors for omental torsion include anatomical variations in the omentum and actions that displace the omentum such as trauma, exercise or hyperperistalsis. Obesity has also been implemented as a risk factor [10,11]. In a study conducted by A. C. Breda Vriesman et al. almost 70% of patients with omental torsion were obese [12]. It is theorized that excess fat, which is unevenly distributed in the omentum, leads to omental torsion. Secondary torsion occurs most often because of hernia, tumor, or adhesion, with the dependent omentum becoming fixed in the torse position and unable to untwist. Both processes may lead to infarction of the affected omentum [13]. Our patient seems to have had none of these predisposing or precipitating conditions mentioned.

Omental Torsion as a Cause of Acute Abdomen

Usually patients present with pain, which is commonly localized in the right lower quadrant or right paraumbilical region of the abdomen. The pain usually occurs suddenly with increasing severity. It is persistent, does not radiate, and is commonly associated with nausea, vomiting, as well as anorexia and loss of appetite [14]. If the omentum involved is a large part, a mass might be palpable. Other presenting features include fever and leukocytosis. These signs and symptoms imitate acute appendicitis as reported in the Alvarado Score [15] making preoperative diagnosis difficult and hence leading to most cases being diagnosed intraoperatively, as in our case.

According to clinical presentation, omental torsion falls in the category of acute abdomen and so ultrasound and CT scans are usually the studies of choice to assist diagnosis. Ultrasound findings in the case of omental torsion demonstrate hyperechoic, noncompressible ovoid intra-abdominal mass adherent to the abdominal wall, which is located in the umbilical region or anterolaterally to the right half of the colon [16,17]. In addition, specific CT findings include diffuse streaking in a whirling pattern of fibrous and fatty folds [18]. Although these imaging studies are usually very helpful in establishing the diagnosis, only 0.6% to 4.8% of cases of omental torsion are diagnosed preoperatively [13]. In our case the patient refused imaging studies due to inability to pay, and due to his typical presentation of acute appendicitis, he was transferred to the operating theatre where diagnostic laparoscopy was performed.

The treatment of omental torsion can be surgical or conservative. Conservative management involves oral analgesics, anti-inflammatory drugs, and prophylactic antibiotics; however, conservative management has many complications such as abscesses and adhesions due to the persistence of the necrotic omental tissue [19]. In review of the literature, only 7 cases have been described where conservative management was successful in which the omental torsion became atrophied or fibrosed. On the other hand, surgical treatment involving omentectomy via laparoscopic or laparotomic approach is the treatment of choice [20].

CONCLUSION

In conclusion omental torsion can be very difficult to diagnose due to its very low incidence and vague presenting signs and symptoms. Ideally, the patient should be diagnosed preoperatively. Although imaging

tests play a huge role in establishing the diagnosis, exploratory surgery is often necessary when clinical features are unclear. Due to the many advantages of laparoscopic surgery over the conventional laparotomy, laparoscopic surgery should be the first option for the treatment of internal hernias when there are no contraindications for laparoscopy.

REFERENCES

- [1] Yager A, Carmeci C. Torsion of the greater omentum: CT findings. *AJR. American journal of roentgenology*. 1999 Oct; 173(4): 1139.
- [2] Shinde J, Pandit S, Fernandes A, Joshi V, Naik R. Case report of primary omental torsion. *Medical Journal of Dr. DY Patil University*. 2015 Jul 1; 8(4):534.
- [3] Occhionorelli S, Zese M, Cappellari L, Stano R, Vasquez G. Acute abdomen due to primary omental torsion and infarction. *Case reports in surgery*. 2014;2014.
- [4] Tsironis A, Zikos N, Bali C, Pappas-Gogos G, Koulas S, Katsamakis N. Primary torsion of the greater omentum: report of two cases and review of the literature. *The internet journal of surgery*. 2008;17(2):16.
- [5] Kim J, Kim Y, Cho OK, Rhim H, Koh BH, Kim YS, Han DS, Baek HK. Omental torsion: CT features. *Abdominal imaging*. 2004 Jul 1;29(4):502-4.
- [6] Chinaka C, Mansoor S, Salaheidin M. Torsion of the Omentum: A Rare Cause of Acute Abdomen in a 14-Year-Old Boy. *Case reports in surgery*. 2018; 2018.
- [7] Tsironis A, Zikos N, Bali C, Pappas-Gogos G, Koulas S, Katsamakis N. Acute abdomen due to primary omental torsion: case report. *The Journal of emergency medicine*. 2013 Jan 1;44(1):e45-8.
- [8] Pinedo-Onofre JA, Guevara-Torres L. Omental torsion. *An acute abdomen etiology. Gaceta medica de Mexico*. 2007; 143(1): 17-20.
- [9] Scabini S, Rimini E, Massobrio A, Romairone E, Linari C, Scordamaglia R, De Marini L, Ferrando V. Primary omental torsion: a case report. *World journal of gastrointestinal surgery*. 2011 Oct 27; 3(10):153.
- [10] Itenberg E, Mariadason J, Khersonsky J, Wallack M. Modern management of omental torsion and

Omental Torsion as a Cause of Acute Abdomen

- omental infarction: a surgeon's perspective. *Journal of surgical education*. 2010 Jan 1; 67(1): 44-7.
- [11] Atar E, Herskovitz P, Powsner E, Katz M. Primary greater omental torsion: CT diagnosis in an elderly woman. *The Israel Medical Association journal: IMAJ*. 2004 Jan; 6(1): 57-8.
- [12] Vriesman AB, Lohle PN, Coerkamp EG, Puylaert JB. Infarction of omentum and epiploic appendage: diagnosis, epidemiology and natural history. *European radiology*. 1999 Nov 1;9(9):1886-92.
- [13] Theriot JA, Sayat J, Franco S, Buchino JJ. Childhood obesity: a risk factor for omental torsion. *Pediatrics*. 2003 Dec 1; 112(6): e460-2.
- [14] Albuz O, Ersoz N, Kilbas Z, Ozerhan IH, Harlak A, Altinel O, Yigit T. Primary torsion of omentum: a rare cause of acute abdomen. *The American journal of emergency medicine*. 2010 Jan 1; 28(1): 115-e5.
- [15] Alvarado A. A practical score for the early diagnosis of acute appendicitis. *Annals of emergency medicine*. 1986 May 1;15(5):557-64.
- [16] Benaghmouch F, Hrorra A, Benamer A, Sabbah F, Ahallat M, Raiss M. Acute abdomen for omental torsion. *European Journal of Radiology Extra*. 2011 Aug 1; 79(2): e55-7.
- [17] Puylaert JB. Right-sided segmental infarction of the omentum: clinical, US, and CT findings. *Radiology*. 1992 Oct;185(1):169-72.
- [18] El KA, Driss B, Abdellatif D, Mehci A, Souad C, Mohamed B. Omental torsion and infarction: CT appearance. *Internal Medicine*. 2008;47(1):73-4.
- [19] Perelló JM, Albasini JA, Aledo VS, Jiménez JA, Pastor BF, Arenas MC, Baena EG. Torsión de epiplón: las técnicas de imagen pueden evitar intervenciones innecesarias. *Gastroenterología y hepatología*. 2002 Jan 1; 25(8): 493-6.
- [20] Sánchez J, Rosado R, Ramírez D, Medina P, Mezquita S, Gallardo A. Torsion of the greater omentum: treatment by laparoscopy. *Surgical Laparoscopy Endoscopy & Percutaneous Techniques*. 2002 Dec 1; 12(6): 443-5.

Citation: Abdulaziz A Sadeq, Nasser A Abdelall, Mohammad Al Ghadhban. *Omental Torsion as a Cause of Acute Abdomen*. *Open Journal of Surgery*. 2019; 2(1): 01-04.

Copyright: © 2019 Abdulaziz A Sadeq, Nasser A Abdelall, Mohammad Al Ghadhban. This is an open access article distributed under the Creative Commons Attribution License, which permits unrestricted use, distribution, and reproduction in any medium, provided the original work is properly cited.