

# Adult Asymmetrical Tonsils: Case Series and Review of Current Literature

Ankit Patel\*, Bhavesh Patel, Hesham Kaddour

\*Barking & Havering NHS Trust, Rom Valley Way, Romford, Essex, RM7 0AG.

*\*Corresponding Author: Ankit Patel, Barking & Havering NHS Trust, Rom Valley Way, Romford, Essex, RM7 0AG.*

## Abstract

*In adults, tonsillar asymmetry may represent oropharyngeal squamous cell carcinoma (SCC), lymphoma or other primary tumours of the tonsil. For this reason, many patients with asymmetrical tonsils undergo tonsillectomy. True unilateral tonsillar enlargement can be caused by several causes other than malignancy, including tonsillar hyperplasia resulting from repeated or chronic infection. In addition, a prolapsed tonsil or asymmetry of the tonsillar pillars can demonstrate a false asymmetry.*

*70 patients underwent tonsillectomy for asymptomatic asymmetrical tonsils at our institution with no other features of malignancy. No cases of malignancy were identified on histology.*

*We have reviewed the existing literature and suggested a novel guideline on the management of adult tonsillar asymmetry.*

**Keywords:** *Cancer, Head and neck surgery, Magnetic resonance imaging, Tonsil, Tonsillectomy*

## INTRODUCTION

The presence of an asymmetrical tonsil is a relatively common referral to the ENT clinic. As secondary lymphoid tissues, the tonsils can be the site of primary or secondary neoplastic disease. In children asymmetrical tonsils may represent lymphoma<sup>1</sup>. In adults, they may be the presenting feature for oropharyngeal squamous cell carcinoma (SCC) or lymphoma. 85-90% of oropharyngeal cancer in adults is SCC<sup>2</sup>. Other primary tumours of the tonsil have been described in case reports<sup>1</sup>. For this reason, some authors have advocated that all asymmetrical tonsils should undergo tonsillectomy to exclude malignancy<sup>3</sup>. True unilateral tonsillar enlargement can be caused by several causes other than malignancy, including repeated or chronic infection<sup>4</sup>.

Tonsillectomy is a common ENT procedure. Its principal indications are recurrent tonsillitis and sleep-disordered breathing, however a small number are carried out to exclude malignancy in an asymmetrical tonsil. The procedure in adults results in significant morbidity for around two weeks - mostly due to post-operative pain. There is an associated risk of secondary post-operative bleeding in approximately

5% of cases<sup>5</sup>. A Scandinavian study has estimated the rate of mortality following tonsillectomy haemorrhage as 1 in 41,000<sup>6</sup>.

Several studies have investigated the necessity to perform tonsillectomy in asymmetrical tonsils given the associated morbidity. We aim to identify the incidence of malignancy in adult asymptomatic asymmetrical tonsils. The current literature on asymmetrical tonsils has been reviewed and a guideline on management has been suggested.

## METHODS

Adult tonsils sent for histology at Barking, Havering and Redbridge University Hospitals NHS Trust between 2011 and 2018 were retrospectively identified. The sample was identified through pathology records. The case notes were reviewed to establish the clinical background to each case.

Patients who underwent tonsillectomy for recurrent tonsillitis, sleep-disordered breathing or suspected tonsil carcinoma were excluded. Cases with lymphadenopathy, tonsil mucosal disease, a positive PET scan and unknown primary were identified as "suspected tonsil carcinomas" and therefore excluded.

## Adult Asymmetrical Tonsils: Case Series and Review of Current Literature

### RESULTS

243 tonsillectomies were sent for histology in the study period (figure 1). Following exclusion, 70 cases of asymptomatic asymmetrical tonsils were identified. The mean age was 27.7 years. The mean volume of the

larger tonsil ( $7690.71\text{mm}^3$ ) was statistically greater (paired t-test,  $p < 0.01$ ) than that of the smaller tonsil ( $5840.15\text{mm}^3$ ).

0/70 patients were found to have malignancy on histology.

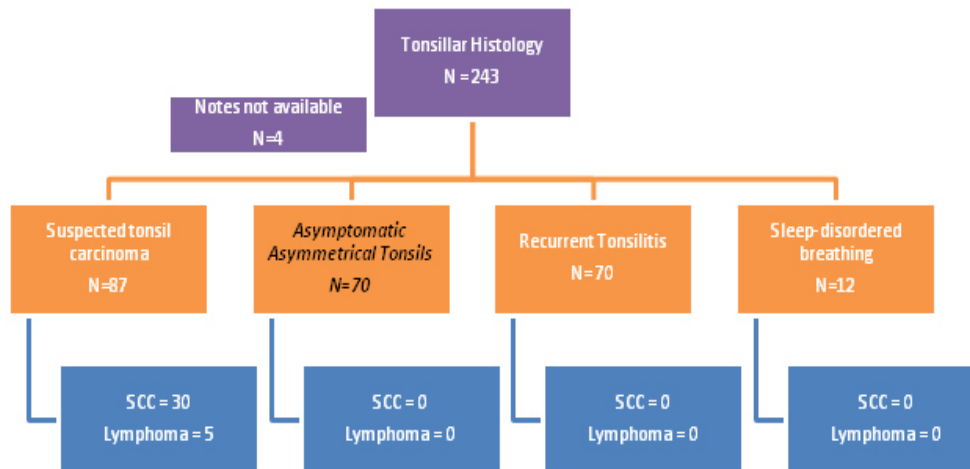


Fig1. Results flowchart

### DISCUSSION

Adults with an asymmetrical tonsil as the only concerning feature frequently undergo tonsillectomy to exclude an underlying malignancy<sup>7</sup>. The procedure is associated with significant morbidity due to pain, the development of secondary post-operative haemorrhage, damage to oral structures and change in taste sensation<sup>8, 9</sup>. The value of performing tonsillectomy for histology must therefore be carefully balanced with these risks. Current programmes in the UK healthcare system have emphasized the importance of “getting it right first time” and reducing procedures of “low clinical value”<sup>10</sup>. This is based on reducing unnecessary morbidity to patients but also reducing the associated costs.

The pattern of oropharyngeal SCC has been changing in recent years. This is associated with an increase in Human-Papilloma Virus (HPV) type 16<sup>11</sup>. Tonsil SCC now comprises 13% of head and neck cancer in men and 10% in women<sup>12</sup>. Although HPV-associated head and neck malignancies are seen to have a favourable prognosis, the need for early detection in any malignancy is paramount<sup>11</sup>. Hence, the presence of an asymmetrical tonsil is an important referral to the ENT clinic and requires a thorough assessment. True tonsil size must be carefully assessed, as a prolapsed tonsil or asymmetry of the tonsillar pillars

can demonstrate a false asymmetry<sup>4</sup>. It is important to assess for concerning signs and symptoms. Concerning signs to review during examination include: mucosal changes/ulceration, firmness on palpation, rapid increase in tonsil size and the presence of neck lumps. Concerning red flag symptoms include: unexplained weight loss, fevers, neck pain, ear pain, throat pain and odynophagia<sup>13</sup>. In the past medical history the presence of immunodeficiency or previous malignancy should be ascertained. If present, concerning signs and/or symptoms should warrant urgent assessment and would categorise the patient into the suspected tonsil carcinoma category. If they are not present then the patient can be managed in the asymptomatic asymmetrical tonsil category which has been reviewed in this paper.

Lymphoma may also present as tonsillar asymmetry. This is more commonly seen in children, but can occur in adults. A number of reviews have identified a low incidence of lymphoma in paediatric tonsillar asymmetry<sup>14</sup>. The concerning features which may suggest lymphoma are: associated lymphadenopathy, rapid tonsillar growth, fevers, night sweats, weight loss and failure to thrive. As with tonsil SCC, a thorough history and examination is paramount to identify associated red flag features which place the patient into a suspected tonsil lymphoma category – this warrants further investigation.

## Adult Asymmetrical Tonsils: Case Series and Review of Current Literature

Our results are relatively consistent with the international literature regarding the rates of malignancy in asymptomatic asymmetrical adult tonsils. A literature search using PubMed has identified 7 articles which have been summarized in Table 1<sup>4, 7, 13, 15-18</sup>. Following data extrapolation, the incidence of malignancy has been identified at 1.15% from a total sample of 522 patients. The six malignancies were all

lymphoma. Randall et al. identified the rate of occult malignancy in routine tonsil specimens at 0.011% (n=54901)<sup>19</sup>. Thus, the incidence of malignancy is approximately 10-times greater in adult asymptomatic asymmetrical tonsils. This highlights the importance of patient assessment and appropriate clinical surveillance.

**Table 1.** Extrapolated histological data from literature review of adult asymptomatic asymmetrical tonsils

Author	Number of adult cases	Positive Histology	Comments
Puttasiddaiah et al. 2007	33	0	Cannot be clear how many children in sample
Spinou et al. 2005	75	0	No malignancy in whom clinical suspicion was low
Reiter et al. 1999	31	2	2 lymphomas, did not formally exclude cervical lymphadenopathy and specific symptoms
Oluwasanmi et al. 2006	87	2	2 asymptomatic adult lymphomas. Cannot be clear how many children in sample
Gomez et al. 2009	25	0	Extrapolated data to identify cases of adult asymptomatic asymmetrical tonsils
Syms et al. 2000	44	2	2 asymptomatic adult lymphomas
Addison et al. 2015	157	0	
Our data. 2019	70	0	
	<b>522</b>	<b>6 (1.15%)</b>	

Magnetic resonance imaging (MRI) is the current imaging of choice for staging soft tissue oropharyngeal carcinoma<sup>20</sup>. MRI with STIR sequences can confirm the presence of tonsil asymmetry and identify suspicious features within the tonsil tissue<sup>20</sup>. Cases of unknown primary with lymph node metastases suggesting on oropharyngeal primary are investigated with MRI, yet the exact specificity and sensitivity of MRI in detecting a tonsil tumour has not been established<sup>21</sup>. MRI can also screen the neck for coexisting lymphadenopathy. MRI is less useful at identifying mucosal changes – which should be carefully assessed clinically<sup>20</sup>. MRI scanners are widely available and have no associated radiation exposure. The principle disadvantages to MRI are related to claustrophobia, increased scanning time and the identification of incidental findings<sup>22</sup>.

Following data extrapolation we identified the incidence of malignancy in adult asymptomatic asymmetrical tonsils to be 1.15% (n = 6/522). It is important to note that the complete exclusion of suspicious clinical signs and symptoms in these studies cannot be established. Given this small positive histology rate, 516 patients in this sample underwent tonsillectomy and the

associated morbidity for no therapeutic gain. This places a significant morbidity upon the patient. In addition, with the current economic pressures faced by the UK healthcare system it has significant financial implications.

As in other branches of medicine, it is important to risk stratify patients to identify individuals who will benefit from an intervention. This practice reduces unnecessary morbidity, whilst ensuring the intervention is performed in selected patients. As a secondary gain, risk-stratifying reduces the financial burden placed upon healthcare systems.

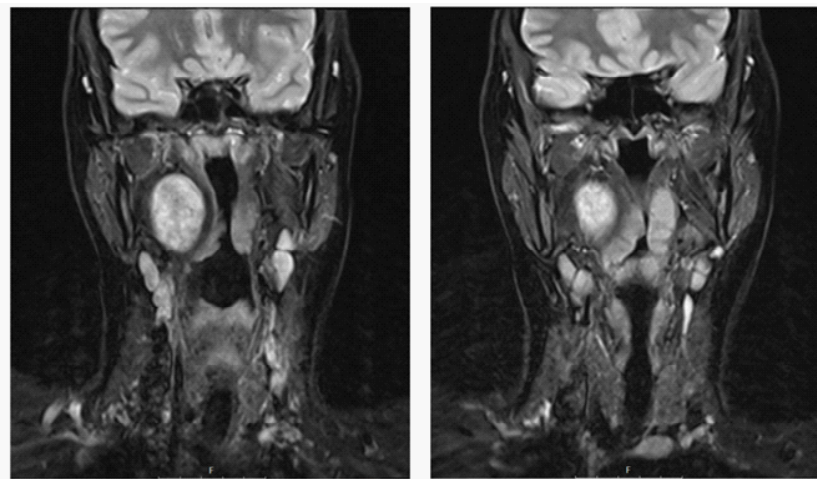
Our suggestion follows that each patient reviewed with an asymmetrical tonsil should be carefully risk stratified prior to considering tonsillectomy for histology. Hwang et al. has already suggested a treatment algorithm to manage tonsil asymmetry<sup>23</sup>. They highlight the use of close observation or CT/CT-PET in conjunction with clinical examination. We advocate the use of MRI as the initial imaging-of-choice in all adults who present with an asymptomatic asymmetrical tonsil. Following the exclusion of an intrinsic tonsillar abnormality, coexisting lymphadenopathy or extrinsic compression

## Adult Asymmetrical Tonsils: Case Series and Review of Current Literature

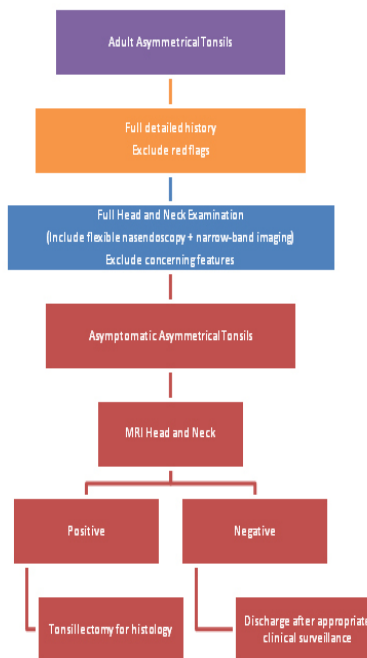
on the MRI imaging (figure 2), the patient can be safely discharged subject to reasonable clinical surveillance (figure 3: flow chart). This excludes any patient who has demonstrated a suspicious clinical sign or symptom in whom tonsillectomy should still be performed. As with any guideline, clinical suspicion and experience should be used in conjunction to ensure optimum patient care. Individuals may argue the need to undertake a MRI in patients with no other concerning features, but in our experience this can cause a delayed diagnosis for underlying pathology, as demonstrated in the case example below. Although of lesser importance, it can also provide additional reassurance to the clinician with regards to potential medicolegal implications.

### Case Example

A 26 year-old female was referred to the ENT clinic with an asymptomatic asymmetrically enlarged right tonsil. On review the right and left tonsil were grade 4 and grade 1 respectively. No concerning features were identified in the history or examination. She underwent a MRI scan (figure 2). This identified the presence of an extrinsic mass medializing the right tonsil. Discharging without imaging could have delayed the diagnosis and undergoing a diagnostic tonsillectomy could have resulted in a significant intra-operative complication. This example highlights the use of the suggested guideline.



**Fig2.** MRI coronal images demonstrating medialisation of right tonsil by parapharyngeal mass



**Fig3.** Proposed guideline of management adult asymmetrical tonsils

## Adult Asymmetrical Tonsils: Case Series and Review of Current Literature

From a financial perspective, over the seven year period the use of such a guideline within our trust would have saved a total of £65,844.10. We have used National Health Service (NHS) healthcare resource group (HRG) codes and the associated tariff<sup>24</sup>. The calculation has incorporated the tariff of 70 day-case tonsillectomies (£1063/tonsillectomy) with an associated 5% readmission secondary to post-

tonsillectomy haemorrhage (£980/readmission), and incorporating 1% arrest-of-bleeding in theatre (£1063/arrest in theatre). The cost of 70 MRI scans (£182/MRI) has been deducted. The direct financial impact has been summarized in figure 4. The indirect financial impact of being off-sick from employment for 10-14 days is difficult to accurately determine, but nevertheless represents a significant burden.

**Fig4.** Financial implications of various management options for 70 patients with tonsillar asymmetry

	Activity	Calculation	HRG Code	Total Sum
<b>A</b>	Total cost of tonsillectomies	70 x £1063	CZ05Y	£74,410
<b>B</b>	Total cost of re-admission following secondary bleed	(0.05 x 70) x £980	WA12Y	£3,430
<b>C</b>	Total cost of post-tonsillectomy bleed arrest in theatre	(0.01 x 70) x £1063	CZ05Y	£744.10
<b>D</b>	Total cost of MRI scans	70 x £182	RA032	£12,740
	<b>Final Calculation = (A + B + C) - D</b>			<b>£65,844.10</b>

### CONCLUSION

The management of an asymmetric tonsil is controversial and varies considerably. We have suggested a guideline to use in the case of an asymptomatic adult asymmetric tonsil. It aims to reduce morbidity to patients and reduce financial implications healthcare systems, whilst risk-stratifying individuals who will benefit from further investigation and intervention. Further assessment and validation is still required to confirm its use in the clinical setting. The importance of clinical judgement and experience is paramount in managing these patients.

### SUMMARY

- Neoplastic disease can present as tonsillar asymmetry
- The yield of neoplastic disease on histopathological examination in asymptomatic tonsillar asymmetry is extremely low
- Patients should be risk stratified on the basis of clinical history and examination as to whether neoplastic disease is likely
- Asymptomatic tonsillar asymmetry in patients with a low clinical suspicion should be investigated with MRI as opposed to tonsillectomy for histology
- Use of such a treatment algorithm can significantly reduce patient morbidity for surgery, which could provide significant cost savings for care providers

### REFERENCES

- [1] Rokkjaer MS, Klug TE. Malignancy in routine tonsillectomy specimens: a systematic literature review. *European archives of oto-rhino-laryngology: official journal of the European Federation of Oto-Rhino-Laryngological Societies (EUFOS): affiliated with the German Society for Oto-Rhino-Laryngology - Head and Neck Surgery* 2014; **271**(11):2851-61
- [2] Cinar F. Significance of asymptomatic tonsil asymmetry. *Otolaryngology--head and neck surgery : official journal of American Academy of Otolaryngology-Head and Neck Surgery* 2004; **131**(1):101-3
- [3] Cortez EA, Mattox DE, Holt GR, Gates GA. Unilateral tonsillar enlargement. *Otolaryngology and head and neck surgery* 1979; **87**(6):707-16
- [4] Spinou C, Kubba H, Konstantinidis I, Johnston A. Role of tonsillectomy in histology for adults with unilateral tonsillar enlargement. *The British journal of oral & maxillofacial surgery* 2005; **43**(2):144-7
- [5] Audit NP. Impact of NICE guidance on rates of haemorrhage after tonsillectomy: an evaluation of guidance issued during an ongoing national tonsillectomy audit. *Quality & safety in health care* 2008; **17**(4):264-8

- [6] Ostvoll E, Sunnergren O, Ericsson E, Hemlin C, Hultcrantz E, Odhagen E, et al. Mortality after tonsil surgery, a population study, covering eight years and 82,527 operations in Sweden. *European archives of oto-rhino-laryngology: official journal of the European Federation of Oto-Rhino-Laryngological Societies (EUFOS): affiliated with the German Society for Oto-Rhino-Laryngology - Head and Neck Surgery* 2015;**272**(3):737-43
- [7] Tobias Gomez S, Palomar Asenjo V, Borrás Perera M, Perez Hernandez I, Ruiz Giner A, Palomar Garcia V. [Clinical significance of unilateral tonsillar enlargement]. *Acta otorrinolaringologica española* 2009;**60**(3):194-8
- [8] Hoddeson EK, Gourin CG. Adult tonsillectomy: current indications and outcomes. *Otolaryngology--head and neck surgery : official journal of American Academy of Otolaryngology-Head and Neck Surgery* 2009;**140**(1):19-22
- [9] Ohtsuka K, Tomita H, Murakami G. Anatomy of the tonsillar bed: topographical relationship between the palatine tonsil and the lingual branch of the glossopharyngeal nerve. *Acta otolaryngologica Supplementum* 2002(546):99-109
- [10] Thong G, Davies K, Murphy E, Keogh I. Significant improvements in quality of life following paediatric tonsillectomy: a prospective cohort study. *Irish journal of medical science* 2017;**186**(2): 419-25
- [11] Mehanna H, Evans M, Beasley M, Chatterjee S, Dilkes M, Homer J, et al. Oropharyngeal cancer: United Kingdom National Multidisciplinary Guidelines. *The Journal of laryngology and otology* 2016;**130**(S2):S90-s6
- [12] Head and neck cancers incidence statistics. In: <https://www.cancerresearchuk.org/health-professional/cancer-statistics/statistics-by-cancer-type/head-and-neck-cancers/incidence#heading-Four> [2019, April 17]
- [13] Puttasiddaiah P, Kumar M, Gopalan P, Browning ST. Tonsillectomy and biopsy for asymptomatic asymmetric tonsillar enlargement: are we right? *The Journal of otolaryngology* 2007;**36**(3):161-3
- [14] Jones GH, Burnside G, McPartland J, Markey A, Fallon M, De S. Is tonsillectomy mandatory for asymmetric tonsils in children? A review of our diagnostic tonsillectomy practice and the literature. *International journal of pediatric otorhinolaryngology* 2018;**110**:57-60
- [15] Reiter ER, Randolph GW, Pilch BZ. Microscopic detection of occult malignancy in the adult tonsil. *Otolaryngology--head and neck surgery : official journal of American Academy of Otolaryngology-Head and Neck Surgery* 1999;**120**(2):190-4
- [16] Oluwasanmi AF, Wood SJ, Baldwin DL, Sipaul F. Malignancy in asymmetrical but otherwise normal palatine tonsils. *Ear, nose, & throat journal* 2006;**85**(10):661-3
- [17] Syms MJ, Birkmire-Peters DP, Holtel MR. Incidence of carcinoma in incidental tonsil asymmetry. *The Laryngoscope* 2000;**110**(11):1807-10
- [18] Addison AB, Whittaker M, Maddox T, Pelsler A, Watts S. Tonsillectomy for asymmetrical tonsils, are we over-diagnosing and managing: a review of 157 cases: Our Experience. *Clinical otolaryngology: official journal of ENT-UK; official journal of Netherlands Society for Oto-Rhino-Laryngology & Cervico-Facial Surgery* 2015;**40**(3): 278-80
- [19] Randall DA, Martin PJ, Thompson LD. Routine histologic examination is unnecessary for tonsillectomy or adenoidectomy. *The Laryngoscope* 2007; **117**(9):1600-4
- [20] Lewis-Jones H, Colley S, Gibson D. Imaging in head and neck cancer: United Kingdom National Multidisciplinary Guidelines. *The Journal of laryngology and otology* 2016;**130**(S2):S28-s31
- [21] Mackenzie K, Watson M, Jankowska P, Bhide S, Simo R. Investigation and management of the unknown primary with metastatic neck disease: United Kingdom National Multidisciplinary Guidelines. *The Journal of laryngology and otology* 2016;**130**(S2):S170-s5

## Adult Asymmetrical Tonsils: Case Series and Review of Current Literature

---

- [22] Stip E, Miron JP, Nolin M, Letourneau G, Bernazzani O, Chamelian L, et al. Incidentaloma Discoveries in the Course of Neuroimaging Research. *The Canadian journal of neurological sciences / Le journal canadien des sciences neurologiques* 2019; 1-5
- [23] Hwang MS, Kaye KE, Waxman JA, Friedman M. What is the best management of asymptomatic unilateral tonsillar enlargement? *The Laryngoscope* 2015; **125**(11):2438-40
- [24] HRG4+ 2017/18 Reference Costs Grouper. In: <https://digital.nhs.uk/services/national-casemix-office/downloads-groupers-and-tools/costing-hrg4-2017-18-reference-costs-grouper> [2019, April 17]

**Citation:** Ankit Patel, Bhavesh Patel, Hesham Kaddour. *Adult Asymmetrical Tonsils: Case Series and Review of Current Literature. Open Journal of Otolaryngology. 2020; 3(2): 33-39.*

**Copyright:** © 2020 Ankit Patel, Bhavesh Patel, Hesham Kaddour. *This is an open access article distributed under the Creative Commons Attribution License, which permits unrestricted use, distribution, and reproduction in any medium, provided the original work is properly cited.*