

Retained Intrauterine Fetal Bone Fragments as a Cause of Abnormal Uterine Bleeding: An Unusual Case Report

Swati Agrawal^{1*}, Kiran Aggarwal², Manvi Dua³, Ritika Choudhary⁴, Alisha Sethi⁴

^{1*}Associate Professor, Department of Obstetrics & Gynaecology, Lady Hardinge Medical College & Smt. Sucheta Kriplani Hospital, New Delhi.

²Director Professor, Department of Obstetrics & Gynaecology, Lady Hardinge Medical College & Smt. Sucheta Kriplani Hospital, New Delhi.

³Senior Resident, Department of Obstetrics & Gynaecology, Lady Hardinge Medical College & Smt. Sucheta Kriplani Hospital, New Delhi.

⁴Post-graduate student, Department of Obstetrics & Gynaecology, Lady Hardinge Medical College & Smt. Sucheta Kriplani Hospital, New Delhi.
drswatimail@gmail.com

***Corresponding Author:** Dr. Swati Agrawal Associate Professor Department of Obstetrics & Gynaecology, Lady Hardinge Medical College & Smt. Sucheta Kriplani Hospital, New Delhi.

Abstract

Introduction: Retention of fetal bones in the uterine cavity is a rare occurrence and almost always a consequence of second trimester termination of pregnancy

Case: We report an unusual case of a 28 year old P1L1A3 lady who had a surgical termination of a 16 week pregnancy 4 months back and presented with abnormal uterine bleeding. She was anxious to conceive again. Transvaginal ultrasound revealed multiple linear calcific foci in the uterine cavity. Hysteroscopy showed presence of multiple flat fetal bones which were removed under vision. The patient was put on high dose oestrogen in postoperative period and conceived spontaneously 2 months after the procedure.

Conclusion: The differential diagnosis of retained fetal bones should be kept in mind in any woman presenting with abnormal uterine bleeding and difficulty in conception after a second trimester abortion. Also, this case highlights the need to avoid surgical termination of second trimester abortion unless it is done by a skilled person or done under ultrasound guidance.

Keywords: Retained fetal bones, Abnormal uterine bleeding, Hysteroscopy, Fertility

INTRODUCTION

Intrauterine retention of fetal bone fragments is a rare complication of termination of pregnancy especially in the second trimester(1). Rarely, heterotopic intrauterine bone formation may occur as a result of osseous metaplasia brought about by chronic inflammation(2). The patient may present with gynaecological complaints such as irregular bleeding, heavy menstrual bleeding, chronic pelvic pain, vaginal discharge, dysmenorrhea and infertility; or may remain asymptomatic(3).

Hysteroscopy remains the mainstay for the diagnosis and treatment of this condition.

CASE REPORT

A 28 year old P1L1A3 lady presented to the outpatient department of our hospital with chief complaint of abnormal uterine bleeding for last 4 months. Her menstrual cycles had been normal and regular until the termination of a 16 weeks missed abortion by blind dilatation & curettage done 4 months back at a private clinic, following failure of medical methods of abortion. She developed high grade fever in the postoperative period which was managed with injectable antibiotics and anti-inflammatory agents. Her menstrual cycles ever since became heavy with intermenstrual spotting lasting for 15-20 days in a

Retained Intrauterine Fetal Bone Fragments as a Cause of Abnormal Uterine Bleeding: An Unusual Case Report

month. Her obstetric history revealed 1 spontaneous abortion and 1 medical abortion both in the first trimester and a full term caesarean section done 2 years back which was uneventful. She was keen on conception again and was not using any contraception. She did not have any history of a medical or surgical illness.

Her general physical, systemic as well as pelvis examination was unremarkable. Her blood investigations were normal and beta HCG was negative. Transvaginal scan was done which revealed multiple linear highly echogenic foci inside the uterine cavity with an endometrial thickness of 8.7 mm (Figure 1). Hysteroscopy showed multiple pale flattened bone like tissue in varying shapes and sizes inside the uterine cavity with a thin and congested endometrium (Figure 2). A diagnosis of retained fetal bones was made and 18 bone fragments were removed hysteroscopically (Figure 3).

The patient was given single shot of co-amoxiclav preoperatively as per institutional protocol. Postoperatively, the patient was put on high dose estrogens- Tablet progynova 2 mg twice a day for 21 days. The histopathology report confirmed mature osseous tissue in the retrieved tissue consistent with fetal bone.

Postoperative transvaginal ultrasound showed a smooth and regular endometrial lining without any contents (Figure 4). The patient resumed her normal regular menstrual cycles 1 month after the procedure and conceived spontaneously 2 months after the procedure. She is carrying well with her pregnancy in the third trimester at the time of writing this case report.

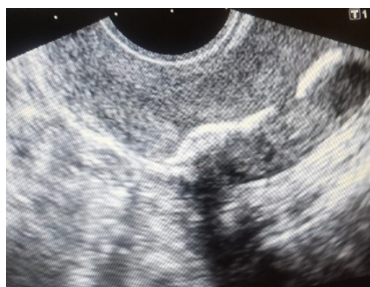


Fig 1. Transvaginal scan showing multiple linear highly echogenic foci inside the uterine cavity

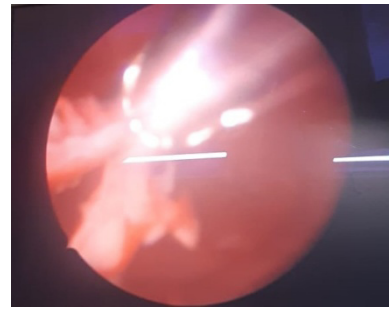


Fig 2. Hysteroscopy showed multiple pale flattened bone like tissue

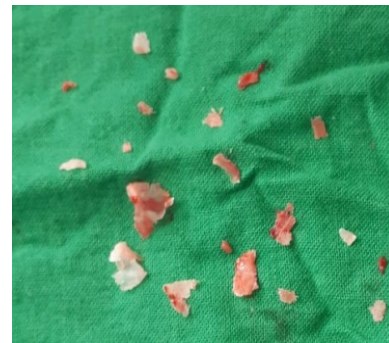

Fig 3. Removed bone fragments

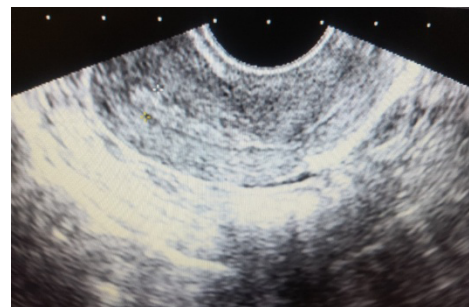


Fig 4. Postoperative transvaginal ultrasound showed a smooth and regular endometrial lining

DISCUSSION

Retained fetal bones is a very rare complication of surgical termination of pregnancy (STOP) and is almost always a consequence of second trimester termination of pregnancy. It usually presents with abnormal uterine bleeding, dysmenorrhea, chronic pelvic pain and secondary infertility. It is therefore important to be aware of this condition and have a high index of suspicion for the same in all patients presenting with the above symptoms with history of STOP. It is said that presence of retained fetal bones act like an intrauterine device preventing implantation and thus leading to secondary infertility. It is also speculated that the presence of bones can also lead to

Retained Intrauterine Fetal Bone Fragments as a Cause of Abnormal Uterine Bleeding: An Unusual Case Report

an increase in endometrial prostaglandins and inhibit implantation (4).

Imaging studies especially a pelvic ultrasound usually help in making a definitive diagnosis but hysteroscopic evaluation is the gold standard for diagnosis and treatment (5). The removal of residual fetal bones under hysteroscopic guidance ensures completeness of treatment with nil or minimal complications. Fetal bones retained for a long period of time may become embedded in the myometrium and also give rise to uterine synechiae. Both the consequences can be easily and safely dealt with hysteroscopy in expert hands.

It is common knowledge that complications from surgical abortions increase in frequency and severity with the increase in the gestational age. The most common complications include hemorrhage, perforation, cervical lacerations and retained tissue. Obtaining adequate cervical dilatation and use of intraoperative ultrasound has been shown to lower the rate of complications in some studies(6). The present study highlights the need to avoid STOP in advanced gestation. If it becomes necessary to perform STOP in second trimester, the authors suggest that the procedure should be carried out by an experienced person, preferably under ultrasonic guidance, to reduce the incidence of perforation and retained products.

REFERENCES

- [1] Xiao S, Tian Q, Xue M. Infertility caused by intrauterine fetal bone retention: a case report. *Journal of Medical Case Reports* 2014;8:177
- [2] Louis LS, Kingman CE, Cochrane GW. Heterotopic intrauterine bone formation. *J Obstet Gynaecol* 2007;27:208-9.
- [3] Lanzarone VF, Pardey JM. Retained intrauterine fetal bone as a rare cause of secondary infertility. *Aust N Z J Obstet Gynaecol* 2009;49:700-1.
- [4] Moon HS, park YH, Kwon HY, Hong SH, Kim SK. Iatrogenic secondary infertility caused by residual intrauterine fetal bone after midtrimester abortion. *Am J Obstet Gynecol* 1997;176:369-70.
- [5] Ikechebelu JI, Eleje GU, Eke NO. Hysteroscopic removal of retained intrauterine fetal bone causing chronic pelvic pain. *Niger J Surg Sci* 2017;27:30-2.
- [6] Ganesh Acharya,Heulwen Morgan,Leslie Paramanatham,Regina Fernando.A randomized controlled trial comparing surgical termination of pregnancy with and without continuous ultrasound guidance. *European Journal of Obstetrics & Gynecology and Reproductive Biology* 2004:114(1); 69-74.

Citation: Swati Agrawal, Kiran Aggarwal, Manvi Dua, Ritika Choudhary, Alisha Sethi. *Retained Intrauterine Fetal Bone Fragments as a Cause of Abnormal Uterine Bleeding: An Unusual Case Report. Archives of Reproductive Medicine and Sexual Health. 2019; 2 (2): 29-31.*

Copyright: © 2019 Swati Agrawal, Kiran Aggarwal, Manvi Dua, Ritika Choudhary, Alisha Sethi. *This is an open access article distributed under the Creative Commons Attribution License, which permits unrestricted use, distribution, and reproduction in any medium, provided the original work is properly cited.*