

Enormous Intraligamentary Uterine Fibroids in Young Patient-Laparoscopic Approach

Sofoudis Chrisostomos^{1*}, Dedoulis Evaggelos², Zioris Konstantinos²

^{1*}Department of Obstetrics and Gynecology Konstandopoulio General Hospital, Athens, Greece.

²Mitera Maternal Hospital, Athens, Greece.

chrisostomos.sofoudis@gmail.com

**Corresponding Author: Dr. Chrisostomos Sofoudis, Ippokratous 209, Athens, Greece.*

Abstract

Fibroids represent benign tumors consisting of smooth muscle cells and fibrous connective tissue. In most of cases, they develop inside the uterine cavity.

It is estimated that 70-80% of women will develop fibroids in their lifetime—however, not everyone will develop symptoms or require treatment.

Cause of uterine fibroids is not known, although studies demonstrate there may be a genetic component. There is no food or external exposure that a woman can have that can cause her to develop fibroids.

Ultimate goal remains fertility preservation, especially in young premenopausal patients.

Laparoscopic approach represents proper surgical option depending on the age of the patient, the size and anatomic location of the uterine fibroids.

Keywords: *Uterine fibroid, Laparoscopy, Dissection, Intraligamentary approach.*

INTRODUCTION

Fibroids consist benign tumors (non-cancerous) that grow from muscle layers of the uterus. [1]

They can grow on the outside, inside or within the smooth muscle of the uterine wall. There represent 5 different classifications of fibroids such as *intramural, subserosal, submucosal, intracavity and cervix fibroids*. [2]

Most important complications of uterine fibroids reflect uterine bleeding, abdominal pain concerning the size of the fibroid and similar abdominal pressure leading to urine or intestinal difficulties, menorrhagia or metrorrhagia.

Intraligamentary uterine fibroids are located in the anatomic parametrial region, endorsed inside the broadligaments. [3]

Anatomic depiction of parametrium bilaterally, consists important step for benign procedures such as abdominal hysterectomy, or malignant procedures such radical abdominal hysterectomy.

This anatomic region increases the difficulty level of the dissection, due to its relation with ureter and large vessels. [4]

Our goal is to demonstrate and depict safe surgical procedure and dissection of uterine fibroids, respecting first of all, all involving anatomic margins.

Assiduous anatomic experience, meticulous hemostasis, suturing and washing of the peritoneal cavity are mandatory.

They represent necessary conditions proper surgical confrontation. Following these clinical steps, we managed to perform uneventful surgical procedure, securing the successful rate of the operation.

CASE

We present a case of a 30-year-old female patient *G2P2*, with negative atomic or gynecologic history, complaining of abdominal pain and episodes of menorrhagia.

Enormous Intraligamentary Uterine Fibroids in Young Patient-Laparoscopic Approach

Pap smear revealed no signs of malignancy. Transvaginal ultrasound scanning depicted presence of *two intraligamentary uterine fibroids* maximal diameter 6 cm located in the anatomic region of right broad ligament followed by *four intramural and three subserosal* uterine fibroids with maximal diameter 3 and 2 cm respectively.

Abdominal MRI confirmed all transvaginal imaging findings. Diagnostic curettage excluded any clinical potential of malignancy.

Therapeutic mapping depending on age of the patient and fertility preservation considered appropriate the laparoscopic approach.

Patient underwent laparoscopic dissection of *two enormous intraligamentary* maximal diameter 6 cm

buried into the anatomic region of right broad ligament, *four intramural* and *three subserosal uterine fibroids*. (Figure I.)

Intraoperatively injection of *pitressin* solution inside the fibroid cavity was performed in order to decrease and minimize any operative bleeding. (Figure II.)

Laparoscopic suturing of right parametrium, assiduous hemostasis and proper washing of the peritoneal cavity considered to be gold standard of the procedure. (Figure III.)

Final histological report confirmed all preoperative findings excluding signs of malignancy.

Patient discharged from hospital the following day in good clinical condition.

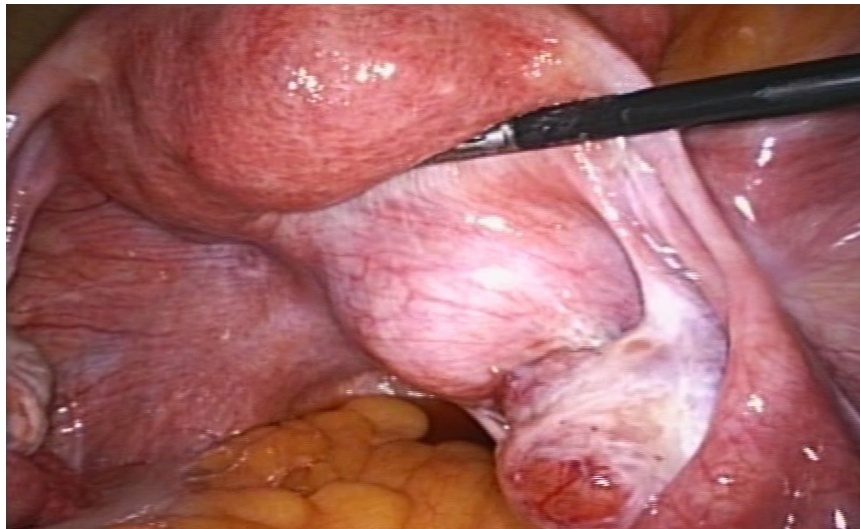


Fig I. Intraligamentary uterine fibroid

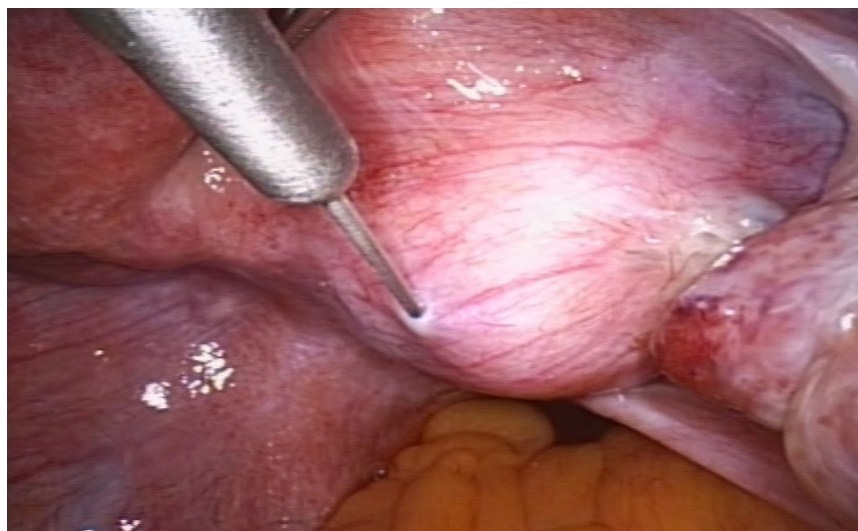


Fig II. Pitressin infusion

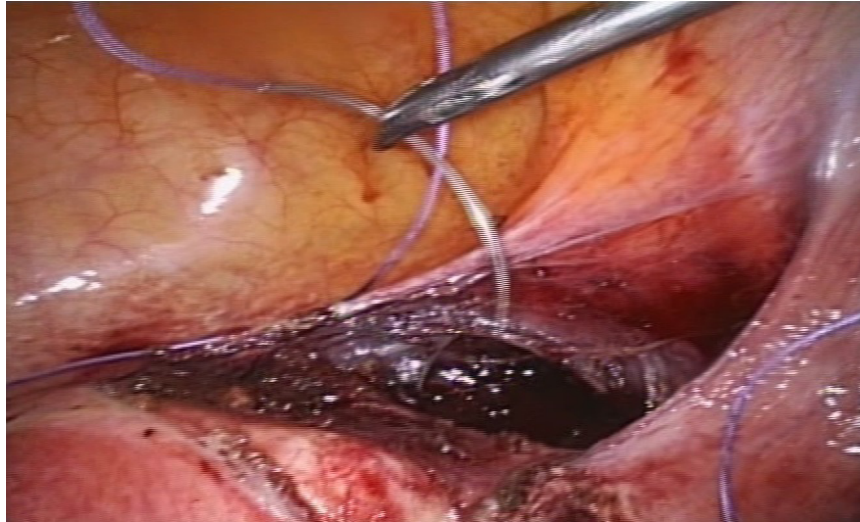


Fig III. *Intraligamentary suturing*

DISCUSSION

Uterine fibroids depict benign tumors affecting with mean incidence of 70 % daily chores of women in reproductive age. [5]

Abdominal pain, menorrhagia or metrorrhagia as examples of vaginal bleeding due to size and anatomic location of leiomyomas, lead to proper diagnosis and meticulous therapeutic mapping.

Assiduous atomic history, laboratory examinations, transvaginal ultrasound and pelvic MRI, consist necessary steps towards ultimate therapeutic strategy, focusing always on fertility preservation in women of reproductive age.

Intraligamentary uterine fibroids, due to their difficult anatomic penetration, represent eventful clinical procedures. [6]

Cystic, hyaline, myxoid or red degeneration, presence of parasitic vessels or enlarged size of the leiomyoma, can lead as pelvic MRI imaging findings into sarcomatous metaplasia and development of leiomyosarcomas. [7]

Hypoechogenic areas typical of leiomyosarcomas may also be found in necrotic myomas, whereas rapid tumor growth, features of neovascularity, significant flow-rate and low resistance flow are characteristic for malignant lesions.

Salman et al. reported a sixth case of lipoleiomyoma of broad ligament which was diagnosed in a postmenopausal woman who underwent exploratory laparotomy with a preoperative diagnosis of a solid adnexal mass suggesting an ovarian malignancy. [8]

Therapeutic penetration must be thorough, accurate, preserving anatomic margins which endorse anatomic structures such as great vessels and the ureter.

In cases of enlarged intraligamentary uterine fibroids with similar collateral vessels, embolization of uterine vessels seems to be alternative procedure, in order to decrease potential intraoperative uterine bleeding.[9]

CONCLUSION

Intraligamentary uterine fibroids represent sub-classification with small incidence but large amount of intra- and postoperative complications.

This anatomic region consists great surgical challenge depending always on surgical experience.

In cases of young premenopausal patients laparoscopic approach represents always the gold standard.

REFERENCES

- [1] Ikhen DE, Bulun SE. Literature Review on the Role of Uterine Fibroids in Endometrial Function. *Reprod Sci.* 2018 May; 25(5): 635-643.
- [2] Juhasz-Böss I, Jungmann P, Radosa J, von Heesen A, Ströder R, Juhasz-Böss S, et al. Two novel classification systems for uterine fibroids and subsequent uterine reconstruction after myomectomy. *Arch Gynecol Obstet.* 2017 Mar; 295(3): 675-680.
- [3] Cărăuleanu A, Socolov R, Lupașcu IA, Rugină V, Socolov D. Giant intraligamentary uterine leiomyoma and its complications. *Rev Med Chir Soc Med Nat Iasi.* 2016 Jan-Mar; 120(1):145-51.

Enormous Intraligamentary Uterine Fibroids in Young Patient-Laparoscopic Approach

- [4] Chmaj-Wierzchowska K, Buks J, Wierzchowski M, Szymanowski K, Opala T. Leiomyoma cellulare in the broad ligament of the uterus--case report and review of literature. *Ginekol Pol.* 2012 Apr; 83(4): 301-4. Review.
- [5] Stewart EA, Laughlin-Tommaso SK, Catherino WH, Lalitkumar S, Gupta D, Vollenhoven B. Uterine fibroids. *Nat Rev Dis Primers.* 2016 Jun 23; 2:16043.
- [6] Panarese A, Pironi D, Pontone S, Vendettuoli M, De Cristofaro F, Antonelli M, Romani A, Filippini A. A case of symptomatic mass in the right iliac fossa: a Bermuda Triangle which often lies the right diagnosis. *Ann Ital Chir.* 2014 Feb 24;85.
- [7] Jondal DE, Wang J, Chen J, Gorny KR, Felmlee J, Hesly G, et al. Uterine fibroids: correlations between MRI appearance and stiffness via magnetic resonance elastography. *Abdom Radiol (NY).* 2018 Jun;43(6):1456-1463.
- [8] Salman Mc, Atak Z, Usubutun A, Yuce K. Lipoleiomyoma of broad ligament mimicking ovarian cancer in a postmenopausal patient: case report and literature review. *J Gynecol Oncol.* 2010, 21, 62-64.
- [9] Matsubara S. Uterine Artery Embolization before Delivery to Prevent Postpartum Hemorrhage. *J Vasc Interv Radiol.* 2016 Jul; 27(7): 1101-2.

Citation: Sofoudis Chrisostomos, Dedoulis Evaggelos, Zioris Konstantinos. *Enormous Intraligamentary Uterine Fibroids in Young Patient-Laparoscopic Approach. Open Access Journal of Gynecology and Obstetrics.* 2019; 2(2): 17-20.

Copyright: © 2019 Sofoudis Chrisostomos, Dedoulis Evaggelos, Zioris Konstantinos. *This is an open access article distributed under the Creative Commons Attribution License, which permits unrestricted use, distribution, and reproduction in any medium, provided the original work is properly cited.*