

## Evaluation of a Patient with Penetrating Thoracic Injury in Covid-19 Pandemic & Further Consequence

Dr. Faruquzzaman, FCPS, MS, MRCS, MCPS

FCPS (Surgery), MS (Surgery), MRCS (Edinburgh, UK), MCPS (Surgery), Assistant registrar, Dept. of Surgery, Khulna Medical College Hospital, Bangladesh.

*\*Corresponding Author:* Dr. Faruquzzaman, FCPS, MS, MRCS, MCPS, Assistant registrar, Dept. of Surgery, Khulna Medical College Hospital, Bangladesh.

### Abstract

*The whole world is affected by the largest pandemic ever in the history of mankind. In such situation now-a-days the incidence of penetrating violence by teda is increasing in many developing counties like us. The bitter fact is that, most often, it is said by many of the patients that teda is a very useful weapon to keep in fight maintain the social distance in this very COVID situation. However, the magnitude of injuries and further consequence are distressful. Let us see.*

**Keywords:** Penetrating injury, thoracic trauma, violence, teda injury.

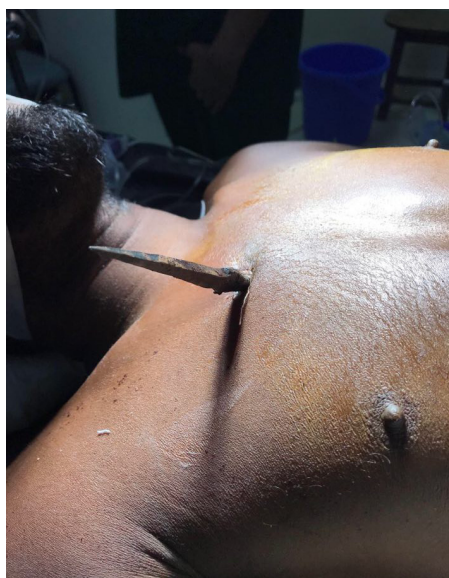
### INTRODUCTION

Trauma continues to be a major public health problem worldwide, as it is associated with high morbidity and mortality in both developed and developing countries, with approximately 5.8 million deaths worldwide. Trauma has also been reported to be the leading cause of death, hospitalization and long-term disabilities in the first four decades of life<sup>1,2</sup>. Thoracic trauma comprises 20–25% of all traumas worldwide and constitutes the third most common cause of death after abdominal injury and head trauma in polytrauma patients<sup>3,4</sup>. It directly accounts for approximately 25% of trauma-related mortality and is a contributing factor in another 25% of such cases<sup>5</sup>. During the first hour after hospital admission, thoracic vascular and neurologic trauma are the most common causes of death<sup>5,6</sup>. The presence of an interdisciplinary team with high experience in anaesthesia, critical care and surgical disciplines, especially neurosurgery, trauma surgery, abdominal surgery and thoracic surgery, is mandatory to ensure high-quality management with low morbidity and mortality rates in these patients<sup>6</sup>.

### CASE PRESENTATION

A 25 years gentleman has been referred to the Dept. of Casualty, Dhaka Medical College Hospital (DMCH),

Bangladesh, with history teda injury from physical violence about 4 hours back. On examination, he was haemodynamically unstable. After initial resuscitation (ATLS protocol), chest radiograph & CT scan of chest was done on urgent basis.



**Figure1.** Patient with teda injury

### On Investigation

Chest radiograph (left lateral view): Pathway of injury was seen. Retained teda appeared to pierce the great

## Evaluation of a Patient with Penetrating Thoracic Injury in Covid-19 Pandemic & Further Consequence

vessels and lung tissue (left). CT scan of chest (coronal section) confirmed the magnitude of injury.

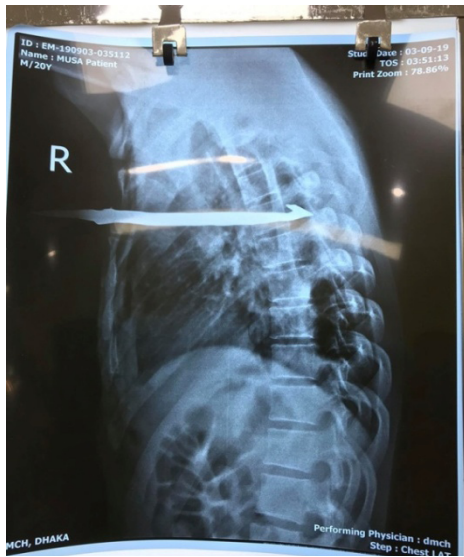

Figure 2. Chest X-ray (left lateral view).

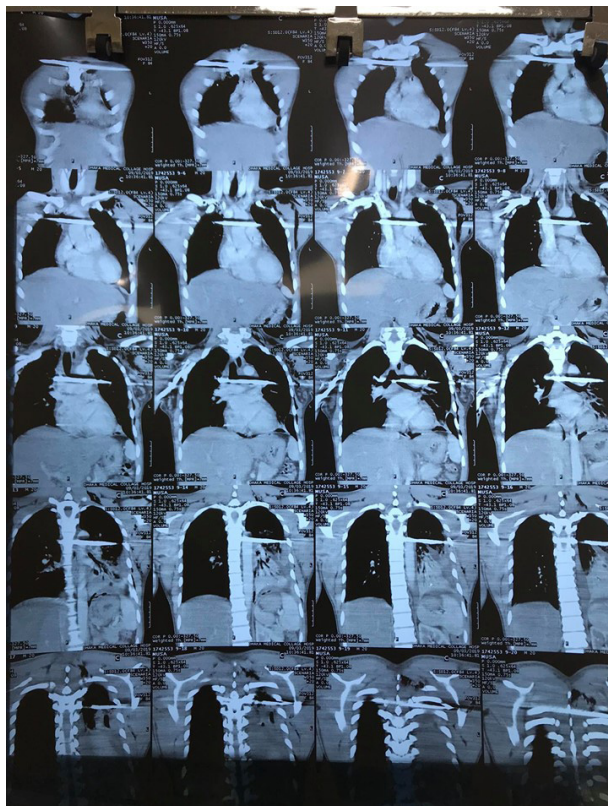


Figure 3. CT scan of chest (coronal section).

### Emergency Operation

With all available precaution, emergency Thoracotomy was done through Sternotomy under general anaesthesia. This surgery was performed in collaborate with the Dept. of Vascular Surgery & Dept. of Thoracic Surgery, DMCH.

### Sternotomy Findings

The teta was found piercing the right lung, the arch of the aorta, portion of the pulmonary trunk and ultimately portion of left lung and was impacted into the left scapula.

### Operative Procedure

A decision of femoro-femoral bypass was taken by the joint surgical team. After connecting with the heart lung machine, attempt of removing the teta started. A protruded portion of the teta was cut first with a haxo blade. Then the distal part of the teta was dislodged from the left scapula. And by gentle traction it was removed. The portion of arch of aorta and pulmonary trunk that severed was sutured with pledgeted double armed 5-0 polypropylene sutures in continuous fashion. Heparin flushing wash continued during the repair. After the repair was successful the bypass was reverted. Two chest drain tubes and one mediastinal drain tubes were kept in situ and the sternotomy was closed with wires and other wounds were closed accordingly. But during closure the patient, suddenly went into cardiac arrest. The arrest was reverted by the help of intra cardiac pacing leads.

### Ultimate Outcome

Finally when the patient was being reversing from the general anaesthesia, he went into cardiac arrest again but this time it could not be reverted. Unfortunately the patient succumbed.

### Other Case of Teta Injury in Khulna Medical College Hospital, Bangladesh During Covid-19 Pandemic

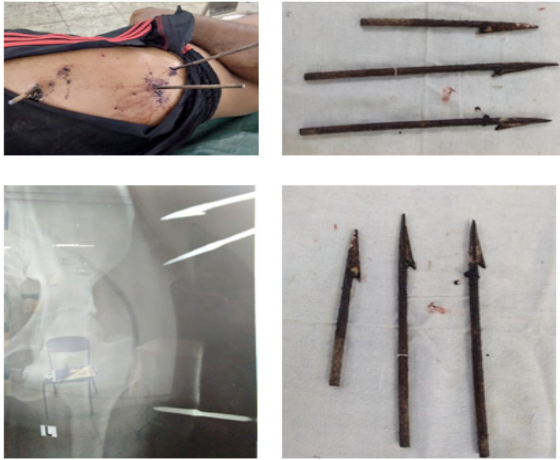#### Case 1.



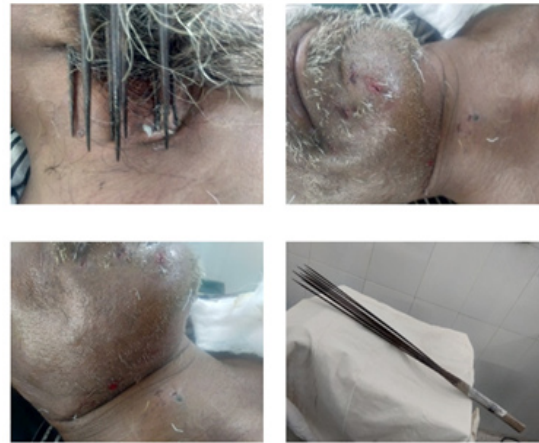

Evaluation of a Patient with Penetrating Thoracic Injury in Covid-19 Pandemic & Further Consequence

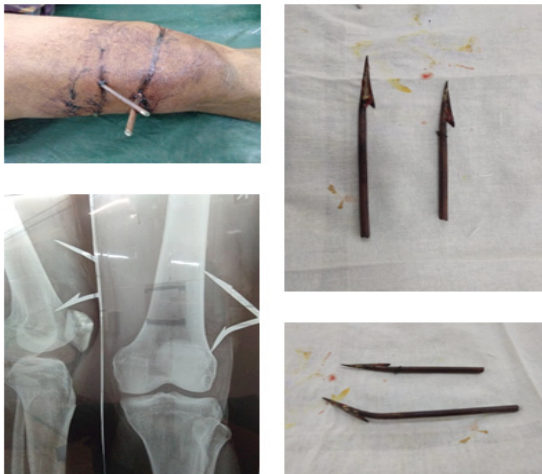Case 2.



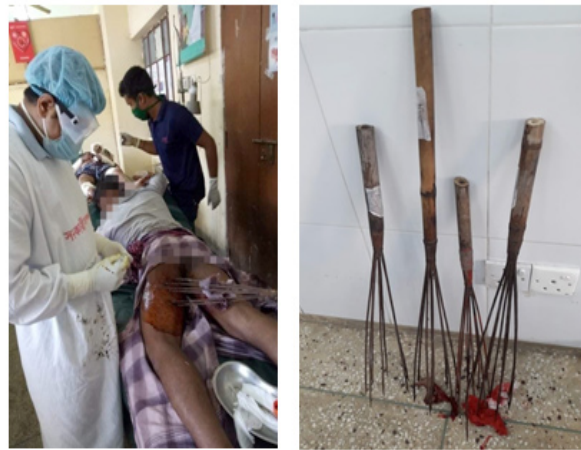Case 5.



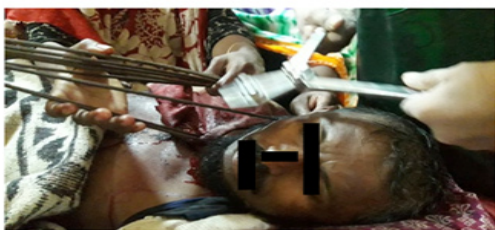Case 3.



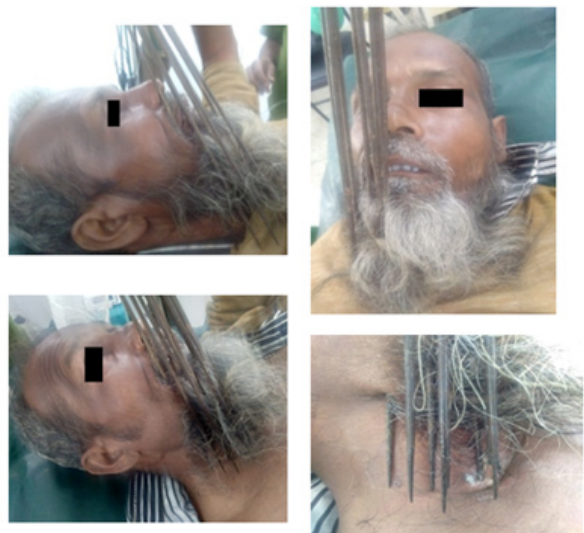Case 6.



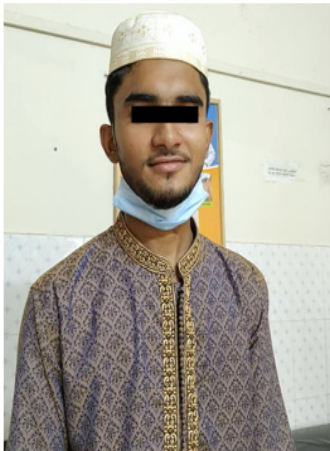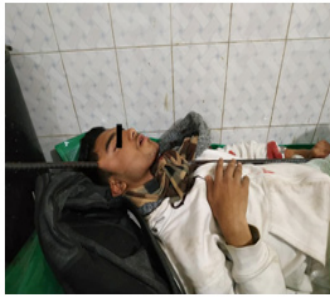Case 4.



Case 7.



Case 8.



REFERENCES

- [1] Krug EG, Sharma GK, Lozano R. The global burden of injuries. *Am J Public Health.* 2000;90:523–6.
- [2] Hoyt DB, Coimbra R, Potenza B. In: Sabiston textbook of surgery. Management of acute trauma. Elsevier; 2004.; pp. 483–532.
- [3] Demirhan R, Onan B, Oz K, Halezeroglu S. Comprehensive analysis of 4205 patients with chest trauma: a 10-year experience. *Interact Cardiovasc Thorac Surg.* 2009;9(3):450–3.
- [4] Lecky FE, Bouamra O, Woodford M, Alexandrescu R, O'Brien SJ. In: Pape H-C, Peitzman AB, Schwab CW, Giannoudis PV, editors. *Epidemiology of polytrauma.* New York: Springer: Damage Control Management in the Polytrauma Patient; 2010. p. 13–24.4.
- [5] O'Connor JV, Adamski J. The diagnosis and treatment of non-cardiac thoracic trauma. *J R Army Med Corps.* 2010;156(1):5–14.
- [6] Wilson RF, Murray C, Antonenko DR. Nonpenetrating thoracic injuries. *Surg Clin North Am.* 1977;57:17–36.

**Citation:** Dr. Faruquzzaman. *Evaluation of a Patient with Penetrating Thoracic Injury in Covid-19 Pandemic & Further Consequence.* *Archives of Radiology.* 2020; 3(1): 22-25.

**Copyright:** © 2020 Dr. Faruquzzaman. This is an open access article distributed under the Creative Commons Attribution License, which permits unrestricted use, distribution, and reproduction in any medium, provided the original work is properly cited.