

Portal Annular Pancreas with Portal Cavernoma Formation with Associated Dorsal Pancreatic Agenesis - A Rare Case Report

Lokesh Rana, Dinesh Sood, Ankur Diwedi, Parminder, Saurabh Kumar Sahu, Narvir S. Chauhan

Assistant Professor, Department of Radio-diagnosis, Dr. RPGMC, Kangra at Tanda, Himachal Pradesh, India.

Professor, Department of Radio-diagnosis, Dr. RPGMC, Kangra at Tanda, Himachal Pradesh, India.

Consultant Radiologist, Forit Hospitals Mohali, Punjab, India.

Resident Department of Radio-diagnosis, Dr. RPGMC, Kangra at Tanda, Himachal Pradesh, India.

Associate Professor, Department of Radio-diagnosis, Dr. RPGMC, Kangra at Tanda, Himachal Pradesh, India.

*Poojalokesh2007@gmail.com; sud.dinesh59@gmail.com

ankur2627@gmail.com; drparmindersangha@gmail.com

dr.saurabhkumarsahu@gmail.com; drnarvir@gmail.com

***Corresponding Author:** Lokesh Rana, Assistant Professor, Department of Radio-diagnosis, Dr. RPGMC, Kangra at Tanda, Himachal Pradesh, India.

Abstract

Portal annular pancreas is an uncommon congenital anomaly resulting from fusion of the pancreatic parenchyma around the portal vein. Its causing portal cavernoma formation and association with dorsal pancreatic agenesis is rare **Case Report** We report a 51-year-old female who underwent contrast enhanced computed tomography for vague right hypochondrial pain. On CECT abdomen images there was presence of ring of pancreatic tissue around the portal vein causing its luminal narrowing with proximal dilation of portal vein tributaries with cavernoma formation. There was also presence of agenesis of dorsal pancreas in this patient.

Conclusion: This variant of portal annular pancreas with cavernoma formation associated with dorsal pancreatic agenesis has not yet been reported and we propose a new CT classification of the same.

CASE REPORT

Portal annular pancreas (PAP) is an uncommon and under-recognized congenital anomaly of the pancreas and with cavernoma formation with associated dorsal pancreatic agenesis is rarest and not been reported in the literature. In contrast to a conventional annular pancreas in which the pancreatic tissue encircles the second part of the duodenum, portal annular pancreas is characterized by encasement of the portal vein by ring of pancreatic parenchymal tissue^{1,2}.

We noted, on an axial abdominal computed tomography study of a 69-year-old female with chronic vague pain in right hypochondriac region, anomalous pancreatic parenchyma encircling the main portal vein with

proximal dilation of the portal vein tributaries with consequent cavernoma formation. There was also presence of agenesis of dorsal pancreatic tissue^{3,4,5,6}. (Fig.)

Pancreas develops from a ventral and a dorsal bud of the duodenum^{2,8,9}. The ventral bud forms the major part of the head and the uncinate process, whereas the dorsal bud forms upper part of the head, the body, and tail of the pancreas. The ventral bud rotates posteriorly during the 7th week of gestation to fuse with the dorsal bud so as to form the fully mature gland¹⁰. Rarely, this fusion occurs to the left of the mesenteric or portal vein, resulting in a encircling pancreatic parenchymal tissue around the portal vein. This has been referred to as the portal annular

Portal Annular Pancreas with Portal Cavernoma Formation with Associated Dorsal Pancreatic Agenesis - A Rare Case Report

pancreas. Karasaki *et al*¹, and Ishigami *et al*¹³ in their studies concluded that the prevalence of portal annular pancreas is not extremely low but is not readily recognized on preoperative imaging due to lack of adequate knowledge and awareness of this uncommon variant but its association with dorsal pancreatic tissue has not been reported yet^{11,12,13}.

Imaging plays a pivotal role in the diagnosis of portal annular pancreas and contrast-enhanced multi-detector computed tomography (MDCT) is considered sufficient enough to establish the diagnosis. Joseph *et al*⁴. Have classified PAP into 3 types. In type I the ventral bud of the pancreas fuses with the dorsal bud posterior to the portal vein with a retroportal pancreatic duct (as is seen in the present case); type II has concomitant pancreas divisum; and type III is when the uncinate process alone is involved and the pancreatic duct is seen anterior to the portal vein (anteportal pancreatic duct)^{3,7,14,16}.

Another classification describes this entity as suprasplenic (commonest), infrapleptic, and mixed type based on the fusion of uncinate process with the body posteriorly above or below the level of the splenoportal confluence. It may be associated with the abnormal course of pancreatic duct (retroportal pancreatic duct) or pancreatic divisum^{17,18}.

We propose a new classification of this entity with two groups.^{1,3,19,20}

Group A-Portal annular pancreas (PAP) without complications

Group B-Portal annular pancreas (PAP) with complication of portal hypertension, pancreatitis, obstructive biliopathy etc.

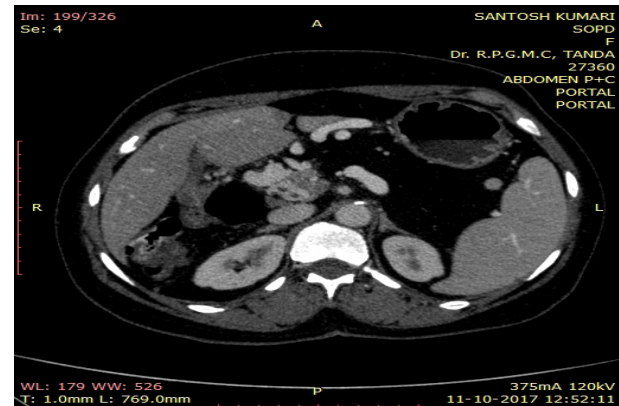
Type I-Ventral bud fuses with the dorsal bud posterior to portal vein forming a ring of pancreatic tissue around portal vein

Type II-Pancreatic divisum

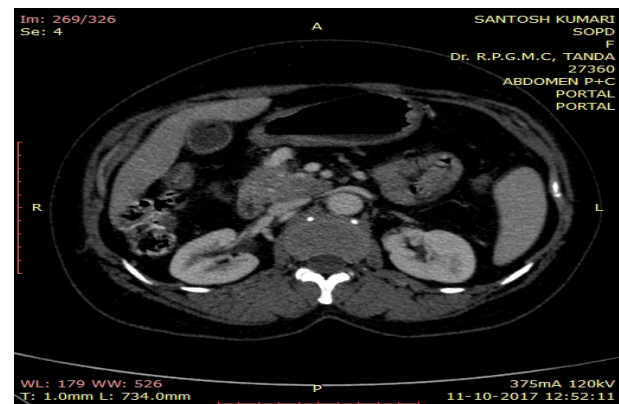
Type III-Anteportal pancreatic Duct

Type IV-Associated dorsal pancreatic agenesis

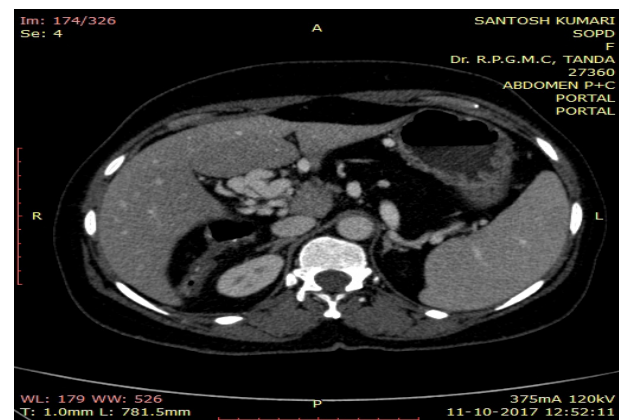
Images



a)



b)



c)

CECT images portal venous phase of 31 year old female showing (fig a) a ring of pancreatic tissue around portal vein (arrow) causing its luminal narrowing. There is presence of dorsal agenesis of pancreas (fig b) with dependant viscera sign(arrow). This is Type IV portal annular pancreas according to the new classification described in the text. (Fig c) shows dilated proximal portal channels with cavernoma formation (arrow).

Portal Annular Pancreas with Portal Cavernoma Formation with Associated Dorsal Pancreatic Agenesis - A Rare Case Report

Our case is type IV and computed tomography scan is usually adequate for diagnosing this anomaly, which can be demonstrated by continuity of the extension of the uncinate process into the body of the pancreas in more than 2 slice however, the presence of the anomaly of pancreatic ducts can also be suggested by demonstrating the abnormal course of the pancreatic duct when present which can be depicted on MRCP or ERCP^{21,22}.

CONCLUSION

PAP is a rare anomaly and cavernoma formation with associated dorsal pancreatic agenesis more rarer. We emphasize on the new classification system which lay stress on complication associated with it and co-existent congenital anomalies of pancreas.

REFERENCES

- [1] Karasaki H, Mizukami Y, Ishizaki A, et al. Portal annular pancreas, a notable pancreatic malformation: frequency, morphology, and implications for pancreatic surgery. *Surgery*. 2009;146:515–518.
- [2] Matsumoto I, Shinzeki M, Fukumoto T, et al. An extremely rare portal annular pancreas for pancreaticoduodenectomy with a special note on the pancreatic duct management in the dorsal pancreas. *Surgery*. 2013;153: 434–436.
- [3] Savastano S, Alessi S, Fantozzi O, et al. MRI diagnosis of a periportal annular pancreas. *Euro J Radiol Extra*. 2004;50:93–95.
- [4] Gonoï W, Akahane M, Akai H, et al. Retroportal main pancreatic duct with circumportal pancreas: radiographic visualization. *Clin Imaging*. 2011;35:442–446.
- [5] Hashimoto Y, Ross AS, Traverso LW. Circumportal pancreas with retroportal main pancreatic duct. *Pancreas*. 2009;38:713–715.
- [6] Leyendecker JR, Baginski SG. Complete pancreatic encasement of the portal vein (circumportal pancreas): imaging findings and implications of a rare pancreatic anomaly. *J Comput Assist Tomogr*. 2008;32:61–64.
- [7] Marjanovic G, Obermaier R, Benz S, et al. Complete pancreatic encasement of the portal vein—surgical implications of an extremely rare anomaly. *Langenbecks Arch Surg*. 2007;392:489–491.
- [8] Song SY, Oh JY, Kim Y, et al. Complete pancreatic encasement of portal vein: circumportal pancreas. *Eur Radiol Suppl*. 2008;18:350.
- [9] Yamazaki S, Kaneko T, Fujinaga Y, et al. CT and MRI features of unclassifiable pancreatic anomaly with superior mesenteric vein running through the pancreatic parenchyma. *Eur J Radiol Extra*. 2005;54:59–61.
- [10] Kin T, Shapiro J. Partial dorsal agenesis accompanied with circumportal pancreas in a donor for islet transplantation. *Islets*. 2010;2:146–148.
- [11] Sugiura Y, Shima S, Yonekawa H, et al. The hypertrophic uncinate process of the pancreas wrapping the superior mesenteric vein and artery—a case report. *Jpn J Surg*. 1987;17:182–185.
- [12] Truty MJ, Smoot RL. Animal models in pancreatic surgery: a plea for pork. *Pancreatol*. 2008;8:546–550.
- [13] Ishigami K, Tajima T, Nishie A, et al. The prevalence of circumportal pancreas as shown by multidetector-row computed tomography. *Insights Imaging*. 2011;2:409–414.
- [14] Joseph P, Raju RS, Vyas FL, et al. Portal annular pancreas. A rare variant and a new classification. *JOP*. 2010;11:453–455.
- [15] Moher D, Liberati A, Tetzlaff J, et al. Preferred reporting items for systematic reviews and meta-analyses: the PRISMA statement. *PLoS Med*. 2009;6:e1000097.
- [16] Bassi C, Dervenis C, Butturini G, et al. Postoperative pancreatic fistula: an international study group (ISGPF) definition. *Surgery*. 2005;138:8–13.
- [17] Hamanaka Y, Evans J, Sagar G, et al. Complete pancreatic encasement of the proximal hepatic portal vein: a previously undescribed congenital anomaly. *Br J Surg*. 1997;84:785.

Portal Annular Pancreas with Portal Cavernoma Formation with Associated Dorsal Pancreatic Agenesis - A Rare Case Report

- [18] Izuishi K, Wakabayashi H, Usuki H, et al. Anomalous annular pancreas surrounding the superior mesenteric vessel. *ANZ J Surg.* 2010;80:376–377.
- [19] Jang JY, Chung YE, Kang CM, et al. Two cases of portal annular pancreas. *Korean J Gastroenterol.* 2012;60:52–55.
- [20] Kin T, Shapiro AM. Circumportal pancreas and islet isolation. *Surgery.* 2009;146:126–127.
- [21] Kobayashi S, Honda G, Kurata M, et al. Pancreaticoduodenectomy in portal annular pancreas: report of a case. *Surg Today.* 2013; 43:926–929.
- [22] Mizuma M, Suzuki M, Unno M, et al. A case of “portal annular pancreas” in that the ventral pancreas joins with the pancreatic body encircling the portal vein. *Tan to Sui.* 2001;22:963–966.

Citation: Lokesh Rana, Dinesh Sood, Ankur Diwedi, et al. *Portal Annular Pancreas with Portal Cavernoma Formation with Associated Dorsal Pancreatic Agenesis - A Rare Case Report. Archives of Oncology and Cancer Therapy.* 2018; 1(2): 10-13.

Copyright: © 2018 Lokesh Rana, Dinesh Sood, Ankur Diwedi, et al. This is an open access article distributed under the Creative Commons Attribution License, which permits unrestricted use, distribution, and reproduction in any medium, provided the original work is properly cited.