

CASE REPORT

Sonographic Diagnosis of Pneumoperitoneum: An Underused Examination Modality

Andrew Man Yuk LIM, Chi Leung TSUI

Accident and Emergency Department, Prince of Wales Hospital, Shatin, Hong Kong.

Received: 04 May 2024 Accepted: 20 May 2024 Published: 06 June 2024

Corresponding Author: Andrew Man Yuk LIM, Accident & Emergency Department, Main Clinical Block and Trauma Centre, Prince of Wales Hospital, Shatin, New Territories, Hong Kong.

Abstract

Pneumoperitoneum secondary to perforated viscus is a commonly encountered diagnosis within Emergency Medicine and General Surgery. Plain radiographs and computed tomography are considered the gold standard for diagnosis. However, such investigations may not be possible if the patient is too unstable, or due to resource limitations. In this study, we report a case of pneumoperitoneum diagnosed with point-of-care ultrasound, without relying on the aforementioned gold standard investigations.

A 50-year-old Chinese man presented to our Emergency Department with severe epigastric pain. Full physical examination and conventional plain radiography were not feasible due to the patient's distress. Point-of-care ultrasound was used to diagnose pneumoperitoneum, which was later confirmed with a CT scan after admission to the Surgical unit.

Therefore, the authors believe that point-of-care abdominal ultrasonography is a useful tool in diagnosing pneumoperitoneum. However, due to the lack of high-level evidence, it is currently unclear if this should be considered a routine examination in patients presenting with acute abdomen.

Keywords: PoCUS, Emergency Medicine, Ultrasonography, Pneumoperitoneum, Abdominal Pain.

1. Introduction

Pneumoperitoneum refers to the presence of air or another gas within the peritoneal cavity. This condition is most frequently caused by visceral perforation, such as from a perforated peptic ulcer. Patients with pneumoperitoneum secondary to perforated viscus generally present to the Emergency Department with "acute abdomen", or sudden severe abdominal pain. Physical examination, though a key part of a patient's evaluation, may sometimes be misleading or non-specific, such as in patients presenting in the late stages of their disease, or in patients who are cognitively impaired. Plain radiographs are a useful tool to identify bowel obstruction or pneumoperitoneum, but smaller pneumoperitonea may not be visualized clearly. CT is now regarded as the "gold standard",

or primary diagnostic option in patients with acute abdominal pain. However, while ultrasound is frequently criticized as being operator-dependent, CT is also dependent on experienced radiologists for image interpretation [1]. Rural communities may also lack access to 24-hour CT scanning. Point-of-care ultrasound (PoCUS) may be an alternative option for the rapid diagnosis of pneumoperitoneum. Though first reported in the 1980s, this technique remains relatively obscure due to the ubiquity of CT scanning [2]. In this article, we report on a case of pneumoperitoneum diagnosed with point-of-care ultrasound in the Emergency Department. However, literature review shows that there remains a lack of high-level evidence regarding the use of PoCUS in the diagnosis of pneumoperitoneum.

Citation: Andrew Man Yuk LIM, Chi Leung TSUI. Sonographic Diagnosis of Pneumoperitoneum: An Underused Examination Modality. Archives of Emergency Medicine and Intensive Care. 2024;5(1):8-13.

©The Author(s) 2024. This is an open access article distributed under the Creative Commons Attribution License, which permits unrestricted use, distribution, and reproduction in any medium, provided the original work is properly cited.

2. Case Presentation

A 50-year-old Chinese man arrived at our Emergency Department with a sudden onset of severe epigastric pain 7 hours ago. The pain was non-radiating, and he did not have any nausea, vomiting, diarrhea, or fever. He had a history of rheumatoid arthritis and was on Diclofenac as needed from our hospital's rheumatology clinic. He had been taking Diclofenac at 3 times the prescribed dose over the past month due to worsening joint pain, without taking the co-prescribed Pantoprazole.

He was afebrile with stable vitals and fully conscious on arrival. However, he was diaphoretic, and visibly

in severe pain. He had tenderness, guarding, and rigidity over his entire abdomen. He could not tolerate further physical examination due to distress. 50mg of Tramadol was given intravenously for analgesia, after which erect chest and abdomen radiographs were ordered. Unfortunately, the patient was unable to sit upright due to persistent severe pain despite IV analgesia, and our radiographer could only take supine films [Fig. 1, Fig. 2]. Point-of-care venous blood gas analysis showed a pH 7.31, pCO₂ 6.8kPa, Bicarbonate 25mmol/L, Base deficit 2, and Lactate 3mmol/L. Other blood tests were drawn, but were not available at the time of diagnosis.

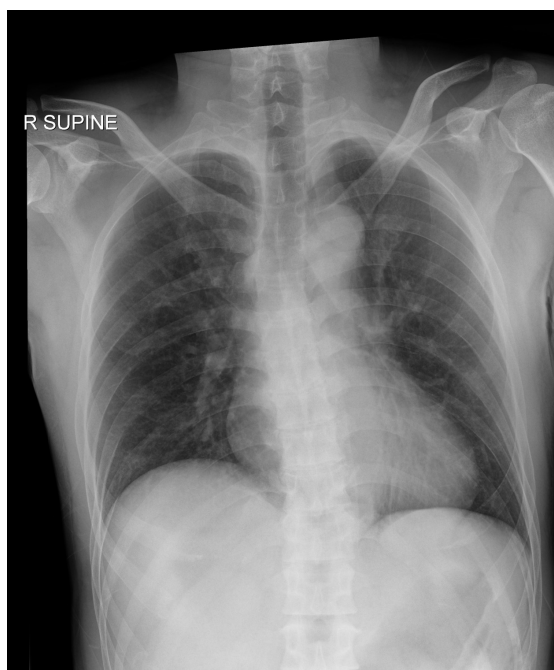


Figure 1. *Supine chest radiograph without subdiaphragmatic free gas.*

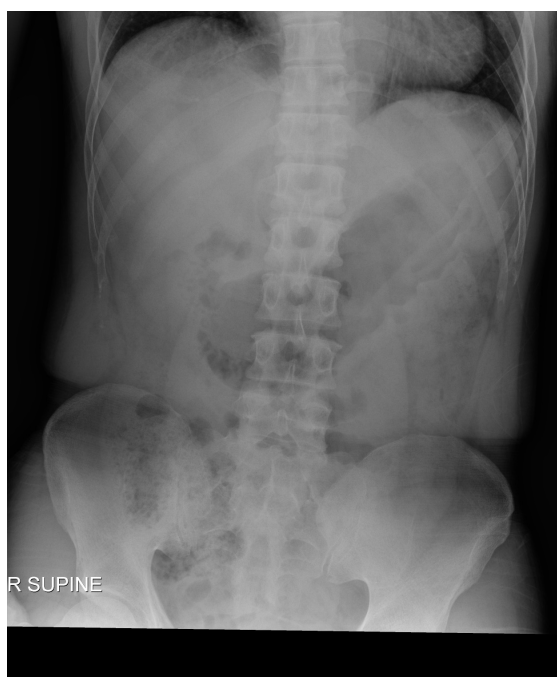

Figure 2. *Supine abdominal radiograph without Rigler sign.*

Point-of-care ultrasound was performed to guide further investigations. Dirty shadowing and enhanced peritoneal stripe sign (EPSS) were seen in the epigastric region immediately below the peritoneal stripe and above the left lobe of liver [Fig. 3]. Scanty

amount of free fluid was also detected at the tip of left liver lobe [Fig. 4]. A sonographic diagnosis of pneumoperitoneum secondary to perforated viscus was therefore made.

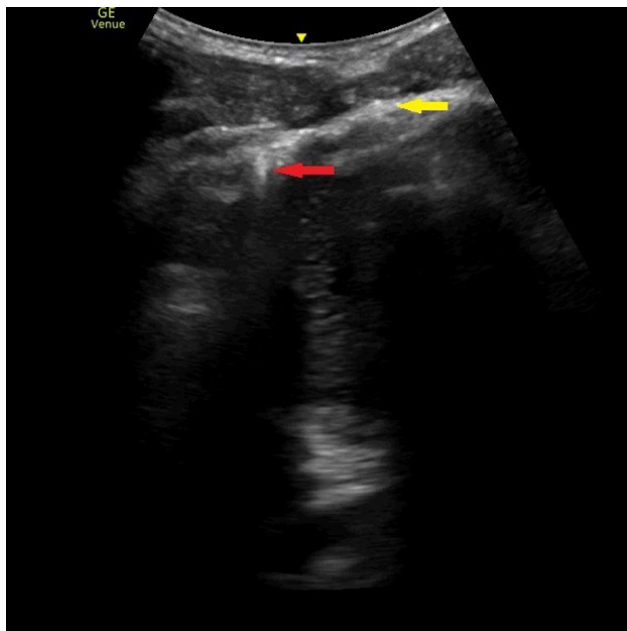


Figure 3. Signs of pneumoperitoneum in the epigastric region. Yellow arrow: Enhanced peritoneal stripe sign (EPSS). Red arrow: Dirty shadowing signifying local free gas. Decreased visualization of deeper structures is also an indirect sign of pneumoperitoneum.

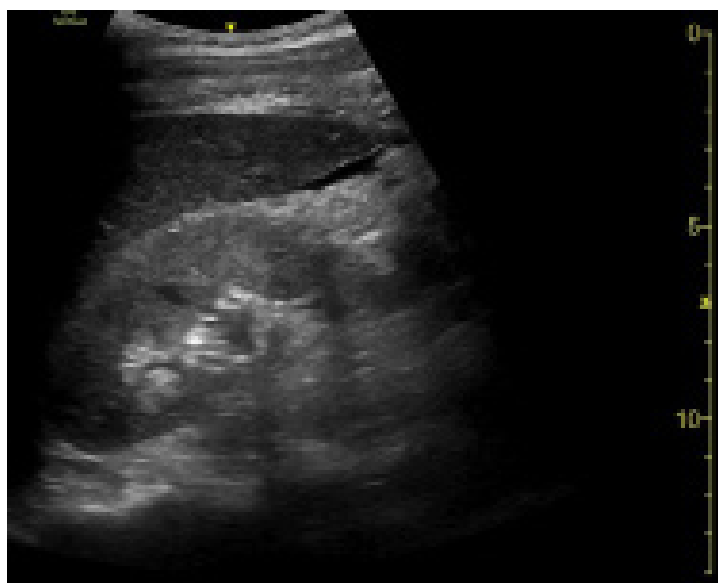

Figure 4. Scanty free fluid at the tip of the left lobe of liver.

Considering his serious condition, the patient was moved to our ED high dependency unit to expedite further management. Large-bore IV access was secured, through which a 500ml bolus of normal saline, and an additional 50mg bolus of IV Tramadol were given. The patient was admitted to the Surgical unit for treatment after prompt Surgical consultation. Lab blood tests were still in progress at the time of handover. The receiving Surgical Resident arranged an abdominal contrast CT after admission, which confirmed pneumoperitoneum secondary to duodenal

(D1) perforation [Fig 5]. Emergency laparoscopic Graham patch repair was performed on the same day within 3 hours of admission. He was found intraoperatively to have a 5mm perforated duodenal ulcer at the anterior aspect of D1, and a moderate amount of intraperitoneal purulent fluid and exudate. He was discharged on post-op day 5 uneventfully and was advised to stop using NSAIDs. The patient was booked for a General Surgery follow-up 6 months post-discharge, which has not been reached as of writing this report.

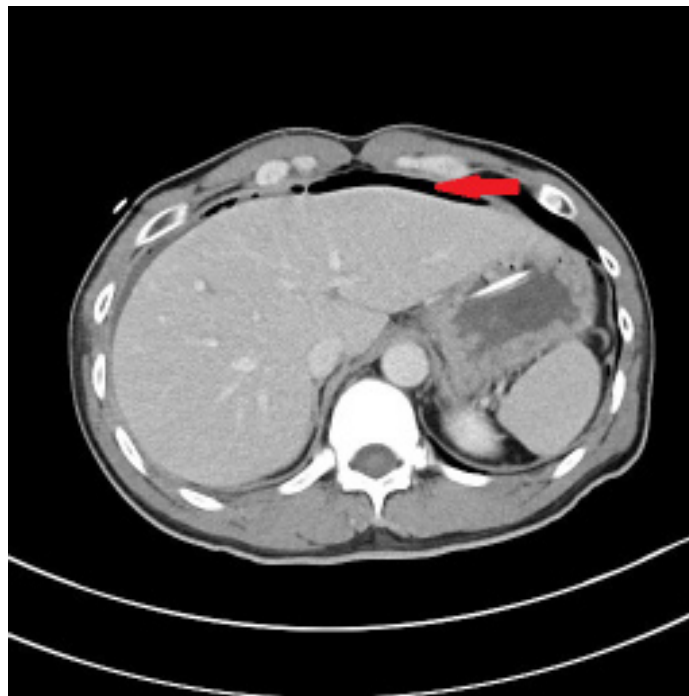


Figure 5. Abdominal contrast CT, showing pneumoperitoneum anterior to the left lobe of liver and in the epigastrium.

3. Discussion

As far as the authors are aware, this is the first case of pneumoperitoneum being diagnosed by emergency point-of-care ultrasound (PoCUS) in Hong Kong. A recent meta-analysis showed that PoCUS had a 91% sensitivity and 98% specificity in the diagnosis of gastrointestinal perforation in patients presenting with acute abdomen [3]. However, this meta-analysis was limited by insufficient eligible studies, varying inclusion criteria, inconsistency regarding sonographers' specialties and training, and a lack of standard scanning procedure [3]. Consequently, pneumoperitoneum is considered by some to be "terra ignota" in the field of emergency ultrasonography [4].

Seitz and Reising first described the ability to diagnose gastrointestinal perforation by identifying abdominal free gas through sonography back in 1982 [2]. Several publications in later years confirmed Seitz and Reising's findings that ultrasonography can be a useful tool for the diagnosis of pneumoperitoneum [3].

Various professional organizations, such as the Royal College of Emergency Medicine and the Royal College of Physicians and Surgeons of Canada, have included PoCUS into their respective postgraduate training curricula for emergency physicians. However, as of 2023, sonographic detection of pneumoperitoneum is not mentioned in their curricula as competencies [5, 6]. The American College of Emergency Physicians does not include bowel ultrasound (including detection of pneumoperitoneum) in their resident level training, instead placing it under their optional Emergency

Ultrasound Fellowship [7]. The Australian College of Emergency Medicine does not include diagnosis of pneumoperitoneum under their list of clinical indications for ultrasound imaging by emergency physicians, but instead writes in their policy titled "The use of focused ultrasound in emergency medicine" that they encourage further research into other known imaging techniques and modalities [8].

Plain radiographs and computed tomography remain the gold standard for diagnosis of pneumoperitoneum [9,10]. Chen et al's study in 2002 showed that upright chest radiographs with additional left lateral decubitus radiographs had a sensitivity of 79%, specificity of 64%, and PPV of 96% in detecting pneumoperitoneum, while he reports elsewhere that CT is the most sensitive imaging test, with a success rate of between 83-100% [11,12]. Furthermore, PoCUS remains an operator-dependent modality of imaging. There is also a high heterogeneity in the reported sensitivity and specificity of abdominal ultrasound: Schleder et al reported that ultrasound is inferior to abdominal radiography and computed tomography [13].

Both linear-array probes and curvilinear probes have been used in studies to detect intra-abdominal free gas. Most agree that the best place to start scanning is in the right hypochondrium superficial to the liver, with the patient supine but with the thorax slightly elevated. The patient may also be placed in a left semilateral decubitus position [14]. However, one must be aware that patient positioning can be limited depending on the patient's clinical condition.

Due to the nature of ultrasonography, so-called direct signs of pneumoperitoneum are not, in fact, direct. They are derived from the scattering of ultrasonic waves at the tissue-air interface, gas also referred to as impedance mismatch. There is a lack of evidence comparing the sensitivity and specificity of the various sonographic signs of pneumoperitoneum. Hoffmann et al discussed the various signs of intra-abdominal air in his 2012 review article. Larger air bubbles can be visualized as bright, highly echogenic lines with distal reverberation and shadowing artefacts, commonly referred to as ring-down artefacts. Smaller gas bubbles can appear as bright punctuate foci without any ring-down artefacts or shadowing. Dirty shadowing is another distinct sonographic sign, which appears as an irregular hyperechoic image with reverberation artefacts deep to the interface [15]. This is commonly seen during routine abdominal scanning but should not be present outside of the bowel [14,16].

Other more specific signs are also reported in literature, including the enhanced peritoneal stripe sign (EPSS), which includes an abnormally echogenic peritoneal reflection with horizontal reverberation artifacts below, and various other indirect signs, such as intraperitoneal free fluid, gas bubbles within ascitic fluid, and thickened bowel or gallbladder walls [17]. The “scissors manoeuvre” introduced by Karahan can also be used to increase the detection rate. It consists of scanning the right paramedial epigastric area with a parasagittally oriented linear-array probe. Free intraperitoneal gas shifts away and returns to the scanned area upon repeated application and release of probe pressure with the caudal part of the probe. This varying amount of gas can then be visualized with the direct signs listed above [18].

4. Conclusion

Further research is necessary to determine if abdominal ultrasonography should be a routine examination in patients presenting with acute abdomen. However, as highlighted in our case, there is a clear value for sonographic diagnosis of pneumoperitoneum in patients who are too ill to stand up or sit up for erect radiographs. It may prove to be an essential tool for rural emergency physicians when handling patients presenting with acute abdomen, particularly if they do not have any radiological service.

Ethics and other Declarations

Our institution does not require ethics approval for case reports. Written informed consent was obtained

from the patient for publication of this case report and any accompanying images.

The authors declare that they have no competing interests, and that they have no sources of funding for this research.

The patient was attended by both authors in the Emergency Department. This article was proposed by Dr. CL Tsui. Initial manuscript drafting was done by Dr. A Lim. Both authors were involved in editing the final manuscript and approved the submission.

5. References

1. Landmann A, Bonds M, Postier R. Chapter 46: Acute Abdomen. In: Townsend CM, Beauchamp RD, Evers BM, Mattox KL, eds. *Sabiston Textbook of Surgery*. 21st ed. Elsevier; 2022:1134-1149.
2. Seitz K, Reising KD. Sonographischer Nachweis freier Luft in der Bauchhöhle [Ultrasound detection of free air in the abdominal cavity]. *Ultraschall Med*. 1982;3(1):4-6.
3. Jiang L, Wu J, Feng X. The value of ultrasound in diagnosis of pneumoperitoneum in emergent or critical conditions: A meta-analysis. *Hong Kong J Emerg Med*. 2019;26(2):111-117. <https://doi.org/10.1177/1024907918805668>
4. Smereczyński A, Kołaczyk K. Is pneumoperitoneum the terra ignota in ultrasonography?. *J Ultrason*. 2015;15(61):189-195. <https://doi.org/10.15557/JoU.2015.0016>
5. Ultrasound Sub-Committee. SLO6 – Point of Care Ultrasound Competence Entrustment Scale: Guidance for Education and Training. Royal College of Emergency Medicine. https://res.cloudinary.com/studio-republic/images/v1660663850/SLO6_POCUS_Ultrasound_Competence_Entrustment_Scale_Aug_2022/SLO6_POCUS_Ultrasound_Competence_Entrustment_Scale_Aug_2022.pdf?i=AA. Published August 8, 2022. Accessed December 26, 2023.
6. Lewis D, Rang L, Kim D, et al. Recommendations for the use of point-of-care ultrasound (POCUS) by emergency physicians in Canada. *CJEM*. 2019;21(6):721-726. <https://doi:10.1017/cem.2019.392>
7. Lewiss RE, Tayal VS, Hoffmann B, et al. The core content of clinical ultrasonography fellowship training. *Acad Emerg Med*. 2014;21(4):456-461. <https://doi:10.1111/acem.12349>
8. ED Ultrasound Committee. The use of focused ultrasound in emergency medicine. Australasian College of Emergency Medicine. https://acem.org.au/getmedia/000b84ee-378f-4b65-a9a7-c174651c2542/Policy_on_the_Use_of_Focused_Ultrasound_in_

- Emergency_Medicine. Published July 2022. Accessed December 26, 2023.
9. Chao A, Gharahbaghian L, Perera P. Diagnosis of pneumoperitoneum with bedside ultrasound. *West J Emerg Med.* 2015;16(2):302. <https://doi.org/10.5811/westjem.2014.12.24945>
 10. Ko YC, Ong HN. Elderly man with abdominal pain. *J Am Coll Emerg Physicians Open.* 2020;1(5):1110-1111. Published 2020 Jul 3. <https://doi.org/10.1002/emp2.12162>
 11. Chen SC, Wang HP, Chen WJ, et al. Selective use of ultrasonography for the detection of pneumoperitoneum. *Acad Emerg Med.* 2002;9(6):643-645. <https://doi.org/10.1111/j.1553-2712.2002.tb02307.x>
 12. Chen SC, Yen ZS, Wang HP, Lin FY, Hsu CY, Chen WJ. Ultrasonography is superior to plain radiography in the diagnosis of pneumoperitoneum. *Br J Surg.* 2002;89(3):351-354. <https://doi.org/10.1046/j.0007-1323.2001.02013.x>
 13. Schleder S, Jung EM, Heiss P, Stroszczyński C, Schreyer AG. Hand-carried and high-end ultrasound systems are equally inferior to abdominal radiography and multidetector computed tomography in the diagnosis of pneumoperitoneum. *Rofo.* 2014;186(3):219-224. <https://doi.org/10.1055/s-0033-1356222>
 14. Hoffmann B, Nürnberg D, Westergaard MC. Focus on abnormal air: diagnostic ultrasonography for the acute abdomen. *Eur J Emerg Med.* 2012;19(5):284-291. <https://doi.org/10.1097/MEJ.0b013e3283543cd3>
 15. Buttar S, Cooper D Jr, Olivieri P, et al. Air and its Sonographic Appearance: Understanding the Artifacts. *J Emerg Med.* 2017;53(2):241-247. <https://doi.org/10.1016/j.jemermed.2017.01.054>
 16. Jones R. Recognition of pneumoperitoneum using bedside ultrasound in critically ill patients presenting with acute abdominal pain. *Am J Emerg Med.* 2007;25(7):838-841. <https://doi.org/10.1016/j.ajem.2007.02.004>
 17. Coppolino F, Gatta G, Di Grezia G, et al. Gastrointestinal perforation: ultrasonographic diagnosis. *Crit Ultrasound J.* 2013;5 Suppl 1(Suppl 1):S4. <https://doi.org/10.1186/2036-7902-5-S1-S4>
 18. Karahan OI, Kurt A, Yikilmaz A, Kahriman G. New method for the detection of intraperitoneal free air by sonography: scissors maneuver. *J Clin Ultrasound.* 2004;32(8):381-385. <https://doi.org/10.1002/jcu.20055>