

The Outcomes of Open Reduction and Internal Fixation of Clavicular Fracture

Hani A. Abduljawad¹, Mohamed M. ElZohairy^{2*}, Yousef M. Kherah³, Khalid M. Hasan⁴

¹Visiting Resident, Orthopaedic Department, Faculty of Medicine, Zagazig University, Egypt.

²Assistant Professor, Orthopaedic Department, Faculty of Medicine, Zagazig University, Egypt.

³Professor, Orthopaedic Department, Faculty of Medicine, Zagazig University, Egypt.

⁴Head And Professor, Orthopaedic Department, Faculty of Medicine, Zagazig University, Egypt.
elzohairy.me@gmail.com

***Corresponding Author:** Dr. Mohamed Mansour Elzohairy, Department of Orthopaedic Surgery, Faculty of Medicine, 4 Zeid Ben Sabet Street, University Villas, Ash Sharqia Governorate, Zagazig City, Egypt.

Abstract

Clavicle fractures are common, surgical treatment of displaced clavicle fractures is controversial. We present our experience with 24 patients over a 2 years period. twenty-four patients underwent open reduction and internal fixation (ORIF) of displaced clavicle fractures, Modern plate fixation was used in all cases. The result for all patients went on to complete union at an average of 10.37 weeks after surgery. The union rate was 91%. No major complications were identified. In conclusion ORIF of displaced clavicle fractures is a reliable treatment with predictable outcomes when fundamentals of fracture fixation and soft tissue technique are followed.

Keywords: Clavicle; Fracture; Surgery; floating shoulder; ORIF

INTRODUCTION

The clavicle fractures are common, which account about 2.6 % of all fractures and nearly 44 % of those in the shoulder girdle. Fractures of the middle third of the clavicle are most common (81%) [1]. Surgical operation for displaced clavicle fractures is controversial. Traditionally, these fractures have been treated non-operative ways [2,3]. This traditional treatment is not without complications, such as shortening, nonunion, deformity and un satisfactory

patient outcomes [4,5]. At recent days, operative treatment has proven superior results [6,7].

A classification suggested by Robinson presented three main types of clavicle fracture: Type I: medial 1/5th clavicle fracture; Type II: middle 3/5th clavicle fracture; Type III: lateral 1/5th clavicle fracture, every type classified into (a) Undisplaced and (b) displaced, also another subtypes (a1) (b1) extra-articular and (a2) (b2) intra-articular (Fig. 1). Internal fixation with plate and screws for clavicular fracture is an accepted method in most cases with fracture displacement [8].

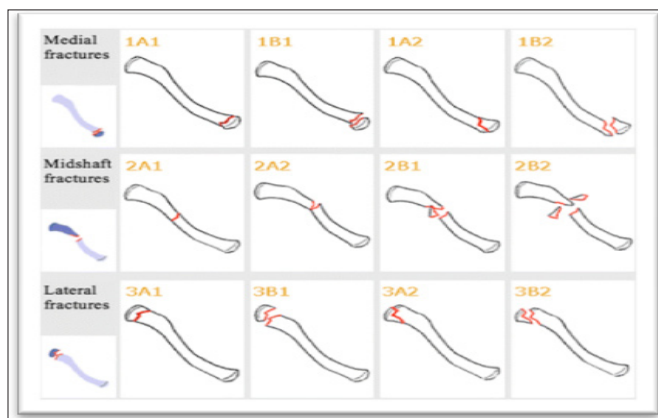


Fig 1: Robinson Classification of clavicle fractures. [8]

The Outcomes of Open Reduction and Internal Fixation of Clavicular Fracture

MATERIALS AND METHODS

The aim of this prospective study was to evaluate the functional results of surgical treatment of clavicular fracture. Twenty four patients' eighteen males and six females with mean age of 32.125 years (17-53 years) were treated for clavicle injury in Zagazig University Hospitals in the period from January 2016 to March 2018 using open reduction and internal fixation of the clavicle in all patients. The right clavicle was affected in 13 patients and the left shoulder injured in 11. The cause of injury was traffic accidents in 12 patients,

falling from height in 10 patients and direct trauma in two cases. They were 20 cases mid shaft fracture and 4 cases distal clavicular fracture. Regarding associated injuries at time of trauma; 10 of them were floating shoulder which combination fracture (clavicle fracture and scapular neck fracture), one of them floating shoulder plus ribs fracture, one floating and distal radius fracture, also one of them floating fracture plus proximal humerus fracture, one of them have clavicle fracture and distal radius fracture, and the others were only clavicle fracture. Also no preoperative neurovascular injuries had been detected.

Table 1. The Criteria of Cases in Our Study.

Inclusion criteria	Exclusion criteria
<ul style="list-style-type: none"> • Associated neurovascular injury • Impending skin compromise • Shortening>20mm • Significant comminution • Scapulothoracic dissociation • Floating shoulder • Bilateral upper extremities fracture • Ipsilateral upper extremities fracture • Open fractures 	<ul style="list-style-type: none"> • Nondisplaced Group I. • Elderly, low-demand, high surgical risk patient. • Pediatric distal clavicle fractures (skeletally immature). • Infection over the site of fracture.

The mean period from injury to surgery was 5 days (range, 3-10 days). The method of fixation of the clavicular fracture was open reduction and internal fixation with a reconstruction plate in twenty patients (**Fig 2**), hook plate and T-plate for distal clavicle fracture. Intraoperative radiology and stress test were done in all patients to ensure the stability of both fractures after fixation of the clavicle.

good stability with internal fixation of clavicle alone, and 4 cases needed to scapular fixation to get shoulder stability.

In 10 cases which floating shoulder, 6 of them has

the shoulder was immobilized in an arm to chest bandage for 3 weeks; followed by pendulum exercises in a sling. Six weeks after surgery, the sling was removed and patients started range-of-motion (ROM) exercises. Clinically the patients were evaluated with the constant shoulder score [9].

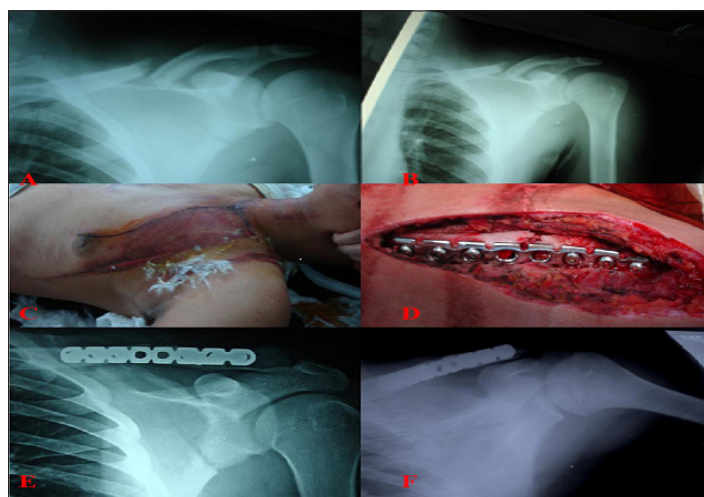


Fig 2: Male Patient 38 Years Old with Floating Shoulder Injury: A&B) Preoperative X-Ray; C) Photo Shows the Clinical Appearance of the Patient Preoperative; D) Intraoperative Photo Shows Fracture Clavicle After Open Reduction and Internal Fixation; E) X-Ray 1month Postoperative; F) X-Ray 15 Months Postoperative with Both Fractures United.

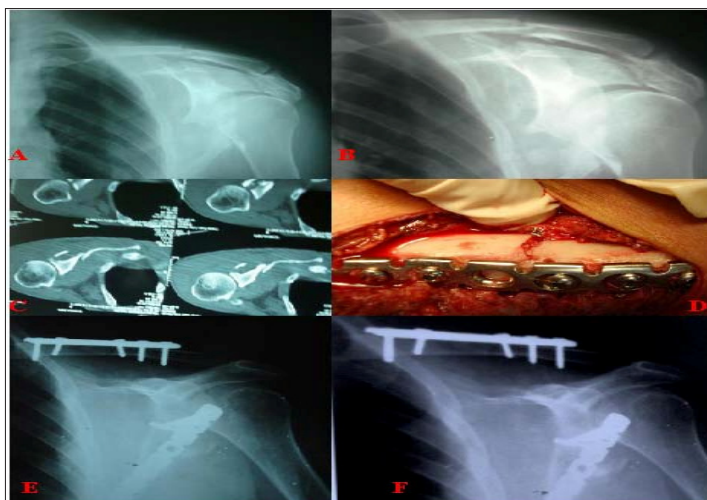


Fig 3: Male Patient 42 Years Old With Floating Shoulder Injury: A&B) Preoperative X-Ray Showing Fracture Clavicle with Displaced Fracture Scapula; C) C-T Scan for the Scapular Fracture with Displacement; D) Intraoperative Photo with Plate Fixation; E) Immediate Postoperative X-Ray Showing Internal Fixation of Clavicle And Scapula ; F) X-Ray 1 Year Postoperative With United Both Fractures in Good Position.

RESULTS

The mean follow up period was 27 months (from 24 to 31). Postoperative monthly visits till three months followed by regular visits every three months. Clinically we used Constant shoulder score system for evaluation of all patients. The Grading of scores as follow: >90 Excellent 80-90 Good 70-80 Fair <70 Poor.

Excellent / good indicates satisfactory results, where as fair / poor indicates unsatisfactory results.

Radiographic bony union was obtained in 22 patients, and other two patients were non-union. The mean time to union was 10.73 weeks.

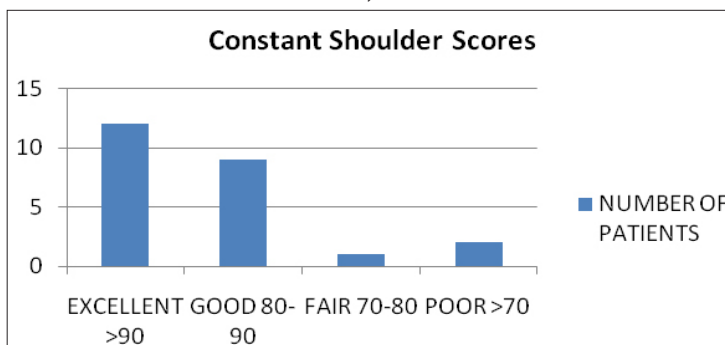
In all 24 cases the average operative time were 120 minutes, and no iatrogenic complication during surgery. The average stay in hospital after operation was 4.83 days. Also most of cases 83.3% were returned to work within 3 months.

Table 2. Clinical Results of 24 cases in our study.

Union rate (%)	91 (n=22)
Mean shoulder score (points)	91.86 (n=24)
Mean union time (weeks)	10.73
Return to work in 3 months %	83.3 (n=20)
Symptomatic hard ware (%)	8.3 (n=2)

At the end of follow up, the mean constant shoulder score was 91.86, which 12 cases were > 90 **Excellent** score, 9 cases was between 80-90 which **Good** score,

one case from 70 to 80 which **fair** score and two cases less than 70 which **poor** outcome and those patients were non-union outcome. As seen in column graph.

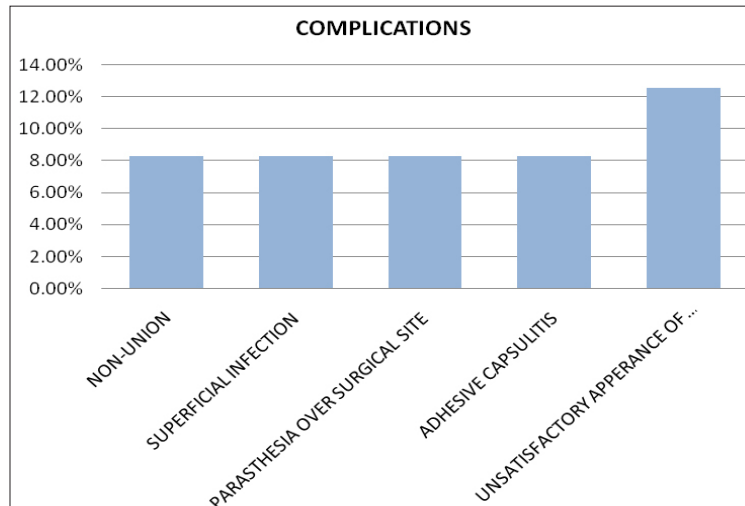


Graph 1. Column Graph Shows The Mean Constant Shoulder Scores of Patients.

The Outcomes of Open Reduction and Internal Fixation of Clavicular Fracture

The complications were two cases non-union these cases complain from diabetes, a second operation (plate fixation and bone graft) was planned to this patients, two cases were superficial infection, which discovered 7-10 days postoperative, and resolved by one week oral antibiotic, two cases complain of paresthesia over surgical site, this complication due to horizontal surgical

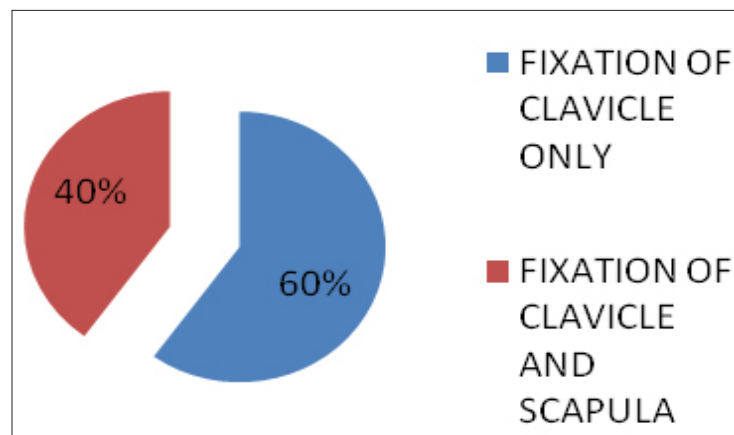
incision, which were relieved by topical analgesic (Diclofenac sodium gel/ 8 hours for two weeks). Also two cases complain of adhesive capsulitis one of them was diabetic, which managed with (corticosteroid injection and physiotherapy). And finally three of them were unsatisfactory appearance of scar, which were younger female. As shown in column graph.



Graph 2. Column Graph Shows Percentage of Complications in Open Reduction Internal Fixation of Clavicular Fracture.

In 10 cases which floating shoulder, 6 of them has good stability with internal fixation of clavicle alone,

and 4 cases needed to scapular fixation to get shoulder stability. As shown in the chart.



Graph 3. The Percentage of Internal Clavicle Stability Alone in Floating Shoulder.

DISCUSSION

The clavicle fractures are common, because of their subcutaneous position, accounting for 2.6% of all fractures, more than 75% located in the mid shaft, after that coming lateral fractures, then rarely medial clavicle fractures [10].

Many conservative treatment ways have been described, but the most common are simple arm sling or figures of eight bandage have been widely used [11].

The arm sling use in the clavicle fractures, demonstrated better patient satisfaction. Moreover, figure of eight bandage which associated with higher complications, the some of these complications was axillary pressure sore, and neurovascular compression [12].

The many of old studies have shown high level of patient satisfaction about their healing after non operative treatment of the clavicle fractures, and even surgical operation had higher rates of nonunion [13,14,15].

The Outcomes of Open Reduction and Internal Fixation of Clavicular Fracture

However; the many of recent studies have demonstrated higher rate of complications after non operative treatment, such as non-union, and poor functional outcome, while the results of operative treatment such as open reduction and internal fixation by plate as primary decision, have improved considerably [16,17,18,19].

The numerous of muscular and ligamentous forces, act on the clavicle, such as deforming force of sternocleidomastoid after fracture, is very strong and cannot be overcome by external supports such as sling arm or figure eight bandage.[20]

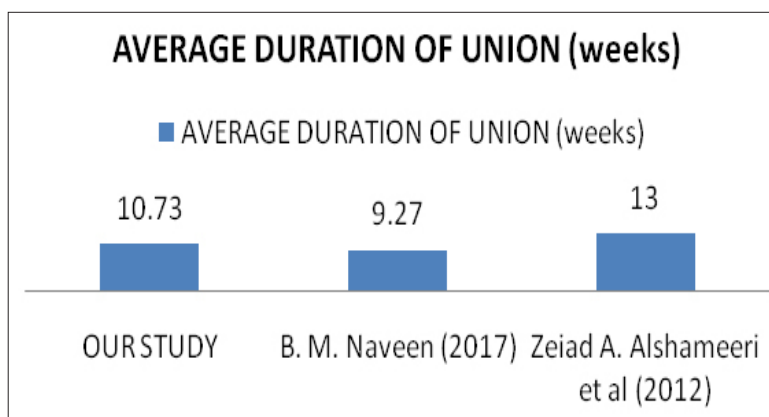
There are many types of fixation in clavicle fractures, in this current study 4 types of implants were performed, reconstruction plate 3.5 mm, locked compression plate 3.5mm, hook plate, and T-plate, 20,1,3,1, respectively, which first two implants used in mid shaft fracture, and last two in distal clavicle fracture.

Overall, the results of this study suggest, the open reduction and internal fixation of clavicle fracture, was satisfied, which the union rate in our study, was 91 %, which is comparable to that in **Naveen et al (2017)** [21], which here union rate was 100%, in study of management of midshaft clavicle, its comparative study between operative and non-operative, consisting 60 patients, used the plate (DCP 3.5mm). While another study taking about management of distal clavicle fracture, **Sylvia A Stegeman et al (2013)** [22], its union rate was (98%), hook plate or medullary nail fixation used in this study.

In our study there was ten cases have floating shoulder, which a clavicle fracture plus scapular neck fracture as associated injury, (60%) of them have good stability with clavicle fixation alone, and (40%) of cases needed scapula fixation after fixation of clavicle, to achieve shoulder stability, and our results its comparable with, **Yousuf M Khiraet al** [23], Where its results were, (66.7%) of their cases have stable shoulder after fixation of clavicle alone, in study includes 12 patient , under the title of Treatment of Floating Shoulder: Is Internal Fixation of The Clavicle enough?.

We followed up the patients by using constant shoulder score. The mean score was (91.86) after 6 months. However in other study, **Chang-Hong Chen et al (2014)** [24], its results were 78 ± 6 points at 8 to 12 months. In these study 33 patients, stabilized by hook plate, in another study **B. M. Naveen (2017)** [21], whereas the mean score after 6 months follow up was (94).

The average duration required for union in our study was 10.73 weeks, as compared to **B. M. Naveen (2017)**[21], where the result in surgical group was 9.27 weeks. In another study of **Zeiad A. Alshameeri et al (2012)**[25], under title of the outcome of surgical fixation of mid shaft clavicle fractures, the union was achieved in all patients after an average of 13 weeks. Column chart below shows the comparison of union time.



Graph 4. The Average Union Time in Our Study And Previous Study.

Regarding complications in our study, we have non-union rate (8.3%). The results it's comparable with, **Verborgt et al (2005)** [26]. And superficial infection in two cases represents (8.3%), while **Verborgt et**

al, were 4 cases represent (10%). And also we notify stiffness shoulder in two cases (8.3%). We have no evidence of deep infection, Implant breakage/failure, and Neurovascular problems.

CONCLUSION

In conclusion, the conservative treatment remains the treatment of choice for simple clavicle fractures, but for displaced and comminuted fractures surgical intervention is appropriate, especially when considering the overall outcome results. Our study included a small cohort of patients and suggests that the Plate fixation of displaced midshaft or distal clavicle fracture reliably restores length and alignment. It resulted in shorter time to union with low complication rates.

For floating shoulder injury, it is important to determine the severity of fracture displacement accurately and the presence or absence of coracoclavicular ligament disruption. On the basis of those factors, internal fixation of the clavicle alone is satisfactory for stable fractures of scapula and simple clavicular fracture. Internal fixation of scapular fracture indicated when fixing the clavicle and shoulder still unstable.

REFERENCES

- [1] Postacchini F, Gumina S, De Santis P, Albo F, "Epidemiology of clavicle fractures," *J Shoulder Elbow Surg*, 11: 452-426, 2002.
- [2] Kashif Khan LA, Bradnock TJ, Scott C, Robinson CM, "Fractures of the clavicle. Current concepts review," *J Bone Joint Surg Am*, 91: 447- 460, 2009.
- [3] Stanley D, Trowbridge EA, Norris SH, "The mechanism of clavicular fracture. A clinical and biomechanical analysis," *J Bone Joint Surg Br*, 70 (3): 461-4, 1988.
- [4] Chen C, Chen J, Wang C, Tien Y, Chang J, et al, "Semi tubular Plates for Acutely Displaced Midclavicular Fractures: A Retrospective Study of 111 Patients Followed for 2.5 to 6 Years," *J Orthop Trauma*, 22 (7): 463-466, 2008.
- [5] Smekal V, Irenberger A, Struve P, Wambacher M, Krappinger D, et al, "Elastic stable intra medullary nailing versus non operative treatment of displaced midshaft clavicular fractures-a randomized, controlled," clinical trial. *J Orthop Trauma*, 23 (2): 106-112, 2009.
- [6] Canadian Orthopedic Trauma Society, "Non operative treatment compared with plate fixation of displaced midshaft clavicle fractures. A multi center, randomized clinical trial," *J Bone Joint Surg Am*, 89 (1): 1-10, 2007.
- [7] Xu J, Xu L, Xu W, Gu Y, Xu J, "Operative versus non operative treatment in the management of midshaft clavicular fractures: a meta-analysis of randomized controlled trials," *Journal of Shoulder and Elbow Surgery*, 23 (2): 173-181, 2014.
- [8] Robinson CM, "Fractures of the clavicle in the adult Epidemiology and complication," *J Bone Joint Surg Br*, 80 (3): 476-84, 1998.
- [9] Constant CR, Murley AH, "A clinical method of functional assessment of the shoulder," *ClinOrthopRelat Res*, (214): 160-4, 1987.
- [10] Crenshaw AH, "Fractures of the shoulder girdle arm and forearm. In: Crenshaw AH," editor. *Campbell's operative orthopaedics*. 8th ed. St.Louis: Mosby Year book, p 989-1053, 1992.
- [11] Lester CW, "The treatment of fractures of the clavicle. *Ann Surg*; 89: 600-6, 1929.
- [12] Andersen K, Jensen PO, Lauritzen J, "Treatment of clavicular fractures. Figure-of-eight bandage versus a simple sling," *Acta OrthopScand*, 58: 71-4, 1987
- [13] Rowe CR, "An atlas of anatomy and treatment of midclavicular fractures," *ClinOrthopRelat Res*, 58: 29-42, 1968.
- [14] Neer CS 2nd, "Nonunion of the clavicle," *J Am Med Assoc*, 172: 1006- 11, 1960.
- [15] Nordqvist A, Petersson CJ, Redlund-Johnell I, "Mid-clavicle fractures in adults: end result study after conservative treatment," *J Orthop Trauma*, 12: 572-6, 1998.
- [16] McKee MD, Pedersen EM, Jones C, Stephen DJ, Kreder HJ, Schemitsch EH, Wild LM, Potter J, "Deficits following nonoperative treatment of displaced midshaft clavicular fractures," *J Bone Joint Surg Am*, 88:35-40, 2006.
- [17] Canadian Orthopaedic Trauma Society, "Non operative treatment compared with plate fixation of displaced midshaft clavicular fractures. A multicenter, randomized clinical trial," *J Bone Joint Surg Am*, 89: 1-10, 2007.
- [18] Wun-JerShen, Tsung-Jen Liu, Young-Shung Shen, "Plate fixation of fresh displaced midshaft clavicle fractures," *Injury*, 30: 497-500, 1999.
- [19] Xin-Hua Wang, Wei-Jun Guo, A-Bing Li, Guang-Jun Cheng, Tao Lei, and You-Ming Zhao, "Operative versus nonoperative treatment for displaced midshaft clavicle fractures: a meta-analysis

The Outcomes of Open Reduction and Internal Fixation of Clavicular Fracture

- based on current evidence," Clinics (Sao Paulo), 70 (8): 584–592, 2015.
- [20] Poigenfurst J, Rappold G, Fischer W, "Plating of fresh clavicular fractures: results of 122 operations," Injury, 23 (4): 237-41, 1992.
- [21] B. M. Naveen, G. R. Joshi, and B. Harikrishnan, "Management of mid-shaft clavicular fractures: comparison between non-operative treatment and plate fixation in 60 patients," Strategies Trauma Limb Reconstr, 12 (1): 11–18, 2017.
- [22] Sylvia A Stegeman, Hakan Nacak, Koen HJ Huvenaars, Theo Stijnen, Pieta Krijnen & Inger B Schipper, "Surgical treatment of Neer type-II fractures of the distal clavicle," Acta Orthopaedica, Vol. 84, Iss. 2, 2013.
- [23] Adel M Salama; and Yousuf M Khira, "Treatment of Floating Shoulder: Is Internal Fixation of The Clavicle enough?," The Egyptian Orthopaedic Journal, Vol. 47, No. 1, 2012.
- [24] Chang-Hong Chen, Qi-Rong Dong, Rong-Kui Zhou, Hua-Qing Zhen, and Ya-Jun Jiao, "Effects of hook plate on shoulder function after treatment of acromioclavicular joint dislocation," Int J Clin Exp Med, 7 (9): 2564–2570, 2014.
- [25] Zeiad A. Alshameeri, Krishnaiah Katam, Mohammed Alsamaq, and Paresheh Sonsale, "The outcome of surgical fixation of mid shaft clavicle fractures; looking at patient satisfaction and comparing surgical approaches," Int J Shoulder Surg, 6 (3): 76–81, 2012.
- [26] Verborgt O, Pittoors K, Glabbeek F, Declercq G, Nuyts R, Somville J, "Plate fixation of middle-third fractures of the clavicle in the semi-professional athlete," Acta Orthop Belg, 71 (1): 17, 2005.

Citation: Hani A. Abduljawad, Mohamed M. ElZohairy, Yousef M. Kherah, Khalid M. Hasan. *The Outcomes of Open Reduction and Internal Fixation of Clavicular Fracture. Archives of Orthopedics and Rheumatology. 2018; 1(2): 42-48.*

Copyright: © 2018 Hani A. Abduljawad, Mohamed M. ElZohairy, Yousef M. Kherah, Khalid M. Hasan. *This is an open access article distributed under the Creative Commons Attribution License, which permits unrestricted use, distribution, and reproduction in any medium, provided the original work is properly cited.*