

Minimally Invasive Spine Osteosynthesis (MISO) Technique Versus Traditional and Paraspinal Posterior Open Approaches for Treatment of Thoracolumbar Spine Fractures

Bahaa Ali kornah*, Hesham Mohamed safwat , Mohamed abdelaziz, Mohamed Ibrahim abuelesoud, Tharwat Abdel ghany, Nagy saleem, Mohamed Abdel-AAI

Consultant Orthopedic Surgeon, Orthopedic Department, Al Azhar University Cairo Egypt.

bkornah@yahoo.co.uk

***Corresponding Author:** Bahaa Kornah, Consultant Orthopedic Surgeon – Al-Azhar University. Cairo Egypt Clinic: 90 D Ahmed Orabi St. Mohandessin, Giza, Egypt.

Abstract

The treatment of fractures of the thoracic lumbar spine remains controversial. Single-segment fractures without neurologic injury treated by pedicle screw fixation posterior short-segment (PS), surgical technique can be either through posterior midline incision or paraspinal posterior open approaches or Percutaneous

The goal of this study is to evaluate the effectiveness of minimally invasive treatment of dorso-lumbar fractures by mini open surgical pedicle screw fixation.

This study involves Patients of acute traumatic single level dorsolumbar spine fractures requiring surgical intervention were included in this study. Twenty eight patients (20 male, 8 female), age range 17-47 years (mean 30.1 ± 7.9 yrs) with dorso-lumbar fractures (D12:8, L1:13, L2:4, L3:3) with TLICS score >4 were studied (Feb 2009-Feb 17). Total of 112 screws were put of which 3 screws were mal positioned (2.6%). Open conversion was done in two cases (7.1%) due to difficulty in screw positioning. In one case, screw pull out was noted intra operatively during ligamentotaxis and rod manipulation.

Results: No patient had post-operative neurological deterioration. Mean post-operative hospital stay was 3.1 days. The average blood loss is 94 ml. Follow-up scans showed satisfactory correction of deformity. Good to excellent outcome was present in 92, 8%.

Conclusion: We conclude that mini open surgery for pedicle screws fixation is a safe, reliable, cost effective technique with favorable results in acute polytrauma cases requiring standalone ligamentotaxis. Complex biomechanics/physics of instrumentation, lack of adequate fusion and steep learning curve during initial cases with increased radiation exposure limits its application in all cases.

Keywords: spine fixation, minimal spine fixation, pedicular screw fixation, Fr. Spine

INTRODUCTION

Spine fractures are serious injuries. The goals of the treatment of thoracolumbar fractures, , are the restoration of the stability of the vertebral column and the decompression of the spinal canal, leading to earlier mobilization of the patient. It is widely accepted that thoracolumbar burst fractures should be addressed surgically.^[1]

The use of pedicle screws for spinal stabilization has become increasingly popular worldwide. Pedicle screw systems engage all three columns of the spine and can resist motion in all planes. Several studies suggest that pedicle screw fixation is a safe and effective treatment for many spinal disorders.^[2,3]

Short-segment pedicle fixation (SS) is a popular option. Dick et al.; have developed the SS stabilization

Minimally Invasive Spine Osteosynthesis (MISO) Technique Versus Traditional and Paraspinal Posterior Open Approaches for Treatment of Thoracolumbar Spine Fractures

for the operative treatment of thoracolumbar and lumbar fractures. However, there is a controversy as far as the results of this instrumentation are concerned.^[4]

The choice of treatment option in the absence of a neurological deficit depends on the Thoracolumbar Injury Classification and Severity Score (TLICS) scores (4&5)

This classification not only highlights the fact that axial load transmission travels through the vertebral bodies and Intervertebral discs, it is also a scoring points system that can be used preoperatively to: Predict screw breakage when short segment, posteriorly placed pedicle screw implants are being used and Select fractures needing further anterior reconstruction. Those fractures with a combined score of 6 or less are suitable for short-segment posterior spinal instrumentation, while those with a 7 or higher require either long-segment fixation or circumferential fusion. For insertion of pedicular screws by Standard techniques for pedicle screw fixation which involve open exposures and extensive muscle dissection [5, 6]. Percutaneous pedicle screw fixation is will accept technique, but it needs specialized equipments and long learning curve before implementation [7]. One of the disadvantages of Percutaneous is high incidence of screw apposition [8], [9] and large doses of radiation exposure [10], [11] have caused a sluggish evolution also the cost.

By applying MINIMALLY INVASIVE SPINE OSTEOSYNTHESIS (MISO) TECHNIQUE, no need to use a modified screws or special screws set with extension sleeve that would allow for remote manipulation of the polyaxial screw heads and remote engagement of the screw locking mechanism and unique rod insertion device.

The purpose of this paper is to describe a minimal invasive posterior fixation of the thoracolumbar and lumbar spine technique using ordinary pedicular screws and instrumentation.

PATIENT AND METHOD

The present prospective study was conducted at El Hussein university Hospital and Bab El Shaaria AL -Azhar University from 2009-2017. This prospective study included 28 patients with Fractures spine between 2009 and 2017. This study included 28

patients with Fractures spine between 2009 and 2017. Fall from height /staircase was the most common mode of injury in 18 patients followed by road traffic accident in 9 and in one case drop of heavy box over the back while working.

There were 20 males and 8 females. Age of patients ranges from 17 to 47 years (mean 30.1 ± 7.9 yrs). The study included 13 patient with fracture Spine lumbar 1 and 8 patient dorsal 12 fractures and 4 patient with L2 fractures and 3 patient L3 fractures. All cases underwent FOR MINIMALLY INVSIVE SPINE FIXATION.

The inclusion criteria using Thoracolumbar Injury Classification System (TLICS). The load sharing classification for burst fractures met these criteria. The study including 28 fractures with a combined score of 6 or less was selected as they are suitable for short-segment posterior spinal instrumentation, also not need for decompression while those with a 7 or higher which need decompression of medullary canal were excluded.

PATIENT SELECTION CRITERIA

Patients without neurological deficit, with TLICS score of 6 or less, not need a decompression of the neural elements with a mechanically unstable burst fracture, reduce displaced bony fragments by ligamentotaxis within 48-72 hours after injury.

The follow up period ranged from 6 to 18 months postoperative with an average of 10 months.

TECHNIQUE

Preoperative Management

The patient was placed on a firm mattress.

Catheterization, under aseptic conditions was used in patients with incontinence or retention.

Parenteral or oral analgesics were administrated before surgery and continued for about 2 days postoperatively.

Operative Procedure

Anesthesia was given to the patient while lying supine beside the operating table. Hypotensive anesthesia was used to decrease the blood loss intraoperatively, and to facilitate homeostasis.

Minimally Invasive Spine Osteosynthesis (MISO) Technique Versus Traditional and Paraspinal Posterior Open Approaches for Treatment of Thoracolumbar Spine Fractures

Position of Patient

The patient is positioned onto a radiolucent table prone on two horizontally placed padded bolsters (one at the level of sternum and another one at the level of anterior iliac spine) or a frame.

The abdomen should hang free to avoid increased intraabdominal pressure to prevent excessive bleeding

Adequate padding needs to be provided to elbows and knees to avoid pressure sores

The head is rested either in a horse shoe ring or a Mayfield rest to avoid pressure on the eyes.

Hips and knees were moderately flexed to prevent stretching of the nerve roots. Then, sterilization and draping were done. (Fig, 1)

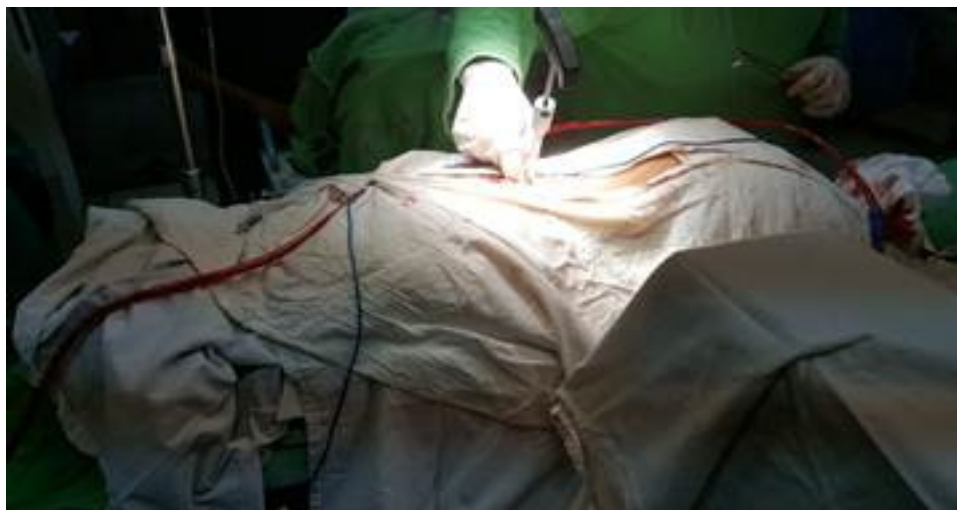

Fig 1. Patient Positioning Similar to Conventional Open Approach with Adequate Padding at Areas of Contact (Elbows And Knees) to Avoid Pressure Sores.

Surgical Approach

Posterior approach was used.

Type of the construct: top loading pedicle screws system.

Incision: two small a posterior midline incision at the target segment at the level of target pedicles determined by C-arm. The length of the incision is about 2 cm, one level above and below the fractured vertebra is exposed. (FIG. 2).

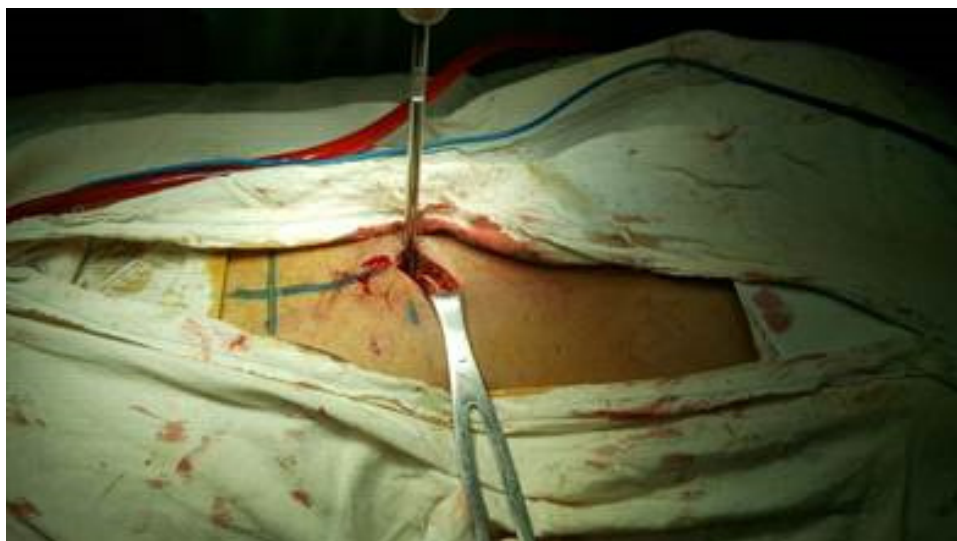

Fig 2. One Level Above and below the Fractured Vertebra was Incised and the Length of the Incision was About 2 Cm.

Minimally Invasive Spine Osteosynthesis (MISO) Technique Versus Traditional and Paraspinal Posterior Open Approaches for Treatment of Thoracolumbar Spine Fractures

The standard posterior approach to the lumbar spine is made through the incision (the paraspinal muscle along the Spinous process and the vertebral lamina. Then, the facet joints and roots of the transverse process were exposed). The thoracolumbar fascia is incised lateral to the supraspinatous ligament, and the paraspinal muscles were stripped subperiosteally along the sides of the Spinous processes, laminae, and

facet joints with a Cobb elevator and a gauze swab in both sides from the same incision with skin retraction. To expose the transverse processes, the dissection continues down the lateral side of the superior facet and onto the transverse process with homeostasis in this area. (7) During exposure, care is taken not to injure the facet joint capsule if a non fusion technique is planned. With the help of mini-retractor (Fig.3),



Fig.3. Mini-Retractor

The entry point is now clearly exposed. The screw side Trajectory is identified and the screw insertion using free hand technique with C arm control under direct vision using AO technique

After application of the 4 screws (fig.4), a contour rod is pass (fig.5) sub muscular position with minimal manipulation, essentially no muscle dissection, and without the need for direct visual feedback

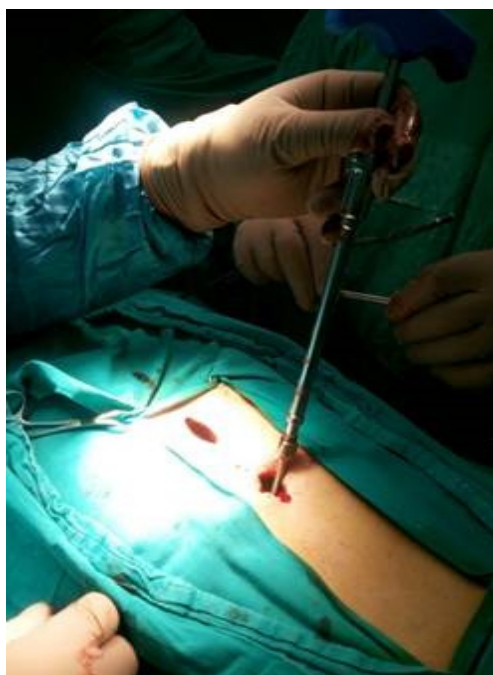


Fig 4. Insertion of the 4 Pedicular Screws

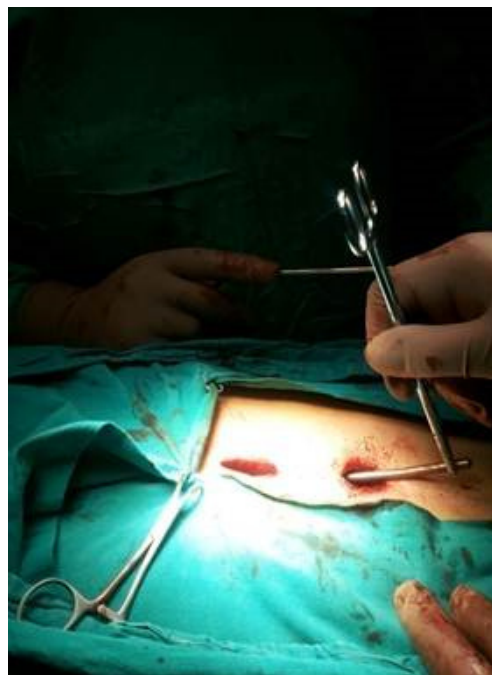

Fig 5. A Contour Rod is Pass Submuscular

Minimally Invasive Spine Osteosynthesis (MISO) Technique Versus Traditional and Paraspinal Posterior Open Approaches for Treatment of Thoracolumbar Spine Fractures

Reduction And Indirect Decompression

Usually partial spontaneous reduction was achieved when the patient was turned to the prone position on a special frame that restored the normal dorsal kyphotic and lumbar lordotic curves of the spine. The reduction was checked by the image intensifier.

Reduction and indirect decompression was done as follows:

- Correction of Kyphosis and recreation of normal lordosis were done by contouring the rod. Correction was achieved using the principle of

3 points fixation. The cephalic and caudal ends of the rods constitute 2 points of fixation and the third was the apex of the deformity that was ventrally displaced by tightening of the anchors. Pedicle screw fixation secured all 3 columns and provided excellent fixation.

- Application of distraction by distractor and distraction was done until correction of vertebral height if possible guided by C arm control .The correction maintained by tightening screws head nuts (fig 6&7)

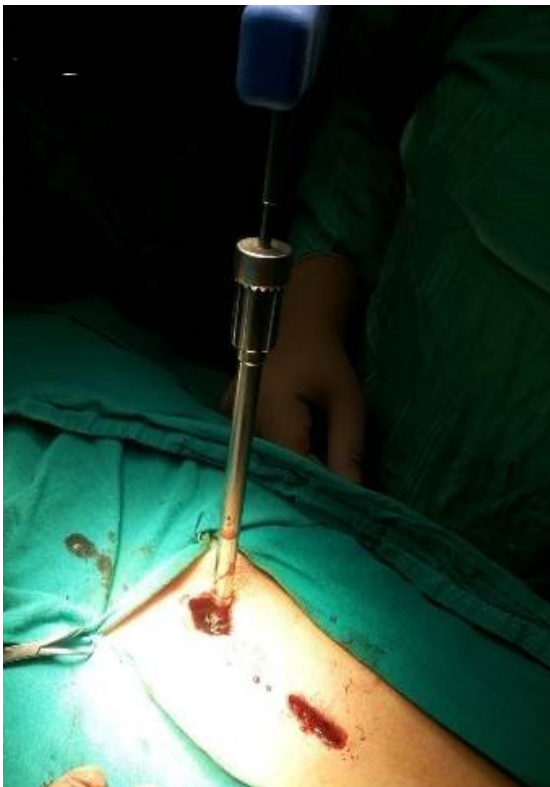

Fig 6. Application of the Nut

The wound are then closed in layers: muscles, fascia, subcutaneous layer and skin using absorbable sutures. In most of cases did no need for drain

Postoperative Care:

All patients were neurologically tested before leaving the operating room.

Patients were kept flat for a period of 24 hours after surgery with close observation to vital signs and

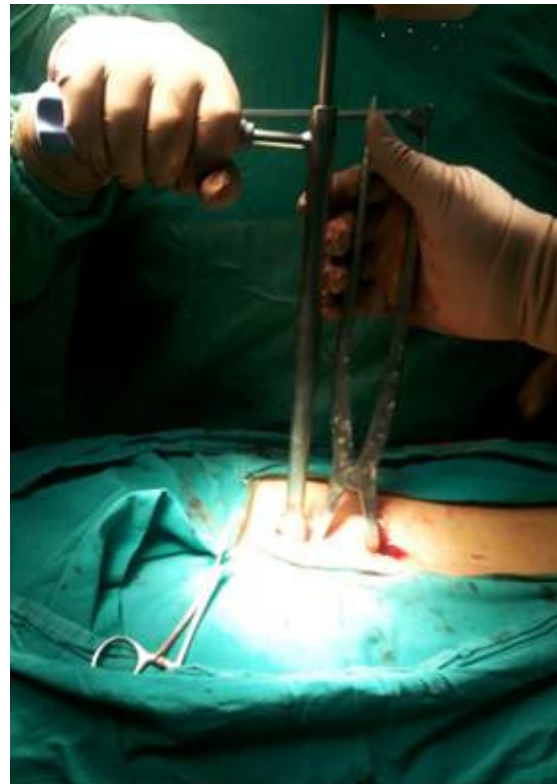


Fig 7. Indirect Reduction by Distraction

drain if applied .Post-operative antibiotics were continued for 2 days.

Post-operativeX- ray and multi slice CT scans were performed and then repeated after 6 months and may be repeated again till assurance of bone healing.

Routine clinical and check up was done every month postoperatively for first three months, then every three months afterwards (Fig 8).

Minimally Invasive Spine Osteosynthesis (MISO) Technique Versus Traditional and Paraspinal Posterior Open Approaches for Treatment of Thoracolumbar Spine Fractures

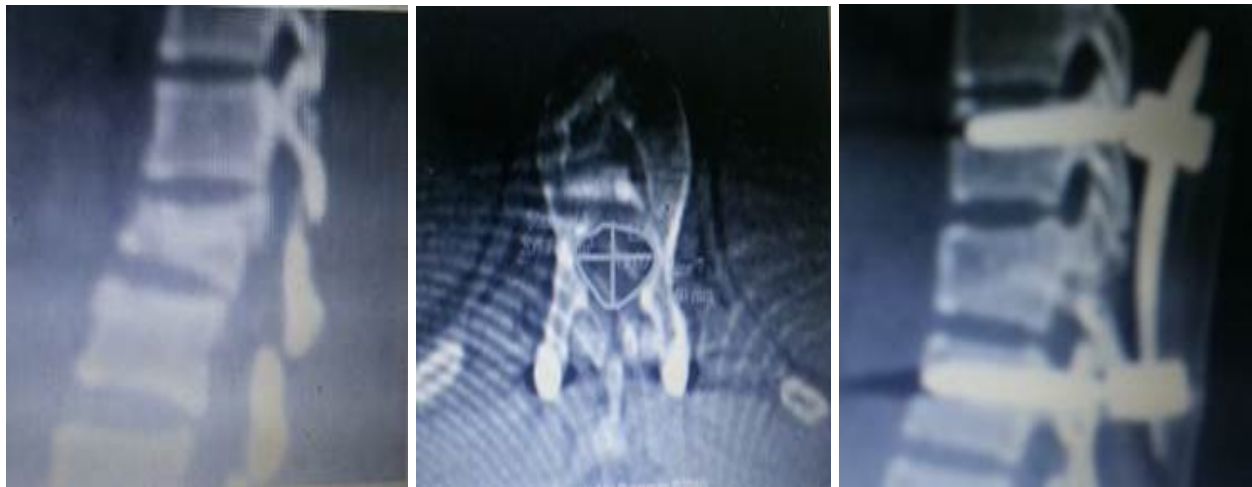

Fig 8. (A) Preoperative Kyphosis Evaluation by Ct & (B) Post Operative Ct Diameter of Spinal Canal, (C) Post Operative Kyphosis Evaluation

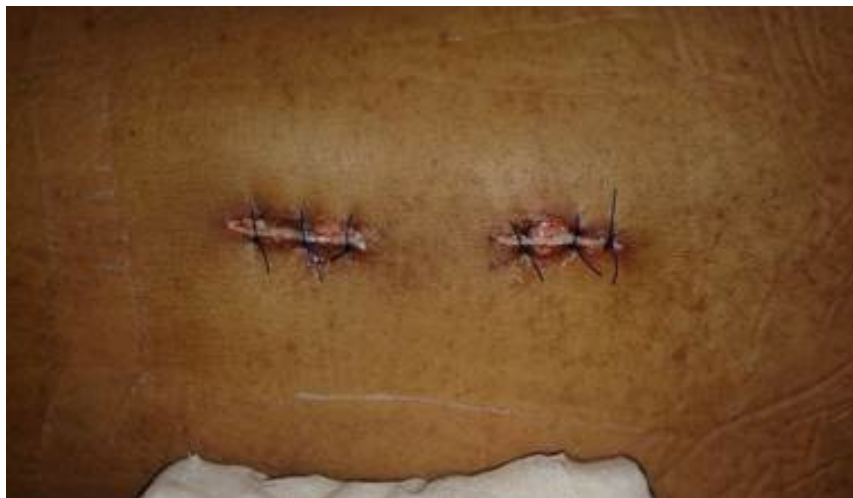

Fig 9. Sutures at the End of Surgery

The study parameters included operative time, blood loss, postoperative drainage, postoperative hospital stays, X-ray exposure time, kyphotic angle, visual analog scale (VAS) scores, postoperative complications, and accuracy rate of screws and cosmetic appearance ((Fig 9). Clinical outcome was classified according to modified Mac nab criteria (9)

RESULTS

All operations were performed using MISO technique apart from two cases. The operative

Operative time (minutes) 65.0 ± 23.2

With the longer operative times occurring early in the learning curve. The average blood loss is 94ml ranged from 70 ml to 100.

Fluoroscopy time (seconds) 5.2 ± 2.1

12 cases with postoperative drainage, the Postoperative drainage (mL) 51.9 ± 37.3

All of the patients were discharged on postoperative Day 1 or 2 apart from 5 patients were discharged on postoperative Day 5 and 7 days due to associated injuries with mean Postoperative hospital stay (days) 3.1 ± 1.8 days.

The follow-up period ranged from 6 to 18 months postoperative with an average of 10 months.

All patients improved clinically, and outcome was classified using the modified Mac nab criteria (Table 1). Total of 112 screws were applied of which 3 screws

Minimally Invasive Spine Osteosynthesis (MISO) Technique Versus Traditional and Paraspinal Posterior Open Approaches for Treatment of Thoracolumbar Spine Fractures

were mal positioned (2.6%). The accuracy rate was 97.4%. Open conversion surgery was done in two cases (7.1%). Results were considered excellent in twelve patients, good in fourteen patients, and poor in two patients. (Fig 6) Although these latter two patients fared well clinically, he required reoperation for hardware revision due to mal insertion of three

screws. Of the seventeen patients who had been followed for longer than 6 months, all were judged to have solid union. All the patient were satisfied from cosmetic appearance of the scar

Clinical outcome was classified according to modified Mac nab criteria (12)

Table 1. Modified Mac Nab criteria used to grade overall Clinical outcome after spinal surgery

Excellent	Complete resolution of all symptoms and free of pain; no restriction of mobility; able to return to normal work and activities
Good	Marked reduction of pain with the patient generally satisfied, returning to work or usual daytime activities, and taking analgesics seldom or not at all
Fair	Some improved functional capacity; still handicapped and/or unemployed
Poor	Continued objective symptoms of root involvement; additional operative intervention needed at index level, Irrespective of repeated operations or length of postop.FU.
Worse	Clinical symptoms considered worse than before receiving procedure

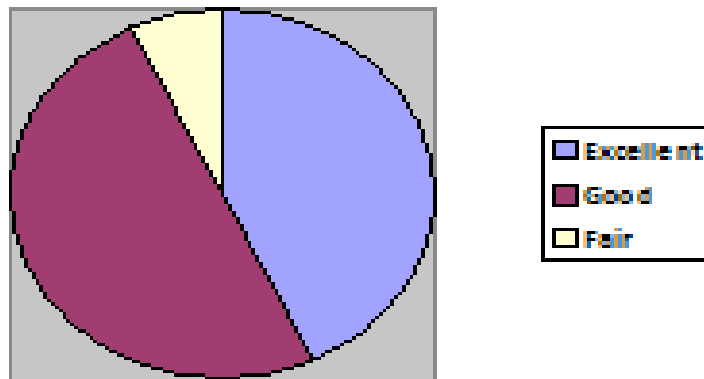


Fig 10. Results

Preoperative pain was high in all patients, with the mean visual analogue scale value of 7.9/10 (range 6-10). It decreased to 2.2 at time of discharge (range 0-7) and to 0.7 at the last follow-up (range 0-2). There were improvements in the vertebral Kyphosis,

vertebral height index and canal area in immediate post operative CT scans which persisted on last follow-up (varying From 6 to 12 months). (Table 2), there were an improvement in the diameter of the canal area comparing preoperative to post operative. (Table 3)

Table 2. Mean Vertebral Height Index (VHI)

LEVEL NUMBER	PRE-OP	POST-OP	FOLLOW - UP
D 12 8 p	58	86	84
L1 13 p	66	89	85
L2 4 p	62	87	85
L3 3 p	75	91	88

L=lumbar- D =dorsal. P= patient

Minimally Invasive Spine Osteosynthesis (MISO) Technique Versus Traditional and Paraspinal Posterior Open Approaches for Treatment of Thoracolumbar Spine Fractures

Table 3. Mean Canal Area in Mm²

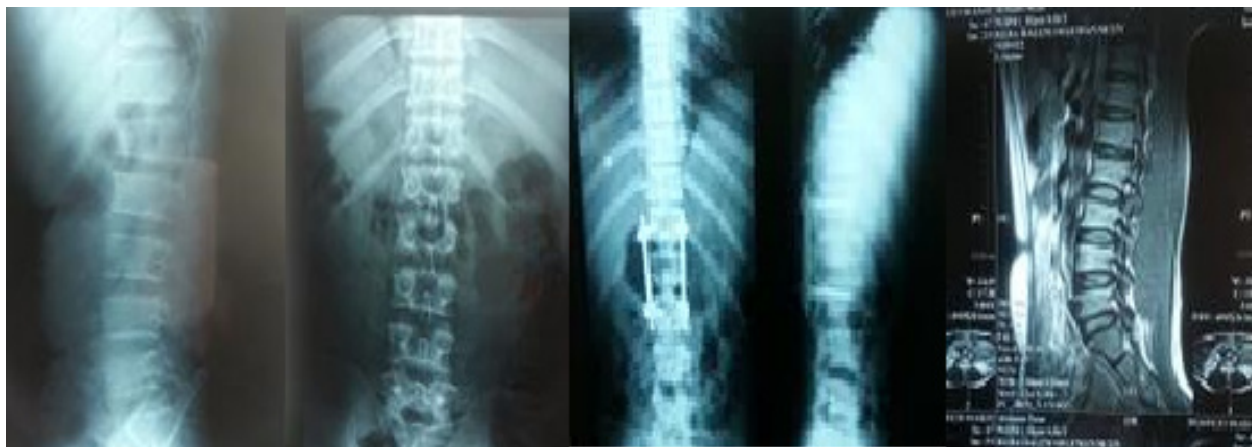Level number	Pre op	Post-op	Last follow up
D 12 8 p	182.34	211.33	207.51
L1 13 p	177.42	207.94	205.30
L2 4 p	168.20	181.73	178.29
L3 3 p	189.3	204.22	202.75

L=lumbar- D =dorsal. P= patient

CASES PRESENTATION

Case male patient 40 years old, fallen from height has L1 fracture

The following are AP. (A) lateral Lat. (B), and post operative AP.& Lat. view (C), View MRI



DISCUSSION

The treatment of traumatic fractures of the thoracic and lumbar spine remains controversial. There is insufficient evidence in the literature to choose between the various surgical options. Five surgical subgroups were recognized: posterior short-segment (PS), posterior long-segment (PL), reports on both posterior short- and long-segment (PSL), anterior (A), and anterior combined with posterior (AP) techniques. (13). Patients with thoracolumbar spine fracture without neurologic deficit should be treated by short-segment posterior stabilization. (14, 15)

Single-segment thoracolumbar fractures without neurologic injury treated by pedicle screw fixation. Posterior short-segment (PS), surgical technique can be either through posterior midline incision or paraspinal posterior open approaches or Percutaneous (16). Wiltse introduce a novel mini-open pedicle screw fixation technique via Wiltse approach (17)

Each method had advantage and disadvantages. It is known that traditional posterior open approaches

to spine surgery lead to increased paraspinal muscle injury following denervation, ischemia secondary to prolonged retraction and detachment of musculotendinous junction. Denervation and ischemia can result from direct injury to dorsal roots and vasculature in extensive surgical exposure, and also occurs due to increased intramuscular edema and resultant focal compartment syndrome secondary to prolonged strong retraction (18)

In 2016 we introduce the novel Minimally Invasive open Spine Osteosynthesis (MISO) Technique. (19) Potential advantages compared with "open" surgery, May result in Smaller incisions and scars, Minimal soft-tissue destruction and scarring, less surgical blood loss, No special instrument or screws, shorter hospital stay, less postoperative pain

Less need for postoperative pain medicine, faster returns to work and daily activities

The procedure involves minimal muscle retraction and minimal stripping of muscles. The pedicles are addressed by usual steps and no needs for specialized instruments.

Minimally Invasive Spine Osteosynthesis (MISO) Technique Versus Traditional and Paraspinal Posterior Open Approaches for Treatment of Thoracolumbar Spine Fractures

The rod is delivered into the screw head deep in the tissue and tightened in place with set screws. This surgery approach allows to be performed with traditional instruments, Radiation Exposure: The amount of radiation that the patient and surgeon are exposed is less than with minimally invasive spine fusion systems than the specific system being used. Incisions: it leaves 2 small scars of approximately less than 2 centimeters, one scar to upper vertebra and one to lower fixed vertebra in the midline. Recovery: from our point the patient leave hospital next day, Operative Time: The amount of surgeon experience is by far the most important factor in operative times rather than the specific spine fusion surgery system used. In general, posterior in general most of surgeon can do it as they trained in Posterolateral fusions.

The need of blood transfusion is decreased and none of our patients required it.

Surgeon learning curve: Pedicle targeting is all spinal surgeons are family with it, so a steep learning curve for the surgeon to build the necessary skills and experience are minimal.

Multi-level spine fusions: it allows multilevel fusions, but the ability to place pedicle screws at each pedicle when performing a two level fusion (known as segmental instrumentation, which may aid in long-term stability) is possible.

Compared to the traditional open spine surgery, minimally invasive techniques require smaller incisions and decrease approach-related morbidity

Schwender et al (20) described their technique of mini PLIF. The mean blood loss of 140 ml and mean hospital stay of 1.9 days in their series is comparable to that of 94ml and 3.1 days respectively in our study. The good 14 to excellent 12 clinical outcome in our study of 92, 8% similar to that of 89.4 % of Schwender (20)

The accuracy rate of pedicle screw placement in open was 96.6%, mini-open using Wiltse approach; the accuracy rate was 95.7%. Comparing to our study the accuracy rate was 97.4%.The biggest current limitation of the mini-open approach is that it is not suitable for posterior laminectomy and Posterolateral fusion

CONCLUSION

Although this study is limited by its retrospective nature and small sample size, the results demonstrate

mini invasive spine surgery is cost effective minimal soft tissue dissection with short hospital stay. The authors believe that the data support its use and that this technique may be applicable for cases not needs spinal decompression . Minimally invasive spinal technologies enable surgeons to achieve the same surgical objectives as with a traditional, open procedure.

REFERENCES

- [1] Roy-Camille R, Saillant G, Mazel C. Plating of thoracic, thoracolumbar, and lumbar injuries with pedicle screw plates. *Orthop Clin North Am* 1986; 17 (1): 147-59
- [2] Gaines RW: The use of pedicle-screw internal fixation for the operative treatment of spinal disorders. *J Bone Joint Surg Am* 82-A: 1458-1476, 2000.
- [3] Yuan HA, Garfin SR, Dickman CA, et al: A historical cohort study of pedicle screw fixation in thoracic, lumbar, and sacral spine fusions. *Spine j*, 1994 19 (Suppl 20): 2279S-2296S,
- [4] Dick W, Kluger P, Magerl F, Woersdorfer O, Zach G. A new device for internal fixation of thoracolumbar and lumbar spine fractures: The 'fixateur interne'. *Paraplegia*1985; 23(4): 225 PubMed -32.4S the thoracolumbar injury severity score: a proposed treatment algorithm.
- [5] Vaccaro AR, Zeiller SC, Hulbert RJ, Anderson PA, Harris M, Hedlund R, Harrop J, Dvorak M, Wood K, Fehlings MG, Fisher C, Lehman RA Jr, Anderson DG, Bono CM, Kuklo T, Oner FC, *J Spinal Disord Tech.* 2005 Jun; 18(3):209-15.5S A new classification of thoracolumbar injuries: the importance of injury morphology, the integrity of the posterior ligamentous complex, and neurologic status.
- [6] Lowery GL, Kulkarni SS: Posterior Percutaneous spine instrumentation. *Eur Spine J* 2000, 9 (Suppl 1):S126-S130, -
- [7] Weinstein JN. Surgical approaches to the lumbar spine. In: Weinstein SL, editor. *The pediatric spine: principles and practice.* New York: Raven; 1994. pp. 1369-80. [Ref list]
- [8] Garfin SR, Fardon DF ,Emerging technologies in spine surgery. *Spine J.* 2002 Jan-Feb; 2 (1): 1-4.

Minimally Invasive Spine Osteosynthesis (MISO) Technique Versus Traditional and Paraspinal Posterior Open Approaches for Treatment of Thoracolumbar Spine Fractures

- [9] Ringel F, Stoffel M, Stüer C, Meyer B., Minimally invasive transmuscular pedicle screw fixation of the thoracic and lumbar spine. *Neurosurgery*. 2006 Oct; 59(4 Suppl 2):ONS361-6; discussion ONS366-7.
- [10] Schizas C, Michel J, Kosmopoulos V, Theumann N Computer tomography assessment of pedicle screw insertion in percutaneous posterior transpedicular stabilization. *Eur Spine J*. 2007 May; 16 (5): 613-7
- [11] Perisinakis K, Theocharopoulos N, Damilakis J, Katonis P, Papadokostakis G, Hadjipavlou A, Gourtsoyiannis N Estimation of patient dose and associated radiogenic risks from fluoroscopically guided pedicle screw insertion. *Spine* 2004 Jul 15; 29 (14): 1555-60
- [12] MacNab 1 (negative disc exploration: an analysis of the cause of nerve root involvement in sixty patients). *J Bone joint surg. (Am)* 1971; 53: 891-903
- [13] Verlaan, J. J.; Diekerhof, C. H. ; Buskens, E. ; van der Tweel, I. ; Verbout, A. J. ; Dhert, W. J. A. ; Oner, F. C. ,Surgical Treatment of Traumatic Fractures of the Thoracic and Lumbar Spine: A Systematic Review of the Literature on Techniques, Complications, and Outcome *Spine*: April 1st, 2004 - 29 - 7 - p 803-814).
- [14] Siebenga, Jan , Leferink, Vincent J. M. ,, Segers, Michiel J. M. . Elzinga, Matthijs J. Bakker, Fred C. ,, . Haarman, Henk J. Th. M., . Rommens, Pol M. ,, , ten Duis, Henk-Jan ,, Patka, Peter ,, Treatment of Traumatic Thoracolumbar Spine Fractures: A Multicenter Prospective Randomized Study of Operative Versus Nonsurgical Treatment ,*Spine*: 1st, 2006 - 31 - 25 - p 2881-2890.
- [15] Denis F , Armstrong GW , Searls K , andMatta L Acute thoracolumbar burst fractures in the absence of neurologic deficit. A comparison between operative and nonoperative treatment. *Clinical Orthopaedics and Related Research* [01 Oct 1984 (189): 142-149
- [16] Xiang-Yao Sun,Xi-Nuo Zhang and Yong Hai, Percutaneous versus traditional and paraspinal posterior open approaches for treatment of thoracolumbar fractures without neurologic deficit: a meta-analysis*European Spine Journal* 2017, 26, 5, 1418–31
- [17] Wiltse LL. The paraspinal sacrospinalis-splitting approach to the lumbar spine. *Clin Orthop Relat Res* 1973 (91), 48–57.)
- [18] Rampersaud YR, Foley KT, Shen AC, Williams S, Solomito M ,Radiation exposure to the spine surgeon during fluoroscopically assisted pedicle screw insertion. *Spine* 2000 Oct 15; 25 (20): 2637-45
- [19] Kornah BA, safwat HM and Abdel-aal M A , Minimally Invasive Spine Osteosynthesis (MISO) Technique for Fractures Spine: A Case Series 14 Cases. *J Trauma Treat* 5: 336.
- [20] Schwender JD, Holly LT, Rouben DP, Foley KT. Minimally invasive transforaminal lumbar interbody fusion (TLIF); technical feasibility and initial results. *J Spinal Disord Tech* 2005; 18 (suppl): S1-6.

Citation: Bahaa Ali kornah et al. *Minimally Invasive Spine Osteosynthesis (Miso) Technique Versus Traditional and Paraspinal Posterior Open Approaches for Treatment of Thoracolumbar Spine Fractures. Archives of Orthopedics and Rheumatology*. 2018; 1(2): 10-19.

Copyright: © 2018 Bahaa Ali kornah et al. This is an open access article distributed under the Creative Commons Attribution License, which permits unrestricted use, distribution, and reproduction in any medium, provided the original work is properly cited.