

Bronchogenic Cyst: An Update on Diagnosis and Treatment

Yasser Ali Kamal*, Yasser Shaban Mubarak

Department of Cardiothoracic Surgery, Minia Cardiothoracic University Hospital, El-Minia, Egypt.
yaser_ali_kamal@yahoo.com

***Corresponding Author:** Yasser Ali Kamal, Department of Surgery, Minia Cardiothoracic University Hospital, El-Minya, 61519, Egypt.

Abstract

Bronchogenic cyst (BC) is a congenital malformation derived from primitive foregut, often located in the mediastinum and lung parenchyma. Most of the cases are symptomatic or associated with complications related to infection or compression. Some cases are asymptomatic and incidentally discovered during or beyond childhood. Computed tomography is valuable diagnostic modality in determining the site, size and relations of BC. A debate remains regarding surgery for asymptomatic BC, however, complete surgical excision is recommended for symptomatic cases as incomplete excision is associated with high rate of recurrence. This article aims to review the literature for update concerns of diagnosis and treatment of BC.

Keywords: Congenital cystic lung malformations, tracheobronchial tree, mediastinal mass, bronchogenic cyst

INTRODUCTION

Bronchogenic cyst (BC) is an embryonic foregut malformation arises from aberrant budding between the 3rd and 6th week of gestation, constituting up to 15% of congenital cystic lung malformations [1]. It can occur at any point of the tracheobronchial tree with common location in the mediastinum, thus BC accounts for 10% of all mediastinal masses with a male predominance [1, 2].

In this article we aim to evaluate the current literature for update information about diagnosis and treatment

of BC. Searching MEDLINE using the keyword of (bronchogenic cyst) on August 2018 revealed 1666 abstracts. The most relevant papers consistent with the purpose of our review were 888, out of which 38 full-text papers were included as references in our article.

PATHOLOGY

Typically, BC is a cystic lesion lined by pseudostratified columnar epithelium, filled with clear fluid, hemorrhagic secretions or air, and contains cartilage and bronchial mucus glands (Figure 1) [2].

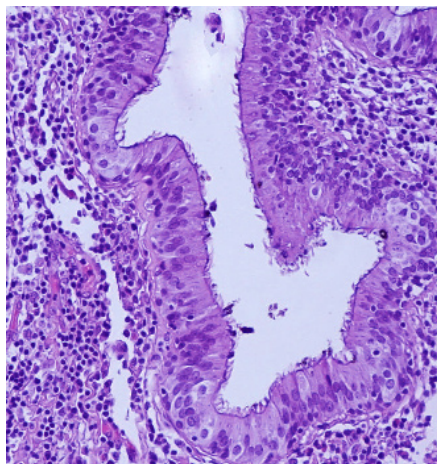


Fig 1. Microscopic view of bronchogenic cyst. Hematoxylin and eosin stained photomicrograph (magnification $\times 200$) showing pseudostratified ciliated columnar epithelium lining a bronchogenic cyst.

Bronchogenic Cyst: An Update on Diagnosis and Treatment

The intra-thoracic mediastinal location of BC is more frequent in the middle mediastinum with three types: para-tracheal (type I), bronchial bifurcation (type II), and hilar (type III), while BC arising in the posterior mediastinum may be para-esophageal (type IV) or has other locations (type V) [3].

Other locations of BC include sub-diaphragmatic, intra-diaphragmatic, supra-clavicular, infra-clavicular, suprasternal, shoulder, neck, retro-peritoneal, scapular and thoracolumbar or lumbar spinal regions [4-8].

The location of tracheal BC may be intraluminal between the mucosa and sub-mucosa layer, or intramural between the cartilages and adventitia [9]. In rare instances, BC may have cutaneous or subcutaneous location, commonly in the scapular region, when a part of the anterior portion of the developing lung is pinched off by the fusing right and left bars of the sternum [8, 10]. Another rare entity of BC is the association of this cystic lesion with a congenital pericardial defect [11].

The reported pathological complications of BC include rupture, infection, and malignant degeneration. The muco-epidermoid carcinoma was reported to arise from a bronchogenic cyst [12].

CLINICAL PRESENTATION

The most of cases with BC are asymptomatic. The symptomatic cases have a wide range of symptoms, depending on the location and size of BC, and including chronic cough, dyspnea, dysphagia, chest pain, hoarseness and stridor during sleeping [2, 13].

In symptomatic patients with intra-thoracic BC (mediastinal or intra-pulmonary), cough is the most common complaint, followed by other symptoms including chest pain, fever, and sputum expectoration [14]. Bronchogenic cyst is an unusual cause of a persistent cough and wheeze in children, thus it is important to consider it in the differential diagnosis of a child presenting with refractory asthma-like symptoms [1].

Moreover, esophageal bronchogenic cyst should be included in the differential diagnosis of a patient with dysphagia, as most of these cases may present with chest pain, cough, dyspnea, and dysphagia [15]. The cases of intra-abdominal BC may have a complaint of epigastric pain or left upper quadrant discomfort. Malignant transformation of intra-abdominal BC

on presentation is rare and most of the cysts are discovered incidentally and benign in nature [16].

The patients with BC may primarily present with a complications of BC as a result of compression of adjacent structures, infection or rupture of the cyst. The reported complaints subsequent to complications of BC include: pneumothorax, pleuritis, and severe hemoptysis [17]. Furthermore, the mediastinal BC may be acutely complicated by atrial fibrillation, pericardial and pleural effusions, and pulmonary vein thrombosis [18].

INVESTIGATIONS

Initially, chest x-ray in a patient with BC may reveal a homogenous lesion, deviation of trachea, and signs of parenchymal compression as atelectasis or emphysema [1]. In patients diagnosed with mediastinal BC, the most frequent findings on chest radiographs include homogenous mass lesions, cystic mass lesions containing air-fluid levels and pleural effusion. On the other hand, the most frequent findings in patients with intrapulmonary BC include cysts with heterogeneous air-fluid levels, homogenous mass lesions and pneumonic consolidation. However, most of the cases with BC could not be identified on chest radiographs [14].

Therefore, there is a need for more accurate imaging modalities to diagnose BC, including computed tomography (CT), flexible laryngoscopy, magnetic resonance imaging (MRI) and 2-(18F)-fluoro-2-deoxy-D-glucose positron emission tomography (PET)/CT. A combination of these modalities can provide an assessment of the properties and location of the lesion, the degree of laryngeal constriction and the association of the lesion with surrounding vital structures [2, 19].

On chest CT, BC may appear as masses of soft tissue or water attenuation with well-defined margins (Figure 2). The most frequent CT findings in patients with mediastinal BC are homogenous solid mass, homogenous cystic mass and heterogeneous cystic mass containing air-fluid levels, respectively, while heterogeneous cystic masses containing air-fluid levels is the most frequent finding in patients with intrapulmonary BC [2, 14]. Abdominal CT is the investigation of choice for the final diagnosis of intra-abdominal BC, as it is helpful to evaluate the cyst contents and to differentiate it from other retroperitoneal and intra-abdominal cystic lesions [16].

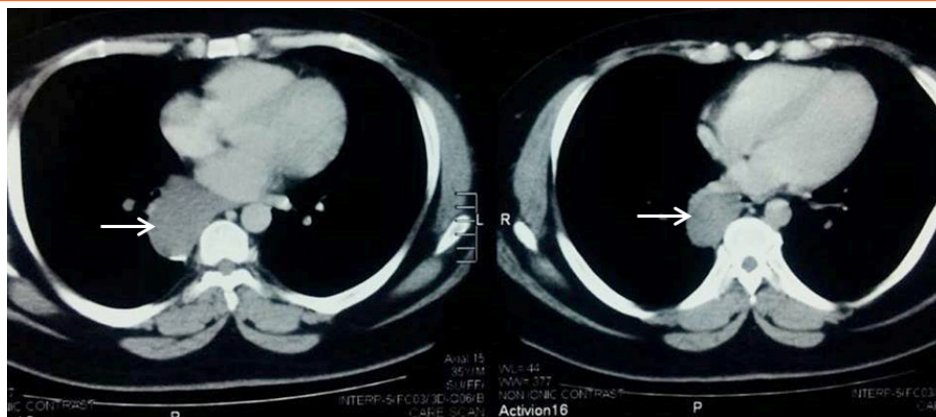


Fig 2. Axial view of chest CT showing paravertebral bronchogenic cyst in the posterior mediastinum with well-defined margins and homogenous content (arrows).

The diagnostic role of MRI in patients with BCs is considered to reveal the cystic nature of the mass. The majority of bronchogenic cysts have intermediate to

higher signal intensity on T1-weighted images and characteristically exhibit high signal intensities on T2-weighted images (Figure 3)[20].

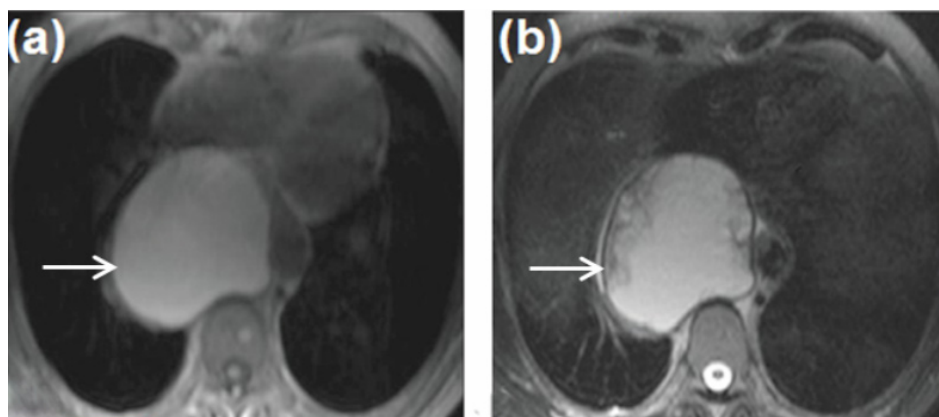


Fig 3. Axial MR images of a bronchogenic cyst: (a) T1-weighted image showing posterior mediastinal lesion with an increased signal intensity (arrow), and (b) T2-weighted image confirms the cystic nature of the lesion with a well-defined wall (arrow).

A histopathological evidence is the definite diagnostic test of BC, where the cyst wall is composed of pseudo stratified ciliated columnar or cuboidal epithelium, however, in most of instances fine needle aspiration biopsy (FNAB) does not appear to be a reliable diagnostic test as it is difficult to target the thin wall of a BC exactly [9].

Preoperative diagnosis using endosonography is an emerging modality. Endobronchial ultrasound-guided transbronchial fine needle aspiration (EBUS-TBNA) provides real-time visualization, and it is feasible to approach BC whenever a superimposed infection is suspected [21]. This modality is useful to obtain cystic fluid for cytology and bacterial culture study, and it can provide instant decompression of the cyst and relieve the pressure on the surrounding structures [22].

TREATMENT

For many years, there was a consensus to choose between conservative and surgical treatment of BC in accordance to its location, size and symptoms, thus surgery was preserved for symptomatic and low-risk patients [23]. However, this concept has been changed in the contemporary practice by some surgeons when surgical excision is undertaken for symptomatic and asymptomatic patients to alleviate airway obstruction, and to prevent the possible complications with long-standing lesions [2, 24-26]. Moreover, the complete excision of antenatally diagnosed BC has been recommended before the age of 2 years to prevent complications and to facilitate surgical dissection [27].

Bronchogenic Cyst: An Update on Diagnosis and Treatment

Complete excision of the cyst is crucial for mediastinal BC (Figure 4, a), while lobectomy (Figure 4, b) is the best treatment for intrapulmonary BC and wedge resection can be performed for cases with small peripheral cysts [14, 28]. The goal of surgery should be complete excision of the cyst as 10-years local recurrence is high after incomplete excision [29].

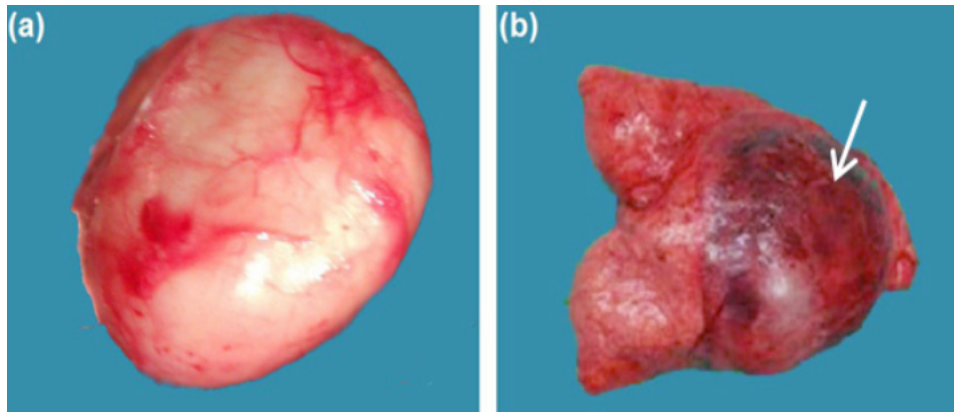


Fig 4. Photographs of excised bronchogenic cysts: (a) completely excised mediastinal cyst, and (b) lobectomy containing the cystic lesion (arrow).

The current surgical options for BC include: thoracotomy, video-assisted thoracoscopic surgery (VATS), and mediastinoscopy [31]. Thoracotomy should be always kept in mind in cases with dense adhesions [32], while VATS can be a good surgical option for decompression and excision of the cyst because it enables a quick approach to the mass, even in a patient with a compromised cardiovascular condition [31]. Moreover, Da Vinci Robotic System in the surgery for mediastinal BC showed encouraging results [32-34], with a recommendation of minimally invasive resection of mediastinal BC to avoid the risk of scoliosis development in childhood following thoracotomy [32].

Although surgery is recommended once BC is suspected, the surgical approach may be limited by thickened cystic wall, severe adhesions to the surrounding structures, and the possibility of unexpected hazardous conditions that could be caused by the pericardial effusion remaining in the cavity [31].

Intraoperative drainage has been recommended to help surgical dissection of the cystic lesion from severe adhesion and to prevent incomplete resection [35]. The use of transbronchial needle aspiration (TBNA) may enable complete aspiration of the cyst causing the collapse of the cystic space with the consequent adhesion of the mucosal surfaces of the

The presence of BC with tense adhesions may be a challenge for complete excision of the cyst, thus partial excision with de-epithelization must be performed to prevent recurrence [30]. Ethanol injection into the cyst wall or electrocautery is to destroy the epithelial layer are required when resection is incomplete [22].

cavity which may reduce the likelihood of recurrence [36, 37]. However, TBNA may be used only in cases of acute compression or in compromised or non-operative patients [38]. To adopt a simple TBNA as the first approach treatment for suspected BC, it will be necessary to program a careful clinical and radiological follow up [36].

CONCLUSION

Bronchogenic cyst is a rare congenital cystic lung malformation. The mediastinum is the most common location of BC, while it has been reported in other locations from oral cavity to lumbar region. The clinical presentation of BC is variable as it may be symptomatic, asymptomatic or complicated. The initial findings on chest radiographs may increase the attention for the need of further diagnostic tests. CT remains the gold standard for the imaging diagnosis of BC. Combination of the proper imaging modalities is a preferable approach for an accurate diagnosis of BC. The definite diagnostic test of BC is the characteristic features on histopathological examination, while preoperative FNAC may be difficult or non-diagnostic. EBUS-TBNA is an emerging preoperative modality for aspiration and decompression of BC contents; however, its use as first-line approach remains controversial. Complete surgical excision of BC is the best choice for treatment. A controversy exists regarding surgery for asymptomatic patients with a current preference of

surgery to prevent life-threatening complications. If incomplete excision is performed, de-epithelization by ethanol injection into the cyst wall or electrocautery should be considered. The current surgical options include thoracotomy, VATS, mediastinoscopy and robotic surgery, with a preference for thoracotomy in cases with dense adhesions. A controversy remains regarding the role of perioperative drainage of BC, with a limitation of its use for cases of acute compression, compromise or non-operative eligibility.

REFERENCES

- [1] Abushahin A, Zarroug A, Wagdi M, Janahi I. Bronchogenic cyst as an unusual cause of a persistent cough and wheeze in children: A case report and literature review. *Case Rep Pediatr*. 2018; 2018: 9590829. doi: 10.1155/2018/9590829.
- [2] Lu D, Yu R, Yang H, Liu J. A bronchogenic cyst of the larynx. *Exp Ther Med*. 2017;14(6):5523-6. doi: 10.3892/etm.2017.5237.
- [3] Kubouchi Y, Nakamura H, Fujioka S, Miwa K, Takagi Y, Yurugi Y, Haruki T, Taniguchi Y. Thoracoscopic Resections of Bronchogenic Cysts Arising in the Posterior Mediastinum: a report on 3 patients. *YonagoActa Med*. 2010;53(4):77-81.
- [4] Demirkol S, Samedli S, Balta Ş, Bozlar U. A mass compressing the left atrium. *Bronchogenic cyst*. *AnadoluKardiyolDerg*. 2014;14(1):95, 104. doi: 10.5152/akd.2013.4792.
- [5] Parshotam G, Ashish J, Justin K, Bruce C. Congenital Cervical Bronchogenic Cyst - A case report and review of literature. *ANZ J Surg*. 2010;80(12):945. doi: 10.1111/j.1445-2197.2010.05558.x.
- [6] Subramanian S, Chandra T, Whitehouse J, Suchi M, Arca M, Maheshwari M. Bronchogenic cyst in the intradiaphragmatic location. *WMJ*. 2013;112(6):262-4.
- [7] Lee HD, Han SH, Park SB, Ko Y, Lee KH. An intradural extramedullary bronchogenic cyst in the thoracolumbar spine: A case report. *Medicine (Baltimore)*. 2017;96(50):e9263. doi: 10.1097/MD.00000000000009263.
- [8] Al-Balushi Z, Ehsan MT, Al Sajee D, Al Riyami M. Scapular bronchogenic cyst : a case report and literature review. *Oman Med J*. 2012;27(2):161-3. doi: 10.5001/omj.2012.33.
- [9] Ohba G, Toma M, Komori K, Hirobe S, Fukuzawa R. Intramural tracheal bronchogenic cyst: a case report. *Springerplus*. 2014;3:262. doi: 10.1186/2193-1801-3-262.
- [10] Manchanda V, Mohta A, Khurana N, Das S. Subcutaneous bronchogenic cyst. *J CutanAesthet Surg*. 2010;3(3):181-3. doi: 10.4103/0974-2077.74498.
- [11] Hiraoka K, Yamazaki S, Hosokawa M, Suzuki Y. Bronchogenic cyst associated with congenital absence of the pericardium. *J Surg Case Rep*. 2015;2015(4). pii: rjv052. doi: 10.1093/jscr/rjv052.
- [12] Taira N, Kawasaki H, Atsumi E, Ichi T, Kawabata T, Saio M, Yoshimi N. Mucoepidermoid carcinoma of arising from a bronchogenic cyst of the diaphragm. *Ann ThoracCardiovasc Surg*. 2018. doi: 10.5761/atcs.cr.17-00131.
- [13] Williams HJ, Johnson KJ. Imaging of congenital cystic lung lesions. *PaediatrRespir Rev*. 2002; 3: 120-7.
- [14] Lee DH, Park CK, Kum DY, Kim JB, Hwang I. Clinical characteristics and management of intrathoracic bronchogenic cysts: a single center experience. *KoreanJThoracCardiovascSurg*. 2011;44(4):279-84. doi: 10.5090/kjtcs.2011.44.4.279.
- [15] Kaistha A, Levine J. An Unusual Cause of Pediatric Dysphagia: Bronchogenic Cyst. *Glob Pediatr Health*. 2017; 4: 2333794X16686492. doi: 10.1177/2333794X16686492.
- [16] Trehan M, Singla S, Singh J, Garg N, Mahajan A. A rare case of intra-abdominal bronchogenic cyst- A case report. *J ClinDiagn Res*. 2015;9(11):PD03-4. doi: 10.7860/JCDR/2015/12949.6761.
- [17] Sarper A, Ayten A, Golbasi I, Demircan A, Isin E. Bronchogenic cyst. *Tex Heart Inst J*. 2003;30:105-8.
- [18] Marshall G, Cheah C, Lenzo N. Bronchogenic cyst with multiple complications. *Biomed Imaging Interv J*. 2007;3(4):e42. doi: 10.2349/bij.3.4.e42.
- [19] Yoon YR, Choi J, Lee SM, Kim YJ, Cho HD, Lee JW, Jeon YS. Retroperitoneal bronchogenic cyst presenting paraadrenal tumor incidentally detected by (18)F-FDG PET/CT. *Nucl Med Mol Imaging*. 2015;49: 69-72.

Bronchogenic Cyst: An Update on Diagnosis and Treatment

- [20] Govaerts K, van Eyken P, Verswijvel G, Van der Speeten K. A bronchogenic cyst, presenting as a retroperitoneal cystic mass. *Rare Tumors* 2012; 4: e13.
- [21] Kuo CH, Chung FT, Kuo HP. Infected bronchogenic cyst diagnosed by endobronchial ultrasound-guided transbronchial needle aspiration. *J Formos Med Assoc.* 2013;112(7):436-7. doi: 10.1016/j.jfma.2011.11.033.
- [22] Alraiyes AH, Shaheen K, Reynolds J, Machuzak M. Recurrent bronchogenic cyst after surgical resection. *Ochsner J.* 2015 Summer;15(2):176-9.
- [23] Tiwari MK, Yadav R, Mathur RM, Shrivastava CP. Mediastinal bronchogenic cyst presenting with dysphagia and back pain. *Lung India* 2010;27: 86-8.
- [24] Stewart B, Cochran A, Iglesia K, Speights VO, Ruff T. Unusual case of stridor and wheeze in an infant: Tracheal bronchogenic cyst. *PediatrPulmonol.* 2002; 34: 320-3.
- [25] Hernández-Solís A, Cruz-Ortiz H, Gutiérrez-DíazCeballos ME, Cicero-Sabido R. Bronchogenic cysts. Importance of the infection in adults. Study of 12 cases. *Cir Cir.* 2015; 83: 112-6.
- [26] Kluger MD, Tayar C, Belli A, Salceda JA, van Nhieu JT, Luciani A, Cherqui D. A foregut cystic neoplasm with diagnostic and therapeutic similarities to mucinous cystic neoplasms of the pancreas. *JOP.* 2013; 14: 446-9.
- [27] Maurin S, Hery G, Bourliere B, Potier A, Guys JM, Lagausie PD. Bronchogenic cyst: Clinical course from antenatal diagnosis to postnatal thoroscopic resection. *J Minim Access Surg.* 2013; 9(1): 25-8. doi: 10.4103/0972-9941.107132.
- [28] De Giacomo T, Diso D, Anile M, Venuta F, Rolla M, Ricella C, Coloni GF. Thoroscopic resection of mediastinal bronchogenic cysts in adults. *Eur J Cardiothorac Surg.* 2009; 36:357-9.
- [29] Hasegawa T, Murayama F, Endo S, Sohara Y. Recurrent bronchogenic cyst 15 years after incomplete excision. *Interact CardiovascThorac Surg.* 2003; 2: 685-7.
- [30] Ribet ME, Copin MC, Gosselin BH. Bronchogenic cysts of the lung. *Ann Thorac Surg.* 1996; 61: 1636-40.
- [31] Han SJ, Cho HJ, Kang MW, Yu JH, Na MH, Kang SK. A Life-Threatening Bronchogenic Cyst. *Korean J ThoracCardiovasc Surg.* 2018;51(1):69-71. doi: 10.5090/kjtcs.2018.51.1.69.
- [32] Toker A, Özyurtkan MO, Kaba E, Nova G. Da Vinci Robotic System in the surgery for mediastinal bronchogenic cyst. *J Vis Surg.* 2015;1:23. doi: 10.3978/j.issn.2221-2965.2015.11.08.
- [33] Yoshino I, Hashizume M, Shimada M, Tomikawa M, Sugimachi K. Video-assisted thoracoscopic extirpation of a posterior mediastinal mass using the da Vinci computer enhanced surgical system. *Ann Thorac Surg.* 2002;74:1235-7.
- [34] Xu S, Liu B, Wang X, Meng H, Wang T, Wang S. Robotic thoracic surgery of the anterior superior mediastinal bronchogenic cyst. *Ann Transl Med.* 2015;3:57.
- [35] Kim YH, Kim JJ, Choi SY, Jeong SC, Kim IS. Complete thoracoscopic excision of an infected bronchogenic cyst. *JThoracDis.* 2017;9(11):E979-E981. doi: 10.21037/jtd.2017.08.172.
- [36] Andreani A, Cappiello G, Valli M, Giovannini M. TBNA for the treatment of non-complicated bronchogenic cyst. *Monaldi Arch Chest Dis.* 2013; 79(3-4):143-5.
- [37] Galluccio G, Lucantoni G. Mediastinal bronchogenic cyst's recurrence treated with EBUS-FNA with a long-term follow-up. *Eur J of Cardiothoracic Surg.* 2006; 29: 627-9.
- [38] Ribet E, Copin MC, Gosselin B. Bronchogenic cyst of the mediastinum. *J ThoracCardiovasc Surg.* 1995; 109: 1003-10.

Citation: Yasser Ali Kamal, Yasser Shaban Mubarak. *Bronchogenic Cyst: An Update on Diagnosis and Treatment. Open Journal of Surgery.* 2018; 1(1): 19-24.

Copyright: © 2018 Yasser Ali Kamal, Yasser Shaban Mubarak. This is an open access article distributed under the Creative Commons Attribution License, which permits unrestricted use, distribution, and reproduction in any medium, provided the original work is properly cited.