

Adult Laryngeal Haemangioma Misdiagnosed as Obstructive Sleep Apnoea

Sushila Kaushal^{1*}, Muhammad Shakeel², Jaiganesh Manickavasagam^{3,4}

¹Clinical Development Fellow in ENT.

^{2,3}Consultant ENT and Head & Neck Surgeon.

^{1,2}Department of Otolaryngology - Head & Neck Surgery, Aberdeen Royal Infirmary, Foresterhill Road, Aberdeen, AB25 2ZN, UK.

³Department of Otolaryngology - Head & Neck Surgery, Ninewells Hospital, UK.

⁴Tayside Academic Medical Centre, University of Dundee, Dundee, DD1 9SY, UK

***Corresponding Author:** Miss Sushila Kaushal, Department of Otolaryngology - Head & Neck Surgery, Aberdeen Royal Infirmary, Foresterhill Road, Aberdeen, AB25 2ZN, UK.

Abstract

Objectives: To describe a case of airway compromise in a 34-year-old man who suffered complications due to an earlier misdiagnosis of a laryngeal haemangioma as obstructive sleep apnoea.

Methods: A case report and review of the literature.

Case Report: A 34-year-old Caucasian man presented with acute onset haemoptysis and dyspnoea, on an 8-month progressive history of a foreign body sensation in the throat. Nasendoscopy revealed a large vascular mass occupying the pharynx and larynx, causing intermittent and frequent airway obstruction. The patient suffered from a cardiorespiratory arrest, and underwent emergency resuscitation, cricothyroidotomy and subsequent tracheostomy. Once stabilised, a planned excision of the mass was conducted and histology confirmed it to be a benign haemangioma. A Respiratory review had been undertaken two years previously and a clinical diagnosis of obstructive sleep apnoea concluded, following sleep studies. A nasendoscopy had never been performed. Following excision of the lesion his apnoea resolved; suggesting it was the cause of his obstructive sleep apnoea.

Conclusions: The evaluation of patients with suspected obstructive sleep apnoea should be conducted with a multidisciplinary approach involving both Respiratory and Otolaryngology teams. We suggest that as part of their work-up, all patients should undergo nasendoscopic examination of the upper aerodigestive tract in order to exclude mechanical causes of airway obstruction.

Keywords: Haemangioma, Larynx, Obstructive sleep apnoea, Tracheostomy

INTRODUCTION

Laryngeal haemangiomas are slowly-progressive, benign vascular lesions of uncertain aetiology^[1] which usually arise from the supraglottis, and seldom cause airway compromise^[2]. They can be subdivided into paediatric and adult type; the paediatric type being relatively common, and adult type extremely rare^[3]. In children, laryngeal haemangiomas are self-limiting,

with the majority undergoing complete spontaneous involution by the age of 2.5 to 5 years^[4], or responding well to medical treatment with propranolol^[5]. In contrast, adult laryngeal haemangiomas do not regress spontaneously, and there is no evidence-based consensus about medical management for them given their rarity^[6]. For this reason, surgical intervention may be necessary in order to relieve possible symptoms of dysphagia and airway compromise,

Adult Laryngeal Haemangioma Misdiagnosed as Obstructive Sleep Apnoea

and to obtain a diagnosis to differentiate them from malignant pathologies which can present similarly. In this article, we report the case of a patient who suffered significant complications due to earlier misdiagnosis of a laryngeal haemangioma; emphasising the need for clinicians to be aware of this condition and to recognise its symptoms and potential consequences.

PRESENTATION OF CASE

A 34-year-old male ex-smoker presented to our hospital with sudden onset haemoptysis and dyspnoea on an 8-month history of pharyngeal foreign body sensation for which he had not sought medical attention.

Of note in his past medical history, he had been reviewed by the Respiratory team two years earlier with symptoms of snoring and daytime somnolence.

He was diagnosed with severe obstructive sleep apnoea following sleep studies, but did not undergo nasendoscopy to visualise his upper airway at that time. He was non-compliant with CPAP (continuous positive airway pressure) therapy, and unfortunately did not attend follow-up.

On admission he was awake, alert and comfortable but continued to have blood-stained mucus expectoration. He was unable to lie flat because of worsening dyspnoea and was therefore nursed upright. Examination with nasendoscopy showed a large, smooth, pedunculated supraglottic mass of vascular appearances (Fig 1). At this stage it was not possible to establish its origin. This was seen to prolapse anteriorly and occlude the glottic aperture on respiration, causing intermittent airway obstruction.

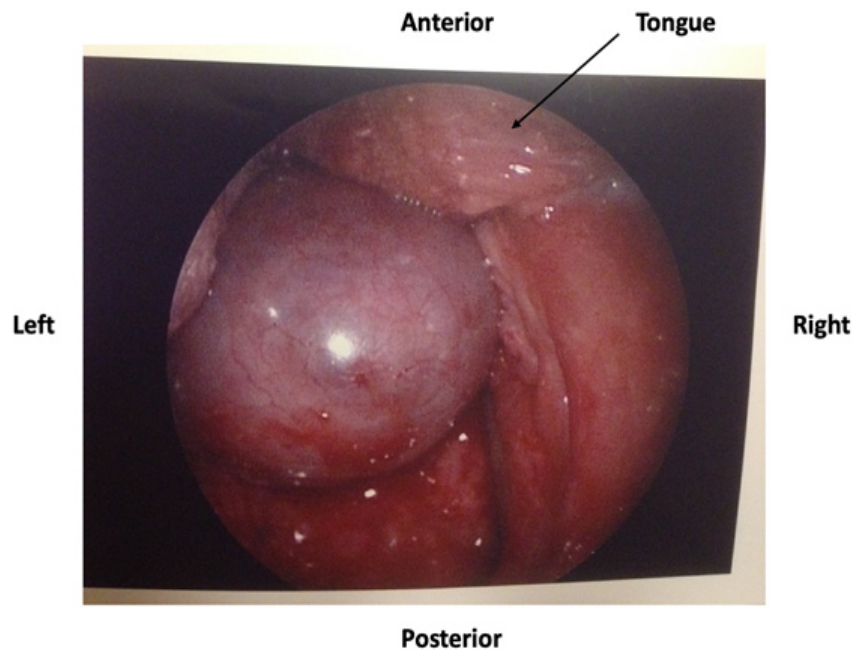


Fig1. Endoscopic trans-oral view of the supraglottic mass when patient lying supine on the operating table after tracheostomy

An urgent contrast CT of his neck, chest and abdomen was obtained (Fig 2 a-c). This revealed a bulky enhancing 3.6 x 2.5 x 3.7cm necrotic mass centred at the posterior and right lateral hypopharyngeal wall, extending superiorly and filling both pyriform fossae. Posteriorly, it extended to the prevertebral fascia with loss of intervening fat, and into the post-cricoid space. The mass appeared to terminate above the pharyngo-oesophagus. Involvement of the posterior aspect of the right paraglottic fat was noted; however, both true and false cords were spared. At the tip of the superior

cornu of the right thyroid cartilage, the mass was seen to abut the right common carotid artery. Some bilateral small level II and III nodes were seen – considering a differential diagnosis of the mass being a malignant tumour, these were equivocal for involvement. No evidence of destruction of the thyroid cartilage was seen. No lung mass or pulmonary nodules were noted, and the imaged abdomen appeared normal. If malignant, the provisional staging for the supraglottic mass was therefore felt to be T2, N0, M0.

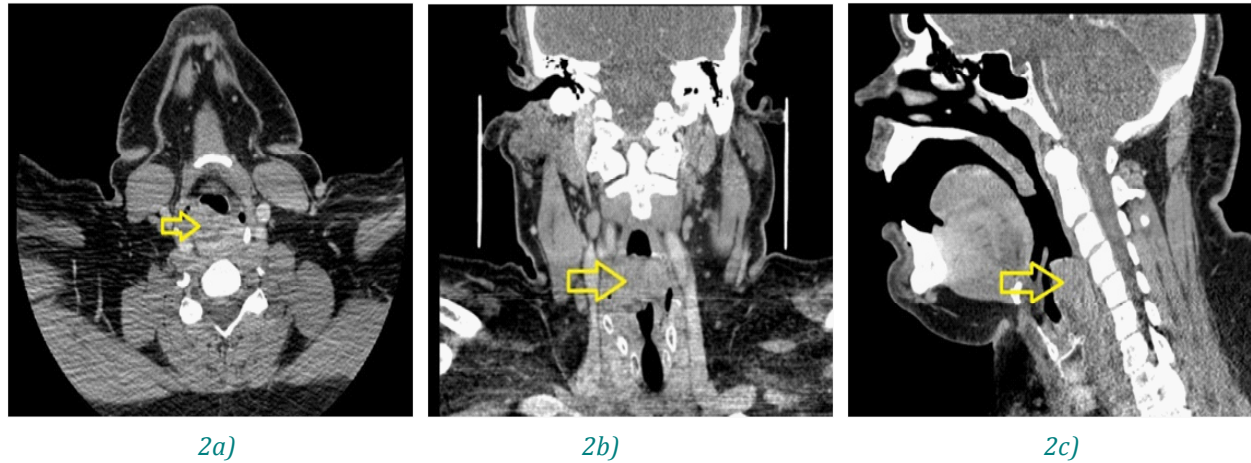


Fig2 a-c. Contrast CT of the neck, showing right supraglottic mass (arrowed); a) axial view, b) coronal view, c) sagittal view

Because of the ongoing small volume haemoptysis and intermittent obstructed breathing, the patient was taken to theatre for further management. While awaiting awake fiberoptic intubation the

patient suffered from a cardiorespiratory arrest; necessitating resuscitation, emergency cricothyroidotomy, intubation and a surgical tracheostomy (Fig 3 and 4).

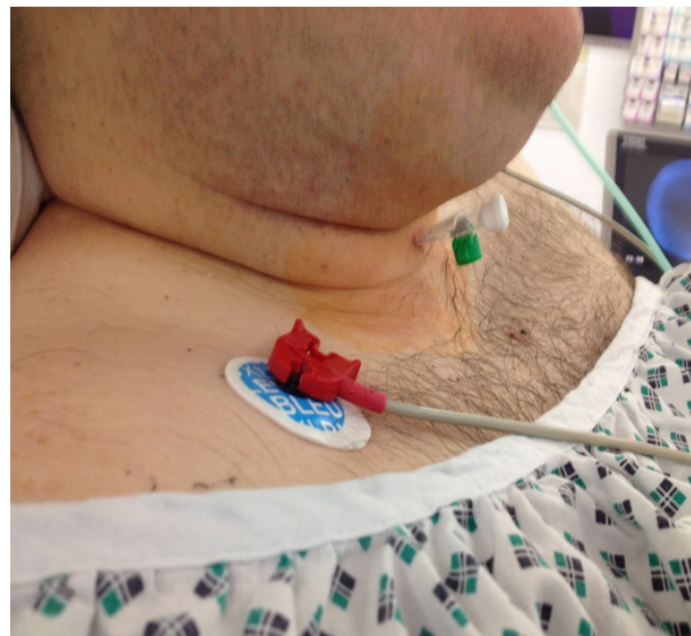

Fig3. Needle cricothyroidotomy

The right arytenoid mass was biopsied at this time and an initial attempt was made to debulk it, however this had to be abandoned due to excessive bleeding from the lesion (Fig 5). This settled down with packing of the pharynx (Fig 6). The patient was subsequently admitted to the Intensive Care Unit where he was kept sedated for two days.

Given the vascular appearances of the right supraglottic mass, with significant bleeding encountered when

an attempt to debulk it was made, a differential diagnosis of an arteriovenous malformation was considered, and a CT angiogram was arranged for further delineation. The histology results from the initial right supraglottic mass biopsy were non-specific; consistent only with squamous mucosa showing mild epithelial hyperplastic change with underlying inflammation. There was no evidence of malignancy.

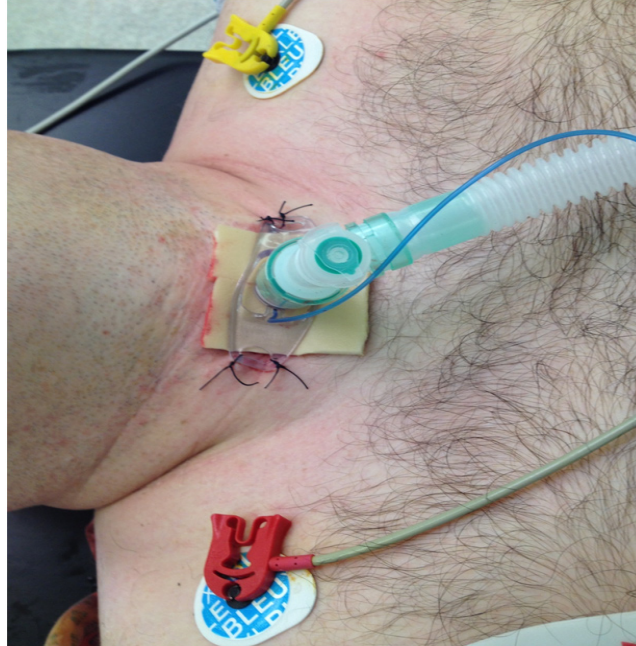


Fig4. Surgical tracheostomy

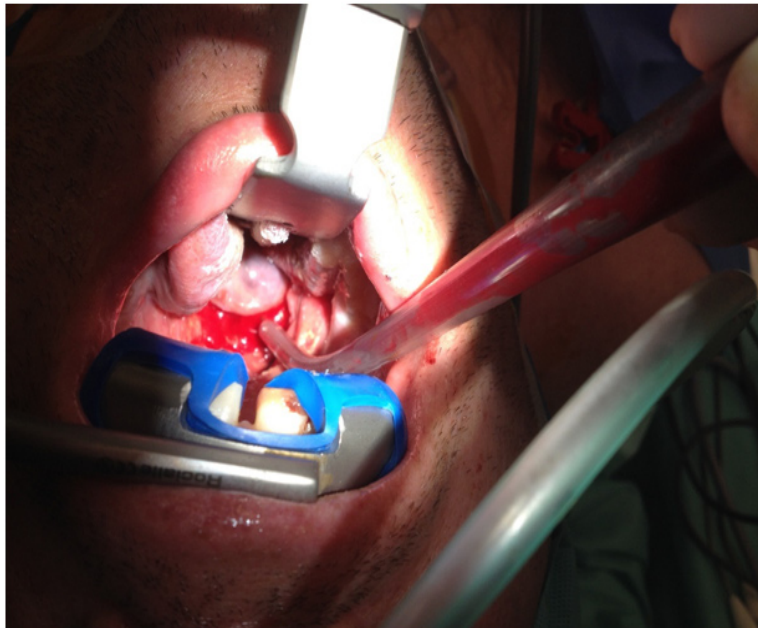


Fig5. The bleeding continued from the hypopharynx with no obvious source of bleeding

The patient's recovery was complicated by hospital-acquired pneumonia, however this responded well to antibiotic treatment, and he was later successfully stepped down to the Otolaryngology ward without further impediment. Feeding was commenced via nasogastric tube as the patient was found to have an unsafe swallow due to significant pharyngeal dysphagia on video fluoroscopy and Speech and Language Therapy team assessment. The patient was successfully discharged home one month and

three days following his initial presentation, with his tracheostomy still in situ and with continued feeding via a nasogastric tube.

A repeat contrast CT of the neck was obtained a month later for surgical planning - this showed no interval change in the right supraglottic mass. Under general anaesthetic the mass was excised trans-orally as described in the article by Mr J Manickavasagam [7].

Adult Laryngeal Haemangioma Misdiagnosed as Obstructive Sleep Apnoea

Following a three-night ICU stay, the patient was stepped down to the Otolaryngology ward, where he continued to make a good recovery. Following excision of the right supraglottic mass, his nocturnal apnoeas completely resolved. The final histology results showed a polypoid lesion comprising of variably sized muscular blood vessels (some of which were thrombosed), with surrounding haemosiderin laden macrophages. These appearances were therefore felt to be in keeping with a laryngeal haemangioma.

The patient underwent regular clinical follow-up over the following months. Nasendoscopic examination of the upper airway performed at three months post excision of the supraglottic mass showed some soft tissue thickening in the left arytenoid area in keeping with scar tissue. Further nasendoscopic examination performed one year after excision of the lesion showed no evidence of recurrence (Fig 7).

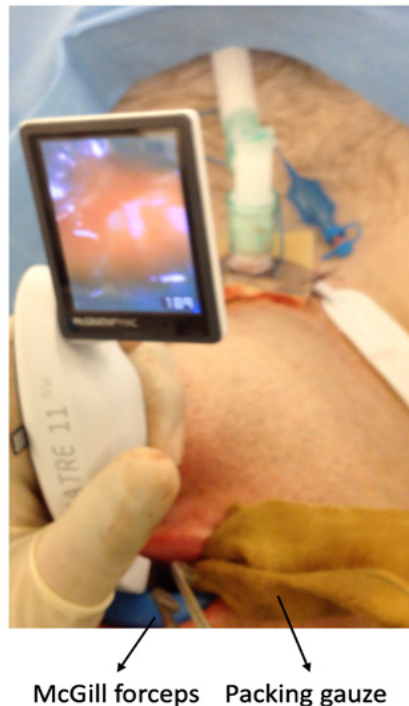


Fig6. Throat packing with antiseptic impregnated gauze using a McGill forceps

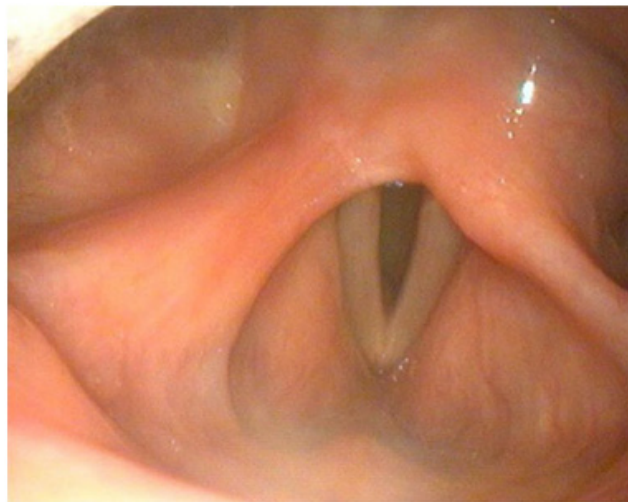


Fig7. Flexible nasendoscopic examination of the larynx at 1 year post excision of the right supraglottic laryngeal haemangioma, showing no evidence of recurrence

DISCUSSION

Acute upper airway obstruction is a life-threatening medical emergency which requires prompt recognition, evaluation and management as demonstrated in this case. The causes of acute upper airway obstruction can broadly be divided into the categories of infectious/inflammatory, traumatic, mechanical and iatrogenic^[8]; laryngeal haemangiomas falling under the mechanical category.

Laryngeal haemangiomas were first described in 1864 by Mackenzie^[9]. By 1921, there were 65 reported cases found in a review of the literature by Moore^[10], however it was not until that year that Sweetser became the first to differentiate between cases occurring in infants, and those occurring in adults^[11].

Infantile laryngeal haemangiomas are the most common head and neck tumour occurring in children, with an incidence of 4-5%^[12]. They account for around 1.5% of all congenital laryngeal anomalies^[13]. In contrast, the incidence of adult laryngeal haemangiomas is unknown due to the lack of case reports. Whereas infantile laryngeal haemangiomas tend to be subglottic and are seen more frequently in females, adult laryngeal haemangiomas usually arise from the supraglottis and predominate in males^[2]. The pathogenesis of infantile laryngeal haemangiomas is thought to be related to an imbalance between positive and negative angiogenic and vasculogenic factors^[14]; accounting for their rapid proliferation and subsequent involution. During their proliferative phase, they can present with symptoms of respiratory distress and stridor. Histologically, the majority of infantile laryngeal haemangiomas tend to be of a capillary type, with small diameter vascular channels^[1].

The aetiology of adult laryngeal haemangiomas is unclear, but it is thought that it could be due to factors such as smoking, vocal abuse and laryngeal trauma (e.g. from intubation)^[1]. It has also been theorised that they may respond to oestrogen and progesterone hormones; with reports in the literature of cases of adult laryngeal haemangiomas proliferating during pregnancy, and subsequently decreasing in size postpartum^[15]. Unlike infantile laryngeal haemangiomas, most adult laryngeal haemangiomas are slowly-progressive and rarely life-threatening. Instead they tend to present with vague symptoms such as hoarseness, cough, haemoptysis, dyspnoea and pharyngeal foreign body sensation^[1]. Our patient

presented with intermittent respiratory distress and persistent blood-stained expectoration. Histologically, adult laryngeal haemangiomas are predominantly of a cavernous type. In contrast to capillary haemangiomas these tend to be larger, located deeper within the submucosal tissues, and consist of wider diameter vascular channels^[1]. Adult laryngeal haemangiomas do not spontaneously regress, and treatment is usually required for symptomatic lesions – the modality of this is governed by the location and extent of the lesion and the patient's performance status. Relatively small lesions can be treated with corticosteroid injections, cryosurgery or CO₂/KTP laser ablation. Larger haemangiomas which extend more deeply into the submucosal tissues are usually best treated by surgical excision (either via microlaryngoscopy or through an open approach) or radiotherapy^[16].

As mentioned, our patient had a preceding diagnosis of severe obstructive sleep apnoea. Obstructive sleep apnoea is a type of sleep-disordered breathing characterised by recurrent collapse of the upper airway causing intermittent hypoxaemia and restless sleep with frequent respiratory effort related arousals, resulting in excessive daytime somnolence. Obstructive sleep apnoea is defined as five or more episodes of apnoea or hypopnoea occurring per hour of sleep (the apnoea-hypopnoea index or AHI). The condition can be further stratified into mild (AHI 5-14/hr), moderate (AHI 15-30/hr) and severe (AHI >30hr)^[17]. Diagnosis is generally achieved by limited sleep studies in the context of high clinical suspicion. The current NICE guidance suggests that those patients with symptoms of obstructive sleep apnoea in addition to specific associated symptoms (including unilateral nasal bleeding, change in voice, severe nasal obstruction, unexplained hoarseness, dysphagia or unusually rapid onset of symptoms in the absence of marked weight gain) should be referred for ENT assessment to rule out significant underlying pathology^[17]. However, when our patient was first diagnosed with obstructive sleep apnoea he did not have any of these symptoms present. He was reviewed once in the ENT clinic, but a flexible laryngoscopic examination was not performed, and he did not attend his follow-up appointment with our department.

It is our opinion that the evaluation of patients with suspected obstructive sleep apnoea should be conducted with a multidisciplinary approach involving both Respiratory and Otolaryngology teams.

Adult Laryngeal Haemangioma Misdiagnosed as Obstructive Sleep Apnoea

We suggest that as part of their work-up, all patients diagnosed with obstructive sleep apnoea on sleep studies should undergo nasendoscopic examination of the upper airway in order to exclude mechanical causes of obstruction.

REFERENCES

- [1] Wang WH, Tsai KY (2015) *Transoral robotic resection of an adult laryngeal haemangioma and review of the literature*. J LaryngolOtol129(6): 614-618
- [2] Barnes L (2000) *Surgical Pathology of the Head and Neck*. 2nd ed, Volume 1. Informa Healthcare, CRC Press:151-152
- [3] Iriz A, Durmaz E, Akmansu SH, Dagli M, Albayrak L (2009) *Vocal Cord Hemangioma; A Rare Localization in Adults*. Turk J Med Sci 39(2): 305-307
- [4] Lomeo P, McDonald J, Finneman J (2000) *Adult laryngeal hemangioma: Report of four cases*. Ear Nose Throat J79: 594, 597-598
- [5] Lei W, Xiling W, Xuefeng X, Chen Z (2015) *Propranolol treatment of subglottic hemangiomas: a review of the literature*. Int J Clin Exp Med8(11): 19886-19890
- [6] Gnepp DR, Bishop JA (2020) *Gnepp's Diagnostic Surgical Pathology of the Head and Neck*. 3rd ed. Elsevier: 405
- [7] Bannon R, Gohil R, Manickavasagam J (2017) *Laparoscopic instrument use in laryngeal surgery: transoral resection of a supraglottic haemangioma*. J LaryngolOtol 131(9): 823-826
- [8] Eskander A, de Almeida JR, Irish JC (2019) *Acute Upper Airway Obstruction*. N Engl J Med 381(20):1940-1949
- [9] Mackenzie M (1871) *Essay on the Growth of the Larynx*. Lindsay and Blakestone, Philadelphia, PA
- [10] Moore I (1921) *Angeiomata of the Larynx*. J LaryngolOtol 36(2): 49-71
- [11] Sweetser TH (1921) *Hemangioma of the larynx*. Laryngoscope 31: 797-806
- [12] McCormick AA, Tarchichi T, Azbell C, Grunwaldt L, Jabbour N (2018) *Subglottic Hemangioma: Understanding the Association With Facial Segmental Hemangioma in a Beard Distribution*. Int J PediatrOtorhinolaryngol 113:34-37
- [13] Holinger PH, Brown WT (1967) *Congenital webs, cysts, laryngoceles and other anomalies of the larynx*. Ann OtolRhinolLaryngol 76(4): 744-752
- [14] Bielenberg DR, Bucana CD, Sanchez R, Mulliken JB, Folkman J, Fidler IJ (1999) *Progressive Growth of Infantile Cutaneous Hemangiomas Is Directly Correlated With Hyperplasia and Angiogenesis of Adjacent Epidermis and Inversely Correlated With Expression of the Endogenous Angiogenesis Inhibitor, IFN-beta*. Int J Oncol14(3):401-8
- [15] Brandwein MS, Abramson AL, Shikowitz MJ (1987) *Supraglottic Hemangioma During Pregnancy*. ObstetGynecol 69(3 Pt 2):450-453
- [16] Karatayli-Ozgursoy S, Basaran M, Umudum H, Akmansu SH (2015) *Adult Laryngeal Hemangioma: A Rare Case Report*. Otolaryngol (Sunnyvale) 5(4): 201
- [17] NICE (2015) *Obstructive sleep apnoea syndrome: clinical knowledge summary*. National Institute for Health and Care Excellence. Available at <https://cks.nice.org.uk/obstructive-sleep-apnoea-syndrome> [Accessed 16 June 2020]

Citation: Sushila Kaushal, Muhammad Shakeel, Jaiganesh Manickavasagam. *Adult Laryngeal Haemangioma Misdiagnosed as Obstructive Sleep Apnoea*. *Open Journal of Otolaryngology*. 2020; 3(2): 26-32.

Copyright: © 2020 Sushila Kaushal, Muhammad Shakeel, Jaiganesh Manickavasagam. This is an open access article distributed under the Creative Commons Attribution License, which permits unrestricted use, distribution, and reproduction in any medium, provided the original work is properly cited.