

## Case Report – Bilateral Vocal Cord Palsy following Hemithyroidectomy

Nilesh Vakharia\*, Samit Unadkat, Paul Stimpson, Michael Papesch

Department of ENT Surgery, Whipps Cross University Hospital, Barts Health NHS Trust, London, UK.

Nilesh.Vakharia@nhs.net

**\*Corresponding Author:** Nilesh Vakharia, Department of ENT Surgery, Whipps Cross University Hospital, Barts Health NHS Trust, London, UK.

### Abstract

Recurrent laryngeal nerve palsy is a recognised complication of thyroid surgery, resulting in temporary or permanent paralysis of the vocal cords. Although rare, bilateral vocal cord paralysis as a result of thyroid surgery is seen exclusively following total thyroidectomy, resulting in dysphonia and if severe, aspiration and airway compromise.

Here we present a unique case of bilateral vocal cord paralysis following hemithyroidectomy, reviewing the aetiopathogenesis of recurrent laryngeal nerve palsy and methods employed to prevent this potentially debilitating complication.

This case highlights the need to consider perioperative causes of injury to the recurrent laryngeal nerve, and steps that can be taken to prevent them.

**Keywords:** Recurrent laryngeal nerve, vocal cord paralysis, hemithyroidectomy, neuropraxis

### BACKGROUND

Recurrent laryngeal nerve palsy is a recognised complication of thyroid surgery, resulting in dysphonia, and if bilateral, airway compromise and aspiration. The resulting dysfunction may be temporary or permanent. The rates of recurrent laryngeal nerve palsy following thyroid surgery varies, and is reported at 0.4% to 7.2% for temporary paresis and from 0% to 5.2% for permanent paralysis<sup>[1]</sup>. Bilateral recurrent laryngeal nerve palsy as a direct complication of thyroid surgery is seen exclusively in total thyroidectomy, and has been described in numerous studies<sup>[2-4]</sup>. Following an extensive review of the literature, we present what we believe is the first case of bilateral laryngeal nerve palsy following hemithyroidectomy surgery and explore the possible aetiopathogenesis.

### CASE PRESENTATION

A 36-year-old woman with no known pre-existing comorbidities, presented to the Head and Neck clinic with a one-year history of a left sided neck lump. Head and neck examination including flexible nasolaryngoscopy

demonstrated a palpable midline neck swelling, with no sinister features and normal symmetrical vocal cord movements. Ultrasound scanning of the lesion demonstrated a 2.2 x 3.4cm nodule within the left thyroid lobe with appearances consistent with a dominant colloid/hyperplastic nodule. This was suggestive of a benign process, graded U2 as per the British Thyroid Association guidelines (2014)<sup>[5]</sup>. The patient opted for a hemithyroidectomy, both for cosmetic reasons and for a definitive histological diagnosis. Her pre-operative voice quality was normal.

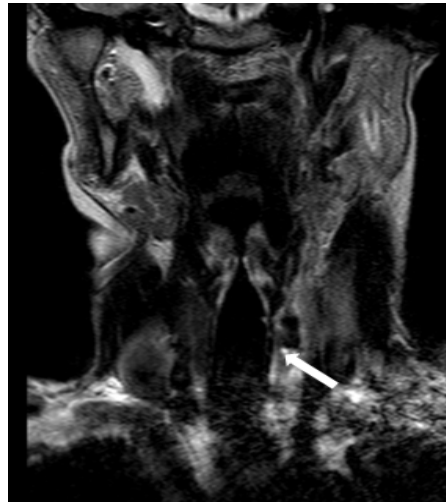
Intra-operatively, she was ventilated using a dedicated cuffed EMG endotracheal tube and positioned supine with neck in extension. There were no intra-operative surgical concerns and the left recurrent laryngeal nerve was identified and stimulated successfully at the end of the procedure.

Post-operatively in recovery, there was no stridor or desaturation but she was profoundly dysphonic. This persisted to the next day and was associated with aspiration on swallowing. Flexible nasolaryngoscopy

## Case Report – Bilateral Vocal Cord Palsy following Hemithyroidectomy

demonstrated a bilateral vocal cord palsy, and unusually the cords were sitting in the paramedian position, suggestive of bilateral recurrent laryngeal nerve paralysis. Blood tests including a corrected

calcium and magnesium were all within the normal range. An MRI scan of the neck was performed (figure 1), but other than a minor seroma in the left thyroid bed, no abnormalities were identified.

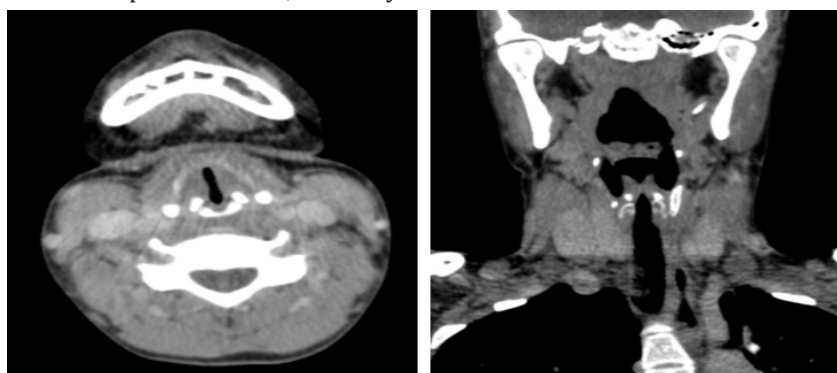


**Fig 1.** Coronal T2 weighted sequence that demonstrates the left thyroidectomy (thick white arrow) with no significant compressive haematoma or collection nor any structural abnormality in the upper mediastinum, lung apices or along the tracheo-oesophageal groove.

Oral steroids (50mg prednisolone) were commenced on the first post-operative day and a speech and language assessment of voice and swallowing was made. The patient required thickened fluids and although she complained of increased respiratory effort, did not require a surgical tracheostomy. She was discharged at day 3 post-operatively, and followed up as an outpatient.

Follow up in the neurology clinic found no abnormality on examination of the cranial or peripheral nervous systems, and the opinion from the neurology team was of bilateral vocal cord dysfunction secondary to neuropraxis. Repeat endoscopic evaluation, at 10 days

post-procedure demonstrated partial recovery of vocal cord movement on the left side, but peculiarly, no improvement on the non-operated, right side. When reviewed at 6 weeks post-operatively, she had regained some mobility of the right vocal cord but continued to have significantly impaired bilateral vocal cord adduction. A CT scan of the neck was performed at this stage to rule out subglottic stenosis (figures 2a and 2b). This demonstrated a partially closed glottis, with medialisation of both vocal folds and no subglottic stenosis. 8 weeks post operatively, her voice had returned to normal, and repeat flexible nasolaryngoscopy demonstrated normal vocal cord movement.



**Fig 2.** CT scan of the neck

*A: Axial contrast enhanced CT at the level of the glottis demonstrating medialisation of both true cords and confirmed clinically as bilateral vocal cord palsies, B: Contrast enhanced CT coronal reformat that demonstrates the left thyroidectomy (thick white arrow), with no evidence of subglottic stenosis and confirms no structural abnormality in the upper mediastinum, lung apices or along the tracheo-oesophageal groove*

### DISCUSSION

Vocal cord dysfunction, from injury to the recurrent laryngeal nerve is a recognised complication of thyroid surgery – the consequences of which can be extremely debilitating. Concerted efforts are taken by surgeons to limit such occurrences through a thorough understanding of the surgical anatomy, the use of loupes magnification and intra-operative nerve monitoring. Thankfully, the reported incidence of bilateral vocal cord palsy remains very low, ranging from 0.58 to 0.63%<sup>[6,7]</sup>. The British Association of Endocrine and Thyroid Surgeons (BAETS) recommend that surgeons ought to be performing a minimum of 20 thyroidectomies per year to be considered safe<sup>[8]</sup>, and Adam et al. (2017) concluded that surgeons performing more than 25 per year had better patient outcomes<sup>[9]</sup>. In the literature to date, there have been no reports of bilateral vocal cord palsy following hemithyroidectomy surgery.

Non-surgical causes of vocal cord dysfunction are well known and include hypocalcaemia, low vitamin D levels<sup>[10]</sup> and as a side effect of Cisplatin and vinca alkaloid based chemotherapy agents<sup>[11]</sup>. Hypocalcaemia is a known complication of thyroidectomy and can lead to laryngospasm, but is seen more frequently following total thyroidectomy<sup>[12]</sup>. In the present case study, the post-operative blood work up including corrected calcium, vitamin D and magnesium were within the normal range.

Compression of the recurrent laryngeal nerve by the endotracheal tube cuff has been suggested as a cause of vocal cord dysfunction, with numerous case reports in the literature following endotracheal intubation<sup>[13,14]</sup>. Cavo (1985) found 6 cases of post-operative bilateral vocal cord palsy in the literature (prior to 1985), none of which were following thyroid surgery<sup>[13]</sup>. Using cadaveric models to investigate the mechanism of injury, he concluded that compression of the anterior branch of the nerve occurred against the rigid thyroid lamina, 6-10mm below the posterior end of the free edge of the vocal cord. He also investigated the fluctuation in cuff pressure depending on the gas used to inflate the cuff, and found that pressure in cuffs inflated with air (as is routine practice in the UK) increased by 8-10mmHg due to diffusion of nitrous oxide across the cuff membrane. Although not routine practice, if inflated with anaesthetic gases, he found little fluctuation in cuff pressure throughout

a procedure. He concluded that the risk of cuff-related nerve palsies can be reduced by a variety of measures including insertion of the endotracheal tube sufficiently distal into the trachea, the use of pressure sensitive release valves, periodic deflation and re-inflation of the cuff and filling the cuff with anaesthetic gases, or a liquid such as normal saline.

Other documented cases of transient bilateral vocal cord palsy, unrelated to neck surgery suggest that patient positioning plays a role<sup>[15,16]</sup>. Nuutinen et al. (1981) and Vyshnavi et al. (2013) concluded that overextension of the neck during intubation resulted in stretching of the vagus nerves. In our case, the patient was positioned with her neck extended, as is commonplace for thyroid surgery, with a shoulder roll and head ring to maintain the patient's position. Although care is taken to avoid hyperextension of the neck, it is not possible to rule out neuropraxia from stretching of the nerve as the cause of bilateral vocal cord paralysis, nor is it possible to rule out a combination of both compression and position.

### CONCLUSION

Vocal cord paralysis is a potentially devastating complication of thyroid surgery leading to functional and psychosocial problems. Diligent identification and preservation of the recurrent laryngeal nerve, the use of intra-operative nerve stimulators and loupes magnification and judicious use of diathermy have all contributed to reducing this risk. Patients who develop bilateral vocal cord palsies are best managed in a multidisciplinary setting.

### KEY POINTS

What is already known:

- Vocal cord paralysis is a relatively rare, but potentially devastating complication of thyroid surgery.
- Causes of vocal cord palsy may be surgical or non-surgical, and are not limited to thyroid surgery.
- Use of intra-operative nerve stimulators and loupes magnification has contributed to reducing risk of damage to the recurrent laryngeal nerve.

What this case adds:

- A unique case of bilateral vocal cord palsy following hemithyroidectomy surgery.

## Case Report – Bilateral Vocal Cord Palsy following Hemithyroidectomy

- A review of the aetiopathogenesis of vocal cord palsy, and the steps that can be taken during surgical procedures prevent it.

We feel this case highlights the need to take extra precautions, not just in thyroid surgery, but in all cases where endotracheal intubation is required, and suggest that ensuring the tube is inserted deep enough past the vocal cords and using cuff pressure monitoring or a pressure-sensitive release valve can help to reduce the risk of compression injury to the nerves. Avoiding excessive hyperextension of the neck, both during intubation and intraoperative patient positioning can also reduce the risk of stretch injury to the nerves, helping to further reduce the incidence of post-operative vocal cord palsy.

### REFERENCES

- [1] Rulli F, Ambrogi V, Dionigi G, Stefano PDI, Medicine T, Vergata RT, et al. Meta-analysis of recurrent laryngeal nerve injury in thyroid surgery with or without intraoperative nerve monitoring. 2014; 73:223–9.
- [2] Dy AES. Transient bilateral vocal fold paralysis after total thyroidectomy. Turkish J. Ear Nose Throat 2016;26(6):356–9.
- [3] Rangappa VB, Ramakrishnan A, Balasubramanya AM, Ram R. Bilateral Adductor Palsy : A Rare Complication during Routine Surgery. :76–8.
- [4] Misron K, Balasubramanian A, Mohamad I, Hassan NFHN. Bilateral vocal cord palsy post thyroidectomy: lessons learnt. BMJ Case Rep. 2014;2014:1–3.
- [5] Perros P, Colley S, Boelaert K, Evans C, Evans R, Gerrard G, et al. Guidelines for the management of thyroid cancer. Clin. Endocrinol. (Oxf). 2014; 81(Supplement 1 July 2014):1–136.
- [6] Ayala MA, Yencha MW. Outpatient Thyroid Surgery in a Low-Surgical Volume Hospital. World J. Surg. 2015; 39(9): 2253–8.
- [7] Zakaria HM, Al Awad NA, Al Kreedes AS, Al-Mulhim AMA, Al-Sharway MA, Hadi MA, et al. Recurrent laryngeal nerve injury in thyroid surgery. Oman Med. J. 2011;26(1):34–8.
- [8] British Association of Endocrine Surgeons. Guidelines for the Surgical Management of Endocrine Disease and Training Requirements for Endocrine Surgery. 2013;
- [9] Adam MA, Thomas S, Youngwirth L, Hyslop T, Reed SD, Scheri RP, et al. Is There a Minimum Number of Thyroidectomies a Surgeon Should Perform to Optimize Patient Outcomes? Ann. Surg. 2017; 265(2):402–7.
- [10] Büyükcım F, Sönmez FT, Şahinli H. A delayed diagnosis: Stridor secondary to hypocalcemia. Int. J. Emerg. Med. 2010;3(4):461–2.
- [11] Myssiorek D. Recurrent laryngeal nerve paralysis: Anatomy and etiology. Otolaryngol. Clin. North Am. 2004;37(1):25–44.
- [12] Bourrel C, Uzzan B, Tison P, Despreaux G, Frachet B, Modigliani E, et al. Transient Hypocalcemia after Thyroidectomy. Ann. Otol. Rhinol. Laryngol. 1993; 102 (7): 496–501.
- [13] Cavo JW. True vocal cord paralysis following intubation. Laryngoscope 1985;95(11):1352–9.
- [14] Jeong DM, Kim GH, Kim JA, Lee SM. Transient bilateral vocal cord paralysis after endotracheal intubation with double-lumen tube. Korean J. Anesthesiol. 2010;59(SUPPL.):9–12.
- [15] Nuutinen J, Kärjä J. Bilateral vocal cord paralysis following general anesthesia. Laryngoscope 1981; 91 (1): 83–6.
- [16] Vyshnavi S, Kotekar N. Aphonia following tracheal intubation: An unanticipated post-operative complication. Indian J. Anaesth. 2013; 57(3): 306–8.

**Citation:** Nilesh Vakharia, Samit Unadkat, Paul Stimpson, Michael Papesch. Case Report – Bilateral Vocal Cord Palsy following Hemithyroidectomy. *Open Journal of Otolaryngology*. 2018; 1(1): 19-22.

**Copyright:** © 2018 Nilesh Vakharia, Samit Unadkat, Paul Stimpson, Michael Papesch. This is an open access article distributed under the Creative Commons Attribution License, which permits unrestricted use, distribution, and reproduction in any medium, provided the original work is properly cited.