

## Onodi Cell Mucocele Causing Unilateral Visual Loss: A Case Study

Yuanpei Zhang<sup>1\*</sup>, Samit N Unadkat<sup>2</sup>, Catherine E Rennie<sup>2</sup>, Hesham A Saleh<sup>2</sup>

<sup>1</sup>Imperial College School of Medicine, London.

<sup>2</sup>Charing Cross Hospital, Imperial College Healthcare, London.

yuanpei.zhang12@imperial.ac.uk

**\*Corresponding Author:** Yuanpei Zhang, Department of Otolaryngology, Charing Cross Hospital, Fulham Palace Road, London.

### Abstract

**Aim:** Onodi cells (sphenoidal cells) are anatomical variants of the posterior most ethmoid air cells which pneumatise superiorly or laterally to the sphenoid sinus. They can be intimately related to the optic nerve and so thorough pre-operative evaluation of the anatomy is essential to avoid potentially devastating complications. Although usually asymptomatic, rarely they can be complicated by sinus disease causing optic neuropathy.

**Methods:** The authors report a rare such case of an Onodi cell mucocoele and its ensuing complications and surgical challenge.

**Results:** An otherwise fit and well 62 year old woman presented elsewhere with sudden, painless right sided visual loss. Pre-operative CT and MRI scanning demonstrated a mucocoele abutting the optic nerve. She was taken to theatre on 2 occasions with unsuccessful drainage of the mucocoele, which was further complicated by an intra-operative CSF leak. This was repaired immediately. A second opinion was sought from our tertiary unit and after the patient's vision deteriorated and further imaging demonstrated persistence of the mucocoele. A third procedure was carried out under image guidance to successfully drain the mucocoele, which was infected. Regrettably, there was no improvement to the patient's vision.

**Conclusions:** Mucocoeles within Onodi cells remain a rare cause of painless visual loss. A thorough systematic pre-operative evaluation of the anatomy must be carried out to identify anatomical variants. The authors advocate early intervention with the aid of image guidance.

**Keywords:** Onodi cell, mucocoele, rhinology, vision loss, obstruction

### INTRODUCTION

Paranasal sinus mucocoeles are cysts lined by mucus secreting respiratory epithelial cells<sup>1</sup>. If left untreated, there can be resultant accumulation and expansion of the cyst that may distort local anatomy and exert pressure on adjacent structures. Anatomical position and frequency is variable; the frontal sinus is particularly prone to developing mucocoeles, with up to two-thirds of all mucocoeles occurring there<sup>23</sup>. The next most common are the anterior ethmoidal sinuses, whereas the maxillary, sphenoidal and posterior ethmoidal sinuses are less frequently involved.

Onodi cells (sphenoidal cells) are anatomical variants of the posterior most ethmoid air cells which

pneumatise superiorly or laterally to the sphenoid sinus. These cells are closely related to the optic nerve<sup>4</sup>, and therefore patients are more likely to experience ocular symptoms such as visual loss, defects in their visual field and extra-ocular palsies rather than nasal symptoms. Given the close proximity of the optic nerve, extreme care must be taken intra-operatively to prevent potentially sight-threatening complications. This involves a thorough pre-operative evaluation of the imaging, and where possible, intra-operative image-guidance.

The incidence of Onodi cells is reported to be between 7% and 14%<sup>567</sup> on imaging studies across the general population. However, Cadaveric studies have

## Onodi Cell Mucocele Causing Unilateral Visual Loss: A Case Study

reported Onodi cells to be present in up to 60% of the specimens<sup>8</sup>, this discrepancy of rate of incidence is likely due to variability in definition rather than true incidence<sup>9</sup>. Mucoceles within Onodi cells are usually asymptomatic and it is only when they expand beyond the confinement of the cell that symptoms ensue from optic neuropathy.

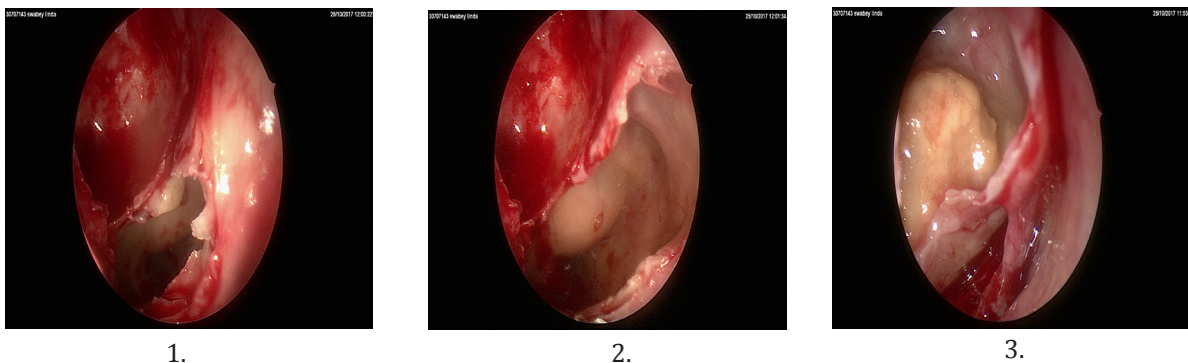
We report a case of rapid visual loss caused by a mucocele of an Onodi cell and the associated intra-operative surgical challenges.

### CASE REPORT

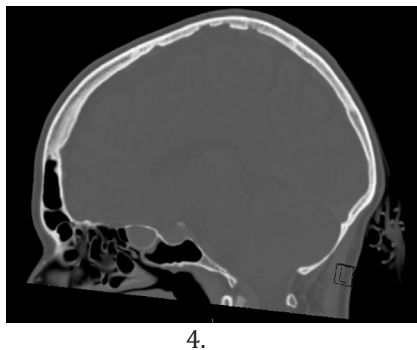
A 62-year-old Caucasian woman presented with sudden, painless right-sided visual loss. She initially presented to her optician with diplopia and loss of colour vision and was given dilating drops to take

home. That evening, her vision deteriorated. She was afebrile with no signs of active infection. She presented to Accident & Emergency but had missed the ophthalmology clinic. Two days later, a Computed tomography (CT) scan revealed a possible large right-sided Onodi cell mucocele abutting the optic nerve. A Magnetic resonance imaging (MRI) scan was not available at this time. Her past medical history was generally unremarkable apart from a previously repaired retinal detachment.

Following a review by ophthalmology, neurology and ENT, an endoscopic approach to the mucocele was attempted. The procedure was unsuccessful, and further complicated by an intraoperative CSF leak. This was repaired immediately. Post-operative MRI confirmed the presence of the residual mucocele.



**Fig 1-3.** Endoscopic Intra-operative photos during third procedure of Onodi Cell Mucocele



**Fig 4.** MRI sagittal view of Onodi Cell Mucocele

A decision was made to re-operate that week. Once again the mucocele was not drained, as confirmed on further post-operative imaging. Dehiscence of the lamina papyracea was noted on the scan. Following the unsuccessful second surgery, a second opinion was sought at our tertiary unit and CT imaging locally demonstrated the persistence of the mucocele in an Onodi cell. It was noted that there was bone thinning in the skull base and the medial orbital wall posteriorly

around the optical apex.

By the time we saw this patient, it had been over a month since her initial presentation, and she had lost all vision in her right eye. A third procedure was carried out under image guidance – this time to successfully drain the mucocele, which was infected. Intra-operatively, there was a dehiscent lamina papyracea, intact periorbita and no evidence of a residual CSF leak. Regrettably, there was no improvement to her vision.

### DISCUSSION

The sphenoidal air cell and its close relation to the optic nerve was first described by Adolf Onodi in 1904<sup>10</sup>. Routine review of pre-operative imaging must identify Onodi cells due to the intimate relation to the optic nerve.

The gold-standard treatment of Onodi cell mucocoeles is through an endoscopic approach. Drainage and marsupialisation of an affected sinus should be sufficient to clear the mucocoele. In the search of the literature, there is no indication to suggest that surgical skill has an impact on the rate of recurrence of mucocoele.

If mucocoeles are not treated despite lack of ocular symptoms, there remains the potential to expand or to become infected. An infected mucocoele would present in a similar manner to acute sinusitis with possible complications due to expansion into adjacent spaces<sup>8</sup>. If the patient was symptomatic, the operation would hope to alleviate compression of the optic nerve in order provide symptomatic relief and to try and preserve the optic nerve.

Onodi cell mucocoeles may affect the optic nerve through two proposed mechanisms; either via mechanical compression causing ischaemia via direct mass effect, or via local inflammation and secondary optic neuritis<sup>11</sup>. Regrettably, the patient in the present study did not have a demonstrable improvement in her vision, despite eventual successful surgery suggesting the need for timely intervention.

A review of the literature, however, has demonstrated variability in this time frame. Fleissig et al (2014) described permanent blindness in one such patient despite intervention within 24 hours<sup>12</sup>, whereas Wu et al (2005) report successful recovery of vision despite a delay of 5 weeks<sup>13</sup>. Lee et al (2016) suggest that 69% of all patients experienced visual improvement after surgery<sup>14</sup>.

### CONCLUSION

The authors conclude that in any patient with rapid-onset unilateral visual loss, early imaging with CT should be undertaken to gather information on the orbits and sinuses. Should a mucocoele be identified in an Onodi cell, early surgical intervention with image-guidance is essential.

### REFERENCES

- [1] Victores A, Foroozan R, Takashima M. Recurrent Onodi cell mucocele: rare cause of 2 different ophthalmic complications. *Otolaryngology--head and neck surgery : official journal of American Academy of Otolaryngology-Head and Neck Surgery*. 2012;146(2):338-9.
- [2] Mafee MF, Valvassori GE, Becker M. *Imaging of the Head and Neck*: Thieme; 2005.
- [3] Toh ST, Lee JC. Onodi cell mucocele: rare cause of optic compressive neuropathy. *Archives of otolaryngology--head & neck surgery*. 2007;133(11):1153-6.
- [4] Kantarci M, Karasen RM, Alper F, Onbas O, Okur A, Karaman A. Remarkable anatomic variations in paranasal sinus region and their clinical importance. *European journal of radiology*. 2004;50(3):296-302.
- [5] Klink T, Pahnke J, Hoppe F, Lieb W. Acute visual loss by an Onodi cell. *The British journal of ophthalmology*. 2000;84(7):801-2.
- [6] Ogata Y, Okinaka Y, Takahashi M. Isolated mucocele in an Onodi cell. *ORL; journal for otorhino-laryngology and its related specialties*. 1998;60(6):349-52.
- [7] Moriyama H, Hesaka H, Tachibana T, Honda Y. Mucoceles of ethmoid and sphenoid sinus with visual disturbance. *Archives of otolaryngology--head & neck surgery*. 1992;118(2):142-6.
- [8] Lim SA, Sitoh YY, Lim TC, Lee JC. Clinics in diagnostic imaging (120). Right rhinogenic optic neuritis secondary to mucocele of the Onodi cell. *Singapore medical journal*. 2008;49(1):84-7; quiz 8.
- [9] Anniko M, Bernal-Sprekelsen M, Bonkowsky V, Bradley P, Iurato S. *Otorhinolaryngology, Head and Neck Surgery*: Springer Berlin Heidelberg; 2010.
- [10] Ónodi A. III. Die Sehstörungen und Erblindung nasalen Ursprunges, bedingt durch Erkrankungen der hinteren Nebenhöhlen. *Ophthalmologica*. 1904;12(1):23-46.
- [11] Chagla AS, Bhaganagare A, Kansal R, Tyagi D. Complete recovery of visual loss following

## Onodi Cell Mucocele Causing Unilateral Visual Loss: A Case Study

---

- surgical treatment of mucopyocele of the anterior clinoid process. *Journal of clinical neuroscience: official journal of the Neurosurgical Society of Australasia*. 2010;17(5):670-2.
- [12] Fleissig E, Spierer O, Koren I, Leibovitch I. Blinding Orbital Apex Syndrome due to Onodi Cell Mucocele. *Case reports in ophthalmological medicine*. 2014;2014:453789.
- [13] Wu W, Sun MT, Cannon PS, Jianbo S, Selva D. Recovery of Visual Function in a Patient with an Onodi Cell Mucocele Compressive Optic Neuropathy Who Had a 5-Week Interval between Onset and Surgical Intervention: A Case Report. *Journal of ophthalmology*. 2010;2010:483056.
- [14] Lee JM, Au M. Onodi cell mucocele: Case report and review of the literature. *Ear, nose, & throat journal*. 2016;95(9):E4-8.

**Citation:** Zhang Y, Unadkat S.N., Rennie C.E., Saleh H.A. *Onodi Cell Mucocele Causing Unilateral Visual Loss: A Case Study*. *Open Journal of Otolaryngology*. 2018; 1(1): 15-18.

**Copyright:** © 2018 Zhang Y, Unadkat S.N., Rennie C.E., Saleh H.A. This is an open access article distributed under the Creative Commons Attribution License, which permits unrestricted use, distribution, and reproduction in any medium, provided the original work is properly cited.