

# A Rare Cause of Nasal Obstruction in Pediatric Patient: Sphenchoanal Polyp

Cengiz Özcan, Onur İsmi, Kemal Görür

Faculty of Medicine, Department of Otorhinolaryngology (KBB) Diseases, Mersin University, Turkey.  
cozcan@mersin.edu.tr

**\*Corresponding Author:** Prof. Dr. Cengiz Özcan, Faculty of Medicine, Department of Otorhinolaryngology (KBB) Diseases, Mersin University, Turkey.

## Abstract

Choanal polyps (CPs) are benign, solitary soft tissue masses which are seen less common compared to nasal polyps. The most common form of the choanal polyps is antrochoanal polyp. Pediatric sphenchoanal polyps are rarely published in the literature. We presented a pediatric patient with sphenchoanal polyp causing nasal obstruction. We discussed the importance of distinguishing sphenchoanal polyp from antrochoanal polyp before the surgery with a detailed review of previous case reports.

**Keywords:** sphenchoanal polyp, choanal polyp, nasal polyp, sphenoid sinus, endoscopic sinus surgery, nasal obstruction.

## INTRODUCTION

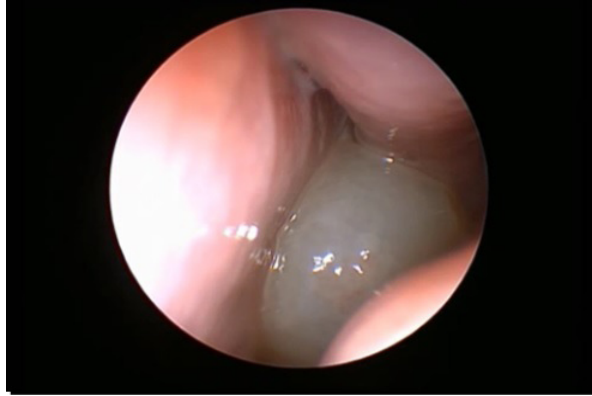Sphenoid sinus is the only paranasal sinus with close proximity to vital structures such as internal carotid artery and optic nerve laterally, pituitary gland and middle cranial fossa superiorly. Differential diagnosis of isolated sphenoid sinus pathologies is broad including inflammatory lesions such as fungal sinusitis, benign neoplasia (e.g. inverted papilloma), internal carotid artery aneurysm, pituitary adenoma, primary or metastatic malignancies. The rarity of these lesions also necessitates thorough investigation of underlying pathology with proper imaging studies [1].

Sphenchoanal polyp (SCP) is a benign solitary mass emerging from sphenoid sinus, passing through the choana extending into the nasopharynx. The first SCP is mostly attributed to Zuckerland in 1892 [2]. In contrast to common nasal polyposis and antrochoanal polyps (ACPs), it is a rare entity [3]. Most of the published cases of SCPs are in adolescent or adult age [4]. Since the first pediatric SCP was reported by Moore et al. in 1919 [5], there have been rare published case reports of pediatric SCPs in the English literature.

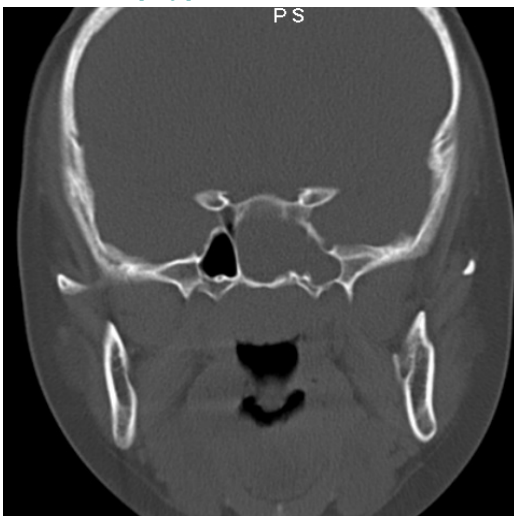
In this case report; we presented a SCP causing nasal obstruction in a pediatric patient.

## CASE REPORT

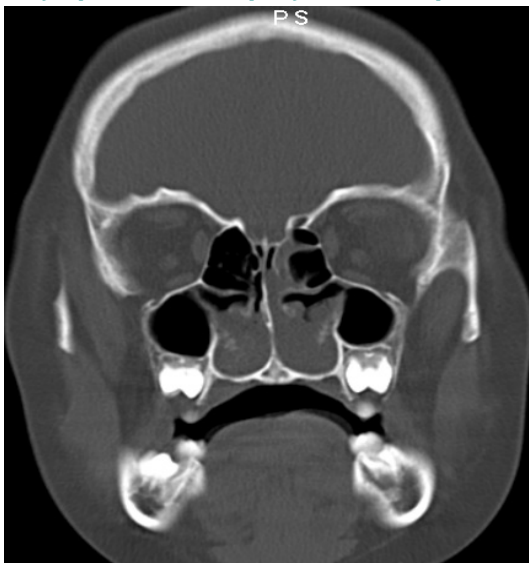
An otherwise healthy thirteen-year-old girl was admitted to our outpatient clinic with the complaint of nasal obstruction and nasal discharge. She had also snoring without apnea. In nasal endoscopic examination using 30° rigid endoscope, a left sided nasal polyp with smooth surface, fulfilling the nasopharynx without involvement of the middle meatus was seen. (Figure 1) On maxillofacial computerized tomography (CT), a left sided nasal mass extending to the choana with sphenoid sinus opacification were seen. The maxillary sinuses were clear. (Figure 2-3). Under the endotracheal general anesthesia, choanal part of the polyp was removed with the through-cutting forceps under the guidance of rigid endoscopes. The pedicle of the polyp was reduced to the sphenoid ostium using microdebrider. The sphenoid ostium was enlarged with mushroom forceps and microdebrider. The cystic part of the polyp inside sphenoid sinus was also removed using forceps. Pathological evaluation of the polyp was well consistent with choanal polyp. Postoperative period was uneventful without complications. The patient was free of the symptoms and polyps on the control endoscopic examinations.



**Figure 1.** Endoscopic view of the left sphenchoanal polyp has been shown.



**Figure 2.** Coronal maxillofacial tomography showing the left sphenoid sinus opacification was presented.



**Figure 3.** Coronal maxillofacial tomography showing the sparing of bilateral maxillary sinuses has been demonstrated.

## DISCUSSION

Choanal polyps (CPs) are benign, solitary soft tissue masses which extend towards the junction of the nasal cavity and nasopharynx [6]. They differ from common nasal polyps in that they are solitary, contain fewer mucus glands and eosinophils [4]. ACP is the most common type of choanal polyps which originates from the maxillary sinus with the pedicle attached to the inner wall of the maxillary antrum, emerging from the posterior fontanelle region or the natural ostium with a stalk [6].

Sign and symptoms of all CPs are similar; nasal obstruction is the most common presentation [7]. Nasal discharge, headache, snoring, ear fullness and hearing loss are other common presenting symptoms [3]. SCPs are mostly seen in adolescents and young adults without gender predominance [4]. ACP develops from the expansion of intramural cyst of the maxillary sinus. It is supposed to develop as a subsequent cyst formation caused by the rupture of an enlarged submucosal gland during the period of recovery from a chronic infection [8]. SCP shares the same histological features with ACPs such as cyst in the center surrounded by edematous stroma with inflammatory cell infiltration, surface of the polyp is covered by respiratory epithelium. Although the exact pathogenesis of SCP is unknown, they seem to have the same pathogenesis with ACPs [3]. Inflammation caused by the sinus infection is supposed to be the main triggering causative factor. Since maxillary sinusitis is seen more common than sphenoid sinusitis, SCPs are seen less common than ACPs [4]. Allergic rhinitis is not a predisposing factor for CPs. Scarcity of eosinophil infiltration, higher number of other inflammatory cells, normal appearance of both basement membrane and surface epithelium with transmission electron microscopic evaluation may indicate that the pathogenesis of CPs is chronic inflammation rather than allergy [9]. Occasionally these CPs may undergo angiomatous degeneration as a result of vascular compromise due to passing through a tight ostia. Compression of feeding vessels induces stasis of blood flow and subsequent edema and dilatation of the polyp. Hypervascular state of some of these CPs needs differential diagnosis of an angiofibroma [8].

## A Rare Cause of Nasal Obstruction in Pediatric Patient: Sphenchoanal Polyp

Choanal polyps need thorough evaluation, because inverted papilloma, malignant melanoma, angiofibroma and other pedunculated tumors should all be in the differential diagnosis [3, 7]. Regarding sphenoid sinus lesions; fungal sinusitis, internal carotid artery aneurysm, pituitary gland tumors, primary or metastatic malignancies also exist in differential diagnosis of a SCP. Making a preoperative diagnosis with endoscopic and radiologic findings will prevent the surgeon from complications such as bleeding or the exploration of the wrong sinus during surgery [7]. It is difficult to identify the sinus of origin of CP with anterior rhinoscopy or plain radiography. The site of origin of CPs are mostly evaluated by nasal endoscopic and CT findings. Nasal endoscopic examination demonstrate a solitary solid polypoid lesion in the posterior part of the nasal passage, but with only nasal endoscopy it is hard to differentiate a SCP from other CPs [3]. CT is helpful for differentiating

a SCP from ACP. In ACP, maxillary sinus is mostly fulfilled, since the polyp extends to nasopharynx lateral to the middle concha, the area between middle concha and the nasal septum is spared. For SCP cases, the polyp occupies sphenothmoid recess and area between nasal septum and middle concha is occupied by the polyp [6, 8, 10].

Although spontaneous resolution of a SCP can occur [11], main treatment is surgery [8]. Destructive surgery to nasal septum and bones such as transseptalsublabial approach to sphenoid sinus is not preferred in a growing child [3]. Endoscopic transnasal approach is the most common preferred route for surgery. Simple polypectomy or avulsion of the CP is related to high recurrence rates, total excision of the polyp's body and stalk inside the sphenoid sinus should be performed to prevent recurrences [3,8]. As shown in table 1, most of the published cases are treated with endoscopic sinus surgery.

**Table 1.** Previous cases of pediatric patients with sphenchoanal polyps.

AUTHOR	YEAR	AGE (years)	RADIOLOGY	TREATMENT
Moore et al.[5]	1919	8	X-Ray	ND
Weissman et al. [10]	1991	11	CT	Transnasal
Ileri et al.[12]	1998	14	CT	ESC
Sethi et al.[13]	1999	15	CT	ESC
Yanagisawa et al. [14]	2000	14	CT	ESC
Tosun et al.[3]	2001	14,15	CT	ESC
Lessa et al.[15]	2002	8	CT	ESC
Lim et al.[11]	2004	3 years 8 months	CT and MR	Spontaneous regression
Ceylan et al.[16]	2006	12	CT	ESC
Yasar et al.[17]	2007	15	CT	ESC
Tsai et al.[8]	2008	12	CT	ESC
Okbi et al.[1]	2010	7	MR	ESC
Al-Qudah et al.[4]	2010	15	CT	ESC

ESC: endoscopic sinus surgery, ND: Not determined, CT: computerized tomography, MR: Magnetic resonance

As a conclusion, sphenchoanal polyps should be considered in differential diagnosis of pediatric patients with nasal obstruction. Preoperative computerized tomography findings are vital for distinguishing sphenochonal polyp from other choanal polyps for prevention of exploration of the wrong paranasal sinus during surgery. Transnasal endoscopic surgery is the suitable choice of the surgical treatment of sphenchoanal polyps.

## REFERENCES

- [1] Al Okbi H, Jain R, Al-Abri R. Sphenchoanal polyp-surgical review. Int J PediatrOtorhinolaryngol Extra. 2010; 5:99-101.
- [2] Hardy G. The choanal polyp. Ann Otol Rhinol Laryngol. 1957; 66:306-26.
- [3] Tosun F, Yetiser S, Akcam T, Ozkaptan Y. Sphenchoanal polyp: endoscopic surgery. Int J PediatrOtorhinolaryngol. 2001; 58:87-90.

## A Rare Cause of Nasal Obstruction in Pediatric Patient: Sphenchoanal Polyp

- [4] Al-Qudah MA. Sphenchoanal polyp: current diagnosis and management. *Ear Nose Throat J.* 2010; 89:311-7.
- [5] Moore I. Recurring Spheno-choanal polypus in a child. *Proc R Soc Med.* 1919; 12:104-8.
- [6] Ozcan C, Duce MN, Gorur K. Choanal polyp originating from the middle turbinate. *Eur Arch Otorhinolaryngol.* 2004; 261:184-6.
- [7] Dadas B, Yilmaz O, Vural C, Calis AB, Turgut S. Choanal polyp of sphenoidal region. *Eur Arch Otorhinolaryngol.* 2000; 257:379-81.
- [8] Tsai CH, Hsu MC, Liu CM. Sphenchoanal polyp. *Tzu Chi Med J.* 2008; 20:223-6.
- [9] Ozcan C, Zeren H, Talas DU, Kucukoglu M, Gorur K. *Eur Arch Otorhinolaryngol.* 2005; 262:55-60.
- [10] Weissman JL, Tabor EK, Curtin HD. Sphenchoanal polyps: evaluation with CT and MR imaging. *Radiology.* 1991; 178:145-8.
- [11] Lim WK, Sdralis T. Regression of a sphenchoanal polyp in a child. *Laryngoscope.* 2004; 114:903-5.
- [12] Ileri F, Koybasioglu A, Uslu S. Clinical presentation of a sphenchoanal polyp. *Eur Arch Otorhinolaryngol.* 1998; 255:138-9.
- [13] Sethi DS. Isolated sphenoid lesions: diagnosis and management. *Otolaryngol Head Neck Surg.* 1999; 120:730-6.
- [14] Yanagisawa K, Ho SY, Yanagisawa E. Endoscopic view of a sphenchoanal polyp. *Ear Nose Throat J.* 2000; 79:546-8.
- [15] Lessa MM, Voegels RL, Pádua F, Wiikmann C, Romano FR, Butugan O. Sphenchoanal polyp: diagnose and treatment. *Rhinology.* 2002; 40:215-6.
- [16] Ceylan A, Ileri F, Kizil Y, Uslu S, Yilmaz M, Asal K, et al. Endoscopic surgery of sphenchoanal polyp. *Kulak BurunBogazlhtisDerg.* 2006; 16:94-6.
- [17] Yasar M, Yildirim A, Bebek AI, Kunt T. Choanal polyp of sphenoid sinus origin. *Turk Arch Otolaryngol.* 2007; 45:105-7.

**Citation:** Cengiz Özcan, Onur İsmi, Kemal Görür. *A Rare Cause of Nasal Obstruction in Pediatric Patient: Sphenchoanal Polyp.* *Open Journal of Otolaryngology.* 2018; 1(1): 01-04.

**Copyright:** © 2018 Cengiz Özcan, Onur İsmi, Kemal Görür. This is an open access article distributed under the Creative Commons Attribution License, which permits unrestricted use, distribution, and reproduction in any medium, provided the original work is properly cited.