

Safety and Efficacy of Forodesine for a Recurrent Peripheral T-Cell Lymphoma, Not Otherwise Specified with Liver Failure

Naruko Suzuki¹, Junji Hiraga^{1*}, Yusuke Takagi¹, Michihiko Narita², Yoshitoyo Kagami¹

¹Department of Hematology, Toyota Kosei Hospital, Toyota, Japan.

²Department of Pathology, Toyota Kosei Hospital, Toyota, Japan.

j-hiraga@toyota.jaaikosei.or.jp

***Corresponding Author:** Junji Hiraga, Department of Hematology, Toyota Kosei Hospital, 500-1 Ibobara, Josui-cho, Toyota City, 470-0396, Japan.

Abstract

Malignant lymphoma patients complicated with liver dysfunction is known for its difficulty in treatment. Forodesine is a purine nucleoside phosphorylase inhibitor approved in Japan for the treatment of peripheral T-cell lymphoma (PTCL), and its administration in liver failure patients are unknown. We experienced a 72-year-old woman with recurrent PTCL, not otherwise specified (NOS), and severe liver dysfunction caused by nonalcoholic steatohepatitis treated with forodesine. She remained in stable disease for six months by continuing forodesine, and no remarkable adverse effects occurred. Forodesine may be considered for PTCL patients complicated with severe liver dysfunction.

Keywords: peripheral T-cell lymphoma, not otherwise specified (PTCL-NOS), relapse, forodesine, liver failure

INTRODUCTION

Peripheral T-cell lymphoma, not otherwise specified (PTCL-NOS) is a heterogeneous category of aggressive T-cell lymphoma with poor prognosis a 5-year survival rate of 20-30% [1, 2]. In relapsed/refractory PTCL-NOS, several treatment options have been reported and their median overall survival (OS) is about 6 months [3-5]. Forodesine is a purine nucleoside phosphorylase inhibitor inducing apoptosis mainly in T cells, and has been approved in Japan for relapse/refractory PTCL [6, 7]. Forodesine acts on targets as the intact form in vivo and is excreted renally. The toxicity profile and efficacy of forodesine administration in liver failure patients are unknown. We report herein the case of a patient with recurrent PTCL-NOS safely treated using forodesine without serious difficulties despite complicating severe liver dysfunction.

CASE REPORT

A 72 year-old woman with nonalcoholic steatohepatitis was referred to our hospital with abdominal discomfort and cervical lymphadenopathy. PTCL-

NOS was diagnosed by cervical lymph node biopsy. Computed tomography (CT) and positron emission tomography revealed advanced-stage disease. Although findings from the images showed no liver infiltrations, pretreatment findings showed Child B liver dysfunction (total bilirubin of 0.6 mg/dL, albumin of 2.7 g/dL, international normalized ratio of prothrombin time of 1.27, no hepatic encephalopathy and advanced ascites). She received 6 courses of cyclophosphamide, doxorubicin, vincristine, and prednisolone achieving partial response (PR). First progression occurred 12 months later. She then received 8 courses of mogamulizumab, because the original tumor expressed CCchemokine receptor 4 protein. PR was again attained. After 2 years of watchful waiting, she was hospitalized with high fever. Antibiotics proved ineffective, and CT showed recurrent lymphadenopathy. Bone marrow biopsy diagnosed involvement of PTCL-NOS. Pretreatment findings showed severe liver dysfunction (total bilirubin of 2.6 mg/dL, albumin of 2.6 g/dL, international normalized ratio of prothrombin time of 1.6, no hepatic

Safety and Efficacy of Forodesine for a Recurrent Peripheral T-Cell Lymphoma, Not Otherwise Specified with Liver Failure

encephalopathy and advanced ascites). Anti-nuclear antibody and Anti-mitochondrial antibodies were negative. Although Child class C liver cirrhosis was strongly suspected, liver biopsy was not performed due to low platelet count. She was willing to receive chemotherapy and agreed to receive forodesine at 400 mg/day after providing written informed consent. Liver failure was treated concurrently with fresh-frozen plasma, diuretics, lactulose, and oral nutrient according to liver cirrhosis. During 4 consecutive

months of forodesine treatment, grade 3 neutropenia with drug withdrawal for 2 weeks occurred once, platelet count improved and CT showed stable disease and no hepatic adverse events were identified during treatment (Fig. 1A, 1B). Genital herpes was controlled by oral valacyclovir and vidarabine. At 6 months after administering forodesine, new lesions were found on CT and progressive disease was diagnosed (Fig. 2). She chose best supportive care, and died of sepsis.

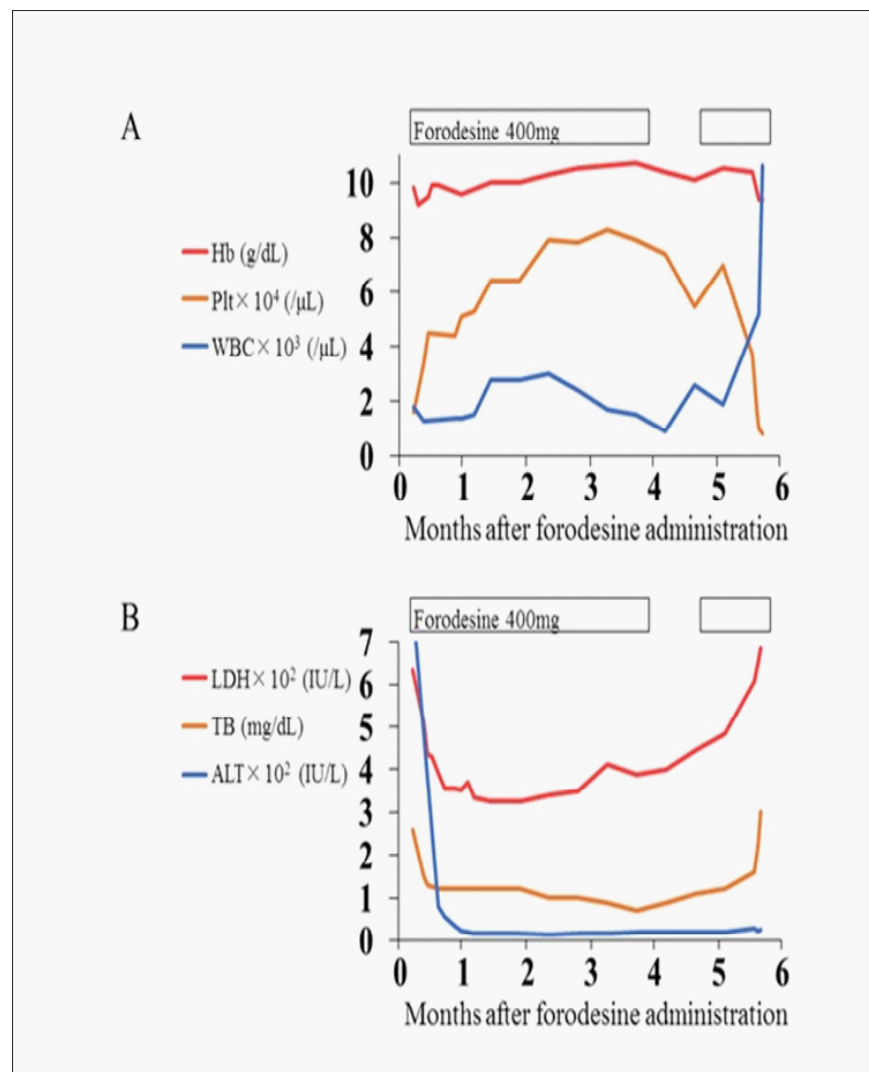


Figure 1.

A) Changes in blood cell counts after administration of forodesine. Administration of forodesine was suspended for administration for 2 weeks because of grade 3 neutropenia. Hb: hemoglobin, Plt: platelet count, WBC: white blood cell count.

B) Transition of liver function tests. ALT: alanine aminotransferase, LDH: lactate dehydrogenase, TB: total bilirubin.

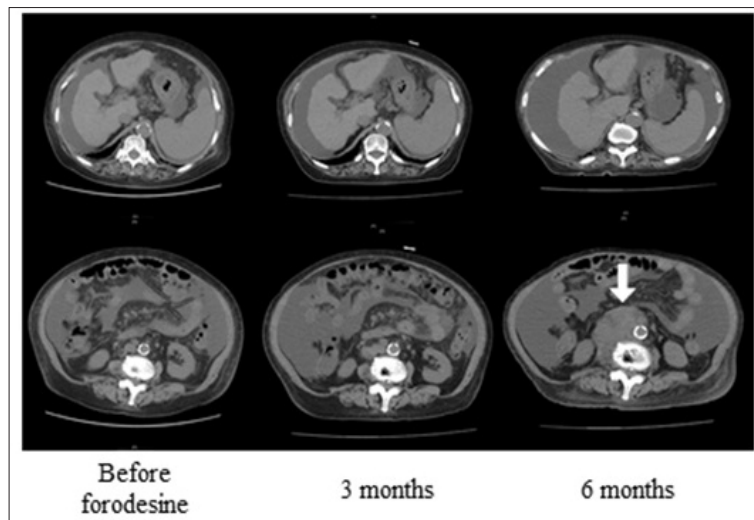


Figure 2. *Computed tomography (CT) of the abdomen. Hepatatrophia, ascites and splenomegaly were confirmed, reflecting liver cirrhosis. Forodesine maintained stable disease for 3 months, with progression at 6 months (arrow).*

DISCUSSION

This report describes the case of a patient with recurrent PTCL-NOS safely treated with forodesine without serious difficulties despite complicating severe liver dysfunction. In this present case, at the start of therapy, the applied dose was reduced to 400 mg/day due to pancytopenia. Recovery of blood count after treatment implies improvement of the suppression caused by bone marrow infiltration. We were not able to perform liver biopsy due to low platelet count. Therefore, the possibility of liver infiltration cannot be excluded. No hepatic adverse events were identified during treatment, and we concluded that forodesine may be safely administered to liver failure patients. A phase I/II study of oral forodesine in patients with relapsed PTCL was recently completed in Japan. In phase 2, overall response rate was 25% (90% confidence interval, 14-38%), including 4 complete responses (10%). Median progression free survival and OS were 1.9 and 15.6 months, respectively [7]. Generally, chemotherapy dosing against a background of complicating liver dysfunction is difficult and numerous factors must be considered. Therapy for liver failure patients is challenging and treatment discontinuations are frequent [8, 9]. In conclusion, forodesine may be considered for PTCL patients complicated with severe liver dysfunction.

REFERENCES

- [1] Foss FM, Zinzani PL, Vose JM, Gascoyne RD, Rosen ST, Tobinai K. Peripheral T-cell Lymphoma. *Blood*. 2011; 117: 6756-6767.
- [2] Pileri SA, Weisenburger DD, Sng I. Peripheral T-cell lymphoma, NOS. In : WHO Classification of Tumours of Haematopoietic and Lymphoid Tissues, 4th ed. Swerdlow SH Ed. IARC, Lyon; 2016. p.403-407.
- [3] Qi F, Dong M, He X, et al. Gemcitabine, dexamethasone, and cisplatin (GDP) as salvage chemotherapy for relapse or refractory peripheral T-cell lymphoma-not otherwise specified. *Ann Hematol*. 2017; 96: 245-251.
- [4] Kim SJ, Kim K, Park Y, et al. Dose modification of alemtuzumab in combination with dexamethasone, cytarabine, and cisplatin in patients with relapsed or refractory peripheral T-cell lymphoma: analysis of efficacy and toxicity. *Invest New Drugs*. 2012; 30: 368-375.
- [5] Hopfinger G, Nösslinger T, Lang A, et al. Lenalidomide in combination with vorinostat and dexamethasone for the treatment of relapse/refractory peripheral T cell lymphoma (PTCL): report of a phase I/II trial. *Ann Hematol*. 2014; 93: 459-462.

Safety and Efficacy of Forodesine for a Recurrent Peripheral T-Cell Lymphoma, Not Otherwise Specified with Liver Failure

- [6] Ogura M, Tsukasaki K, Nagai H, et al. Phase I study of BCX1777 (forodesine) in patients with relapsed or refractory peripheral T/natural killer-cell malignancies. *Cancer Science*. 2016; 103: 1290-1295.
- [7] Maruyama D, Tsukasaki K, Uchida T, et al. Multicenter phase 1/2 study of forodesine in patients with relapsed peripheral T cell lymphoma. *Ann Hematol*. 2019; 98: 131-142.
- [8] Tchambaz L, Schlatter C, Jakob M, Krähenbühl A, Wolf P, Krähenbühl S. Dose adaptation of antineoplastic drugs in patients with liver disease. *Drug Saf*. 2006; 29:509-522.
- [9] Superfin D, Iannucci AA, Davies AM. Commentary: Oncologic drugs in patients with organ dysfunction: a summary. *The Oncologist*. 2007; 12: 1070-1083.

Citation: Naruko Suzuki, Junji Hiraga, Yusuke Takagi, et. al. *Safety and Efficacy of Forodesine for a Recurrent Peripheral T-Cell Lymphoma, Not Otherwise Specified with Liver Failure. Archives of Hematology and Blood Diseases*. 2020; 3(1): 09-12.

Copyright: © 2020 Naruko Suzuki, Junji Hiraga, Yusuke Takagi, et. al. This is an open access article distributed under the Creative Commons Attribution License, which permits unrestricted use, distribution, and reproduction in any medium, provided the original work is properly cited.