

## Renal Biopsy in the Elderly in Senegal: Indications and Outcomes

Ahmed Tall Lemrabott<sup>1\*</sup>, Mame Selly Diawara<sup>1</sup>, Maria Faye<sup>1</sup>, Moustapha Faye<sup>1</sup>, Yaya Kane<sup>2</sup>,  
Mouhamadou Moustapha Cissé<sup>1</sup>, Khodia Fall<sup>1</sup>, Sidi Mohamed Seck<sup>3</sup>, Alex Ismaël Keita<sup>1</sup>,  
Mansour Mbengue<sup>1</sup>, Niakhaleen Keita<sup>1</sup>, Bacary Ba<sup>1</sup>, Seynabou Diagne<sup>1</sup>, Cherif Mohamed Dial<sup>4</sup>,  
Abdou Niang<sup>1</sup>, Boucar Diouf<sup>1</sup>, El Hadji Fary Ka<sup>1</sup>

<sup>1</sup>Nephrology Department, Aristide Le Dantec University Hospital, Dakar, Senegal.

<sup>2</sup>Internal Medicine and Nephrology, AssaneSeck University, Ziguinchor, Senegal.

<sup>3</sup>Internal Medicine and Nephrology, Gaston Berger University, Saint-Louis, Senegal.

<sup>4</sup>Anatomocytology laboratory, Grand-Yoff General Hospital, Dakar, Senegal.

ahmedtall35@hotmail.com

**\*Corresponding Author:** Ahmed Tall Lemrabott, Nephrology Department, Aristide Le Dantec University Hospital 30, avenue Pasteur, Dakar, Senegal.

### Abstract

**Introduction:** Renal biopsy (RB) is poorly performed in sub-Saharan Africa. It is even less practiced in the elderly. The objective of this study was to determine the indications of RB in the elderly and to describe the histopathological aspects of nephropathies of this age group.

**Patients and methods:** This is a descriptive retrospective cohort study over a 5-year period (1<sup>st</sup> January, 2011 to 31<sup>st</sup> December, 2015). Patients older than 60 years who had RB during the study period were included. This RB had to be cortical and contain at least 10 glomeruli. All RB were echoguided.

**Results:** Of the five hundred and ninety-nine (599) RBs performed, one hundred and five (105) were performed in elderly subjects, for a hospital prevalence of 17%. Only 75 had an interpretable histology. The mean age of the patients was 66.5±5.03 years old. With a sex ratio of 2.4. Nephrotic syndrome was the main indication in 26.7% of cases. Glomerular lesions accounted for 63% of cases, tubulointerstitial lesions 5.2%, vascular lesions 25.36% and unclassified lesions 6.5%. Among the 47 glomerular lesions, there were 13 cases (27.65%) of membranous nephropathy (MN), 12 cases (25.53%) of focal segmental glomerulosclerosis (FSGS), 5 cases (10.63%) of amyloidosis, 4 cases (8.51%) of minimal change disease (MCD), 3 cases (6.38%) of extracapillary glomerulonephritis (EGN), a case (2.12%) of membranoproliferative glomerulonephritis (MPGN) and a case (2.12%) of endocapillary glomerulonephritis.

**Conclusion:** Our data, similarly to the literature worldwide, shows that MN is the most found lesion in the elderly.

**Keywords:** renal biopsy, elderly, membranous nephropathy, amyloidosis, Senegal.

### INTRODUCTION

Renal biopsy (RB) consists of taking a fragment of the renal parenchyma for histopathological examination. It is a fundamental examination in nephrological practice due to its triple interest: diagnostic, therapeutic and prognostic [1]. In addition, for the elderly subject characterised by the existence of multiple defects, RB is often necessary to clarify a clinical situation

sometimes confused with comorbidities. Around the world, several studies have focused on RB of the elderly [2,19]. The most common lesion is membranous nephropathy (MN) [20].

Little data is available on this topic in sub-Saharan Africa. This is how we are interested in kidney biopsy of the elderly. The objectives of the study were to clarify the indications of the renal biopsy, to characterise the

## Renal Biopsy in the Elderly in Senegal: Indications and Outcomes

types of histological lesions found and to identify their causes.

### PATIENTS AND METHODS

This is a descriptive retrospective study over a five-year period (1st January 2011 to 31st December 2015). We included patients aged 60 years and older who had RB during the study period with cortical histological section and containing at least 10 glomeruli. Not including non-interpretable biopsies. All biopsies were ultrasound-guided and performed under local anaesthesia with injectable lidocaine 20 mg/ml. The RBs were used until April 2013 using Silverman 18G and 16G needles. After this year the Magnum® BARD automatic pistol was introduced in the renal biopsy practice in Senegal.

The extracted fragment was fixed in Alcohol-Formalin-Acetic acid (AFA) for optical microscopy (OM) examination and in Michel's fluid for immunofluorescence (IF) study, with using polyclonal antisera against human IgM, IgG, IgA, C3, C1q, lambda and kappa light chains. Electron microscopy (EM) was not performed.

The collection tool was a survey card designed to collect demographic data, indications for RB, and pathology results and causes.

**Table 1.** *Indications of PBR*

Indications	Number	Percentage
Nephrotic syndrome	20	26.66 %
Chronic glomerulonephritis (CGN)	9	12 %
Multiple myeloma associated GNC	6	8 %
CKD of indeterminate cause	5	6.66 %
AKI of indeterminate cause	5	6.66 %
Rapidly progressive glomerulonephritis (RPGN)*	4	5.33 %
Rheumatoid arthritis associated CGN	8	10.66 %
Isolated proteinuria	6	8 %
Suspicion of systemic amyloidosis	5	6.66 %
Unspecified	7	9.33 %
Total	75	100 %

Glomerular damage was predominant. They accounted for 63% (47 cases), followed by vascular involvement 25.36% (19 cases), then

For statistical analysis, the data collected was captured and analysed with SPSS software (Statistical Package for Social Science, version 20.0). The qualitative variables were presented as a percentage and the quantitative variables were presented as an average plus or minus the standard deviation or with a minimum and a maximum.

### RESULTS

During the study period, of the 599 RBs performed, 105 were performed in the elderly, representing 17.5% of all RBs. Only 75 of these had led to a precise histological diagnosis, ie 71.42% of interpretable histological slides.

The mean age of the patients was  $66.50 \pm 5.03$  years with extremes of 60 years and 80 years. There were 53 (70.7%) men for 22 (29.3%) women, a sex ratio of 2:40.

The average number of biopsies per year for this population was 15 with extremes of 7 and 22 biopsies per year.

Nephrotic syndrome was the first indication with 26.66% of cases followed by chronic glomerulonephritis (CGN) at the stage of chronic kidney disease (CKD) in 12% (Table I).

unclassified nephropathies 6.50% (5 cases) and tubulointerstitial involvement 5.2% (4 cases) (Figure 1)).

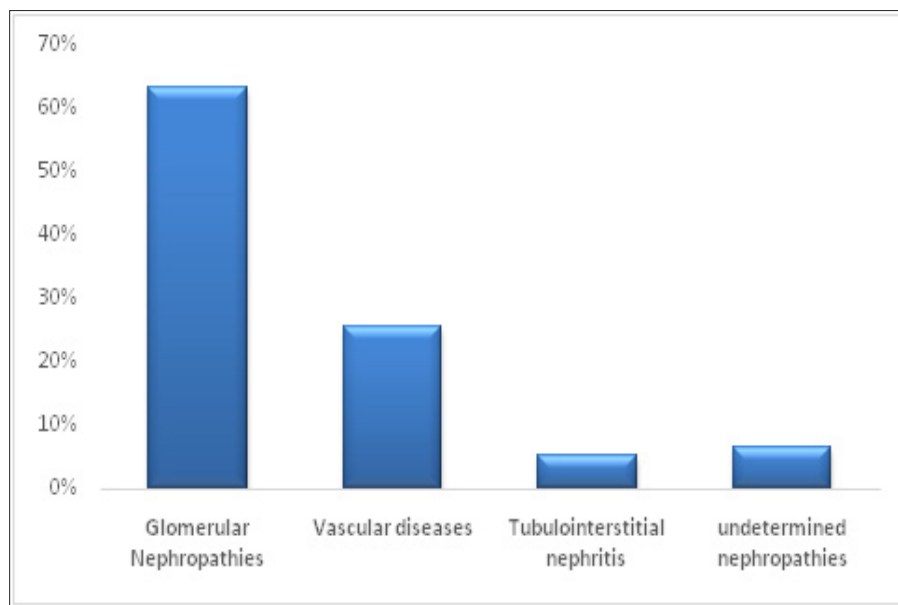


Fig 1. Distribution of nephropathies

The glomerular nephropathies were divided into 13 cases of membranous nephropathy (MN) (27.65%), 12 cases of focal segmental glomerulosclerosis (FSGS) (25.53%), 4 cases of minimal change disease (MCD) (8.51%), 1 case of membranoproliferative glomerulonephritis (MPGN) (2.12%), 3 cases of extracapillary glomerulonephritis (EGN) (6.38%), 5

cases of amyloidosis (10.63%), 1 case of endocapillary glomerulonephritis (2.12%), 3 cases of renal monoclonal immunoglobulin deposition disease (MIDD) or Randall-type MIDD (6.38%) and 5 cases of diabetic nephropathy (10.63%).

These glomerular disorders were either of primary or secondary origin (Table II).

Table 2. Distribution of 47 glomerular nephropathies (63% of cases)

Lesions			Primary		Secondary		Causes
Type	Number	%	Number	%	Number	%	
MN	13	27.65	7	53.84	6	46.15%	Cancer (4 cases), Lupus (1 case)
FSGS	12	25.53	10	83.33	2	16.66	HIV (1 case), Sickle cell disease (1 case)
MCD	4	8.51	3	75	1	25	Lymphoma (1case)
MPGN	1	2.12	1	100	0	0	-
EGN	3	6.38	0	0	3	100	ANCA Vasculitis
Endocapillary GN	1	2.12	0	0	1	100	Malaria
Amyloidosis	5	10.63	3	60	2	40	Tuberculosis (1 case), Myeloma (1 case)
MIDD (3 cases, 6.38%)							
Diabetic nephropathy (5 cases, 10.63%)							

The tubulo-interstitial nephropathies (5.2%) were divided into 3 cases of acute interstitial nephritis (AIN) and 1 case chronic tubulointerstitial nephritis (CTIN).

Vascular nephropathies were found in 19 cases (25.3%). Five patients had thrombotic microangiopathy (TMA) and 12 patients had nephroangiosclerosis (NAS). Two patients had an association of MAT and NAS.

### DISCUSSION

RB is increasingly practiced among the elderly in Senegal (17.5% of all the RB). In the literature in the West, the percentage varies between 13-20% [8], this may be related to a larger ageing population in these countries. The mean age of the patients was  $66.50 \pm 5.03$  years old with extremes of 60 years old and 80 years old. This result was similar to those of Dantas M, in Brazil ( $67.3 \pm 6.5$  years) [22] and Saidani M, (64 years) [23] in Algeria.

In our study, the main indication of RB was nephrotic syndrome with 26.66%. This is in line with recently published cohorts. Indeed, data from 16 studies [21] showed that the 2 most common indications for RB in the elderly were acute kidney injury (12% [10] to 73% [7]) and nephrotic syndrome (13% [11] at 68% [10]).

Membranous nephropathy is one of the most common causes of the nephrotic syndrome in adults. It is the most common primary histological lesion in our series (17.3%) followed by FSGS (16%). This finding was mentioned in another African study, where MN was also the most found lesion in 14.4% of cases [17].

In the Spanish registry, amyloidosis was the first lesion in an RB registry in subjects over 85 years of age [15]. In our series, she was in 3rd place.

There is a great variability in the histological lesions found in the elderly [11, 12]. However, in a recent analysis of global registries [21], MN is still the first lesion found in older people. Because this lesion is often of paraneoplastic origin. And there is still a strong association between cancer and this population.

Tubulo interstitial nephropathies were poorly represented (5.2% of cases), contrary to the finding in some series where they are extremely common in the elderly [13, 3, 7, 19]. Moreover, in a retrospective study done in western France [8], tubulointerstitial nephritis was the most common lesion (23%).

Vascular nephropathies accounted for 25.3% of the histological lesions in our series. This percentage was higher than that reported in France by Pinçon 12% [8]. This is because HTN is a major public health problem in Senegal. Indeed, its prevalence is 24% in the 2015 STEPS survey [24].

With respect to the causes of secondary nephropathies, hypertension was at the forefront of our cohort. In

the literature, diabetes, secondary amyloidosis and cancers were more common [15], [17].

### CONCLUSION

Our data, similarly to the literature worldwide, shows that MN is the most commonly found lesion in the elderly. Histology for this age group is often needed to clarify a clinical situation, which is sometimes confused with comorbidities and this may help to adopt an appropriate therapeutic strategy.

### ACKNOWLEDGEMENTS

Our sincere thanks to Pathology Laboratory of Grand-Yoff General Hospital, Dakar, Senegal.

### REFERENCES

- [1] Hogan JJ, Mocanu M, BernsJS: The native kidney biopsy: update and evidence for best practice. *Clin J Am Soc Nephrol* 2015; pii: CJN.05750515.
- [2] Mohamed N, John R: Use of renal biopsy in the elderly. *Int Urol Nephrol* 2011; 43: 593–600.
- [3] Brown CM, Scheven L, O’Kelly P, Dorman AM, WalsheJJ: Renal histology in the elderly: indications and outcomes. *J Nephrol* 2012; 25: 240–244.
- [4] de Oliveira CM, Costa RS, Vieira Neto OM, et al: Renal diseases in the elderly under went to percutaneous biopsy of native kidneys. *J Bras Nefrol* 2010; 32: 379–385.
- [5] Bolignano D, Mattace-Raso F, Sijbrands EJ, ZoccaliC: The aging kidney revisited: asystematic review. *Ageing ResRev* 2014; 14: 65–80.
- [6] Dhaun N, Bellamy CO, Cattran DC, KluthDC: Utility of renal biopsy in the clinical management of renal disease. *Kidney Int* 2014; 85: 1039–1048.
- [7] Kohli HS, Jairam A, Bhat A, et al: Safety of kidney biopsy in elderly: a prospective study. *Int Urol Nephrol* 2006; 38: 815–820.
- [8] Pinçon E, Rioux-Leclercq N, Frouget T, Le Pogamp P, Vigneau C: Renal biopsies after 70 years of age: a retrospective longitudinal study from 2000 to 2007 on 150 patients in Western France. *Arch Gerontol Geriatr* 2010; 51: e120–e124.
- [9] Di Palma AM, d’Apollo AM, Vendemia F, Stallone G, Infante B, Gesualdo L: Kidney biopsy in the elderly. *J Nephrol* 2010; 23 (suppl 15): S55–S60.

## Renal Biopsy in the Elderly in Senegal: Indications and Outcomes

- [10] Moulin B, Dhib M, Sommervogel C, Dubois D, Godin M, Fillastre JP: [Value of renal biopsy in the elderly. 32 cases]. *Presse Med* 1991; 20: 1881–1885.
- [11] Moutzouris DA, Herlitz L, Appel GB, et al: Renal biopsy in the very elderly. *Clin J Am Soc Nephrol* 2009; 4: 1073–1082.
- [12] Nair R, Bell JM, Walker PD: Renal biopsy in patients aged 80 years and older. *Am J Kidney Dis* 2004; 44: 618–626.
- [13] Haas M, Spargo BH, Wit EJ, Meehan SM: Etiologies and outcome of acute renal insufficiency in older adults: a renal biopsy study of 259 cases. *Am J Kidney Dis* 2000; 35: 433–447.
- [14] Yokoyama H, Sugiyama H, Sato H, et al: Renal disease in the elderly and the very elderly Japanese: analysis of the Japan Renal Biopsy Registry (J-RBR). *Clin Exp Nephrol* 2012; 16: 903–920.
- [15] Omokawa A, Komatsuda A, Nara M, et al: Renal biopsy in patients aged 80 years and older: a single-center experience in Japan. *Clin Nephrol* 2012; 77: 461–467.
- [16] Verde E, Quiroga B, Rivera F, Lopez-Gomez JM: Renal biopsy in very elderly patients: data from the Spanish registry of glomerulonephritis. *Am J Nephrol* 2012; 35: 230–237.
- [17] Okpechi IG, Ayodele OE, Rayner BL, Swanepoel CR: Kidney disease in elderly South Africans. *Clin Nephrol* 2013; 79: 269–276.
- [18] Ferro G, Dattolo P, Nigrelli S, Michelassi S, Pizzarelli F: Clinical pathological correlates of renal biopsy in elderly patients. *Clin Nephrol* 2006; 65: 243–247.
- [19] Heras M, Saiz A, Sanchez R, et al: [Renal biopsy in patients aged 65 years or older: are there differences in the indication and histopathology compared to other patients?]. *Rev Esp Geriatr Gerontol* 2010; 45: 316–319.
- [20] Mbakop A, Chatelana F: [Renal puncture biopsy in the aged subject: apropos of 119 cases]. *Ann Pathol* 1985; 5: 101–105.
- [21] Fiorentino M, Bolignano D, Tesar V, Pisano A, et al. Epidemiology and Indications for Renal Biopsy. *Am J Nephrol* 2016; 43: 1–19.
- [22] Dantas RAS, Oleviera MJ, Costa RS. Renal diseases in the elderly under went to percutaneous biopsy of native kidneys. *J Bras Nefrol* 2010; 32 (4): 379-385.
- [23] Saidani M, Bahamida B. Ponction biopsie rénale du sujet âgé: quelles indications et quels bénéfices? *Nephrol Ther* 2012 ; 8: 364-365.
- [24] ANSD. available on « [www.ansd.sn/ressources/publications/DV-STEPS-1-06-2016%20-%20MF-fin\\_ANSD%20vf.pdf](http://www.ansd.sn/ressources/publications/DV-STEPS-1-06-2016%20-%20MF-fin_ANSD%20vf.pdf) »

**Citation:** Ahmed Tall Lemrabott, Mame Selly Diawara, Maria Faye, et al. *Renal Biopsy in the Elderly in Senegal: Indications and Outcomes. Archives of Nephrology. 2019; 2 (1): 39-43.*

**Copyright:** © 2019 Ahmed Tall Lemrabott, Mame Selly Diawara, Maria Faye, et al. *This is an open access article distributed under the Creative Commons Attribution License, which permits unrestricted use, distribution, and reproduction in any medium, provided the original work is properly cited.*