

## Imaging Findings in Inflamed Meckel's Diverticulum

Dr. Shwetang Solanki, Dr. Kruti Dave

Shalby Hospital & AIMS hospital, Ahmedabad, Gujarat, India.

dave.kruti@gmail.com

*\*Corresponding Author: Dr. Shwetang Solanki, Shalby Hospital & AIMS hospital, Ahmedabad, Gujarat, India.*

### Abstract

Meckel's diverticulum is congenital abnormality of gastrointestinal tract. It is generally accepted that the radiological demonstration of a Meckel's diverticulum is not practicable. But when there is associated complications with Meckel's diverticulum it becomes relatively easy. Abdominal radiograph does not provide any information but USG and CT features are helpful in diagnosing however the single most accurate diagnostic test for a Meckel's diverticulum is scintigraphy.

### INTRODUCTION

Meckel's diverticulum is congenital abnormality of gastrointestinal tract. Appearance on imaging is variable and non specific. It is generally accepted that the radiological demonstration of a Meckel's diverticulum is not practicable.<sup>1</sup>

- Caffey (1945) states that *"it cannot be satisfactorily demonstrated roentgenographically"*
- Potts (1948) wrote *"roentgenologic examination is valueless except in those very rare instances in which barium is given by mouth and by rare good fortune a film happened to be taken at the right time to show an accumulation in the diverticulum."*

*I have never had the good fortune to see one demonstrated Roentgenographically".*

### CASE REPORT

6 years old boy presented with pain in periumbilical region of abdomen associated with 7-8 episodes of vomiting and constipation since 4 days. Intermittent fever since 2 days. Per abdominal examination guarding with right iliac fossa tenderness. On auscultation absent bowel sounds was noted.

Laboratory results showed raised leucocyte count and which was 13,000, Hb 12.5 gm/dl.

Plain abdominal radiograph (Fig. 1) showed multiple loops filled with gas but non specific diagnostic features with no obvious signs of intestinal obstruction.

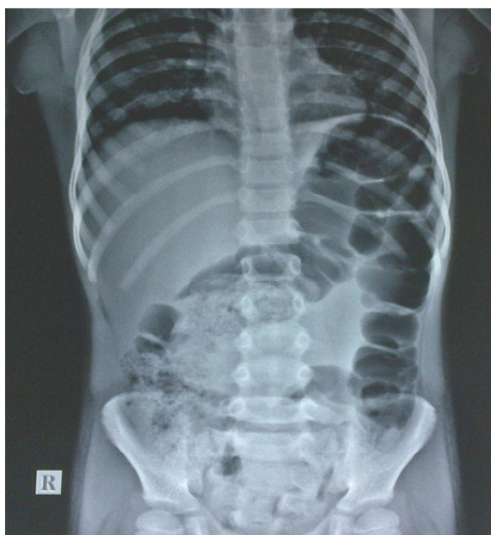
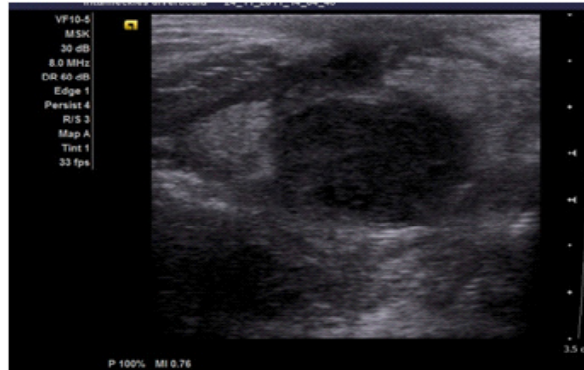


Fig 1. Erect abdominal radiograph

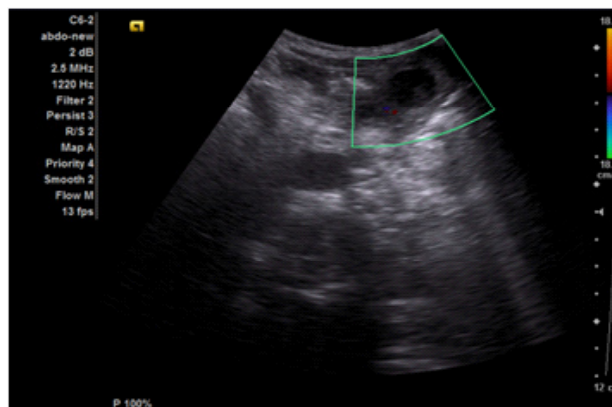
## Imaging Findings in Inflamed Meckel's Diverticulum

Abdominal Ultrasonography was carried out on Siemen's Acuson X300 machine. It revealed abnormal hypoechoic cystic swelling seen superficially near anterior abdominal wall close to umbilicus (Fig. 2). It measures 3 X 2.5 cm in size with soft echoes within it. Pericystic lesion reveals fat stranding suggestive of chronic inflammation.



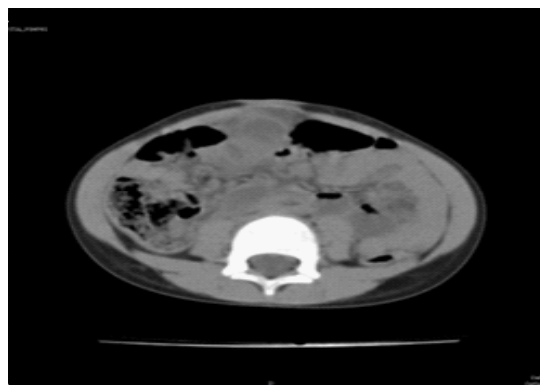
**Fig 2.** Ultrasonographic image in transverse plane at right peri umbilical region

This cystic structure is attached to small bowel loop which is dilated and shows no peristalsis. (Fig. 3) Minimal free fluid is seen in the pelvis. Marked probe tenderness is noted at cystic lesion.

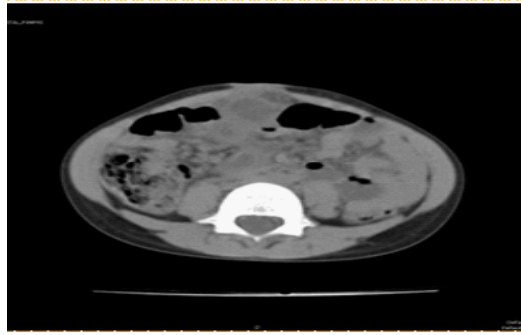


**Fig 3.** Ultrasonographic image in longitudinal plane at right peri umbilical region

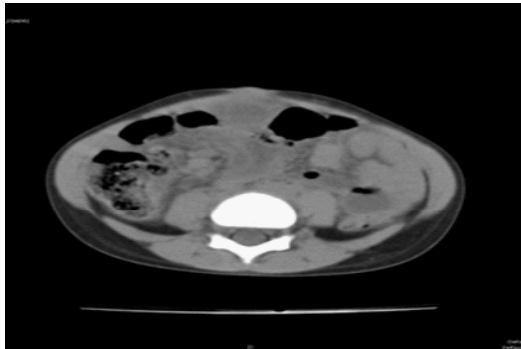
CT performed on GE duo FII scanner without oral and intravenous contrast. Abnormal cystic lesion noted in right periumbilical region which is abutting the anterior abdominal wall merging with adjacent to small bowel loop (Fig. 5 and 6). This loop contains fluid within it with stranding of mesenteric fat (Fig. 4). No pneumoperitoneum, no intestinal obstruction seen.



**Fig 4.** Axial CT image revealing hypodense lesion

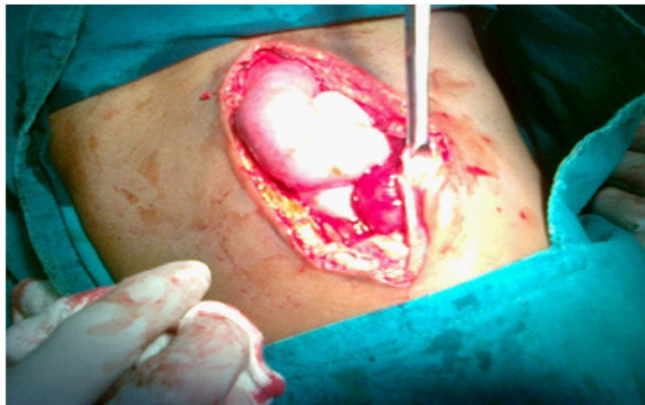

**Fig 5.** Axial CT image revealing hypodense lesion abutting anterior abdominal wall

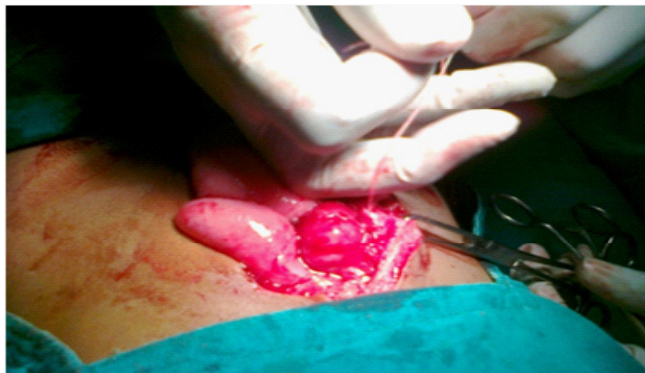

**Fig 6.** Axial CT image revealing hypodense lesion in close approximation with bowel loops

An inflamed Meckel's diverticulum was excised at laparotomy.



**Fig 7.** Intraoperative image revealing diverticulum like mass which is attached to anterior abdominal wall



**Fig 8.** Intraoperative image showing Meckel's diverticulum

## Imaging Findings in Inflamed Meckel's Diverticulum

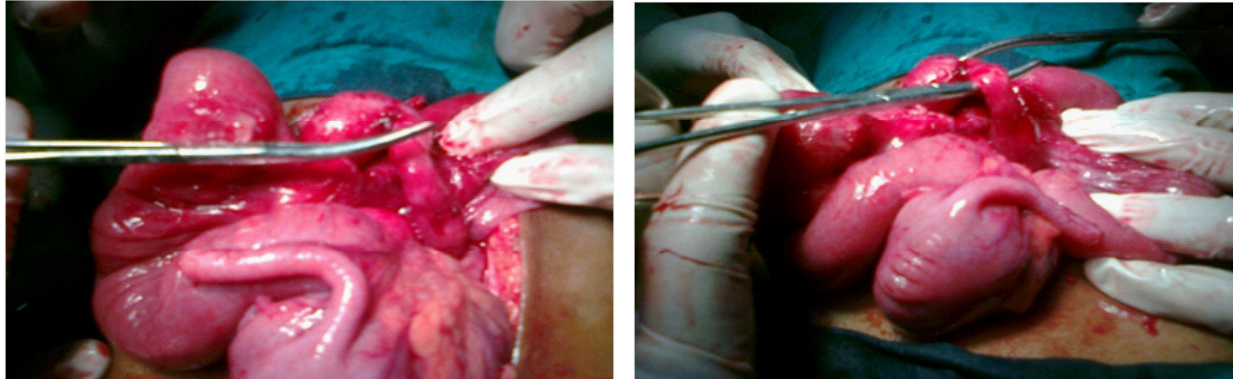


Fig 9, 10. intraoperative image revealing Meckel's diverticulum with fibrous septa extending to small bowel loops

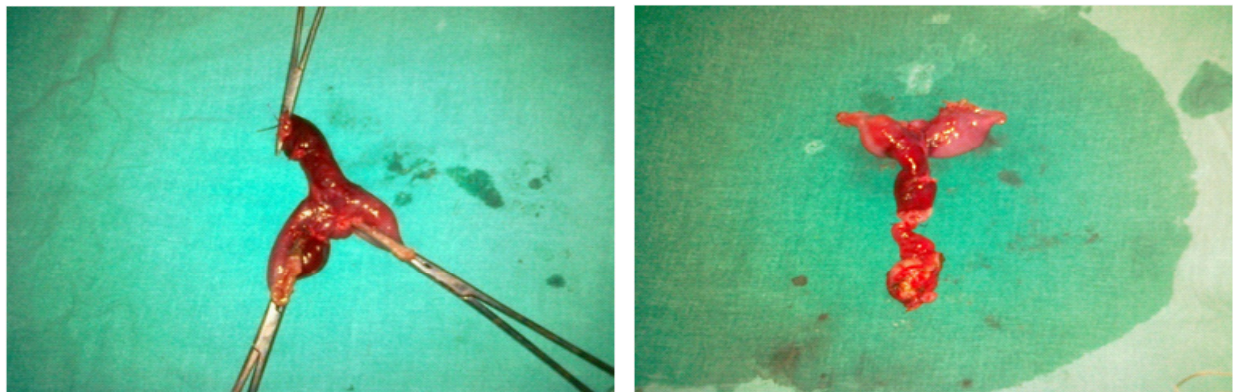


Fig 11, 12. post-operative image of specimen of Meckel's diverticulum

## DISCUSSION

Meckel diverticulum is the consequences of incomplete regression of omphalomesenteric duct. The omphalomesenteric duct in the embryo serves as a communication between the gut and the yolk sac. Obliteration of the duct occurs gradually between the fifth and seventh week, as placental nutrition becomes established. The duct may persist as a fistula between

the small bowel and the abdominal wall (Fig. 13 A), as a fibrous cord connecting the small bowel with the abdominal wall (Fig. 13 B), as a Meckel's diverticulum (Fig. 13C), or as an umbilical sinus (Fig. 13 D). Meckel's diverticulum opens into the antimesenteric side of the small intestine. This is a differential feature from duplications of small bowel which arise on the mesenteric side of the small intestine.<sup>2</sup>

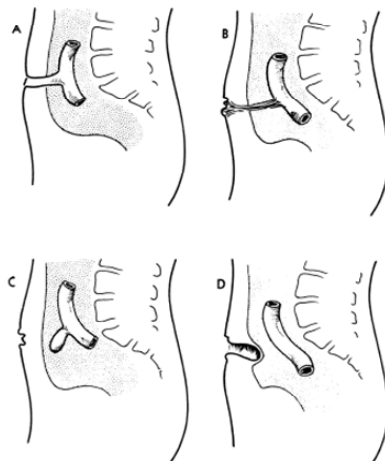


Fig 13. Omphalomesenteric duct abnormalities.

(A) Persistent duct (B) Fibrous cord remnant (C) Meckel's diverticulum (D) Umbilical sinus

### CLINICAL PRESENTATION

Meckel's diverticulum can cause symptoms at any age; however, about 50 per cent of the patients come to the hospital in the first 2 years of life.<sup>2</sup>

Complications of Meckel's diverticulum develop in approximately 2.5 per cent of the cases and include inflammation, peptic ulceration with hemorrhage on perforation, intussusception, and volvulus about the fibrous cord. Neoplasia have also been reported.<sup>3</sup>

Patients with Meckel's diverticulum may have different symptoms. Gastrointestinal bleeding secondary to peptic ulceration is the most common. The bleeding is copious and usually not accompanied by abdominal pain. The stool may at first be dark or black, but subsequently is bright red. Abdominal pain is the second most common clinical presentation and may be second any to Meckel's diverticulitis, sealed off perforation with abscess formation, on recurrent intussusceptions with spontaneous reductions. Small bowel obstruction is caused by intussusception, volvulus, mechanical obstruction about a persistent cord, or internal hernia through the mesentery of a Meckel's diverticulum.<sup>4</sup> Perforation of a diverticulum has also been reported following blunt abdominal trauma, on penetration of a foreign body—most commonly fishbones—through the wall of the diverticulum.<sup>5</sup>

Carcinoid tumors within a Meckel's diverticulum have been associated with the carcinoid syndrome.<sup>5</sup>

### COMPLICATIONS AND PATHOLOGY

Meckel's diverticulum assumes importance chiefly through its liability to various complications, and these have been described between the ages of five hours and 77 years.

1. *Acute inflammation.* This may lead to local abscess formation, gangrene, perforation and peritonitis.
2. *Acute intestinal obstruction* may occur, following strangulation of the bowel by a fibrous or vascular cord from the sac to the umbilicus. Sometimes the tip of the sac is adherent to some other viscus and traps the intestines. If there is twisting of the bowel, volvulus may occur.
3. *Intussusception* caused by an invaginated diverticulum is well recognized, and is said to cause between 2.5 to 5 per cent of all intussusceptions.

This is said to be commoner in children between 3 and 12 years.

4. *Haemorrhage* is a frequent finding: this is usually the result of a peptic ulcer, often chronic, in the secreting gastric mucosa, and a small eroded artery in this region.
5. *New growths* are rare, but many different types are recognised. Of benign tumours, lipoma, myoma, neuroma, papilloma, carcinoid tumour, leiomyoma and argentaffin tumours.
6. *Tuberculosis* of a Meckel's diverticulum, with perforation and generalised peritonitis is recorded *Region ileitis* affecting the diverticulum.
7. In a review of foreign body perforations of the diverticulum, majority are caused by fish bones.
8. *Miscellaneous.* Intra-uterine perforation into the bladder, forming a fistula. Perforation of a diverticulum, presenting as a unilateral hydrocele, acute diverticulitis with round worms in the peritoneal cavity, a Meckel's diverticulum appendiceal fistula and calcium carbonate faecoliths

### IMAGING DIAGNOSIS

Diagnosis of Meckel's diverticulum radiologically may be difficult.<sup>6</sup>

### PLAIN ABDOMINAL RADIOGRAPHS

Plain abdominal radiographs may reveal nonspecific signs of intestinal obstruction.<sup>6</sup> Inflammation in a Meckel's diverticulum, unlike appendicitis, rarely produces gas and fluid levels in the cecum. A rare nonspecific sign is the association of enteroliths within the diverticulum and air-fluid levels.<sup>6</sup>

### BARIUM STUDIES

The conventional small-bowel series has often been considered unreliable for the detection of Meckel's diverticulum because the technique has some inherent limitations. The diverticulum can occasionally be diagnosed by reflux of barium during a colon enema; however, the colon barium enema is not used as a primary imaging method to make the diagnosis of Meckel's diverticulum.<sup>7,11</sup>

**Enteroclysis** is considered by some authors a better technique than the conventional barium follow-through studies in diagnosing small bowel disease

## Imaging Findings in Inflamed Meckel's Diverticulum

and Meckel's diverticulum.<sup>7</sup> With this technique, it is possible to obtain consistent, moderate distension of bowel segments that are suspected to be abnormal. The confirmation of the Meckel origin of the diverticulum rests on the visualization of its fold patterns, especially at the site of its attachment to the normal intestine. A "triradiate" fold pattern in which the loops are collapsed, and a "mucosal triangular plateau" in which the loops are distended, are the junctional fold appearances that are considered characteristic. A gastric rugal pattern may also be identified within the diverticulum.<sup>7</sup>

### SONOGRAPHY

Meckel's diverticulum can be identified on sonography in cases of complications. In cases of an obstructed and fluid-filled diverticulum, sonography may show a tubular overdilated fluid structure connected to the umbilicus.<sup>8</sup>

CT is usually of little value in diagnosing Meckel's diverticulum because distinction between a diverticulum and intestinal loops is usually impossible. If the diverticulum is attached to the umbilicus, the diagnosis may be suspected on CT scans.<sup>9,10</sup>

### NUCLEAR MEDICINE

Radionuclide scans may provide a diagnosis of Meckel's diverticulum when uptake of radionuclide occurs in ectopic gastric mucosa or by identifying the site of gastrointestinal bleeding.<sup>99mTc</sup>perchnetate is preferentially taken up by the mucus-secreting cells of gastric mucosa and ectopic gastric tissue in the diverticulum.<sup>13</sup>

### ANGIOGRAPHY

In patients with Meckel's diverticulum, arteriography is usually indicated when there is active bleeding in the gastrointestinal tract, or in episodes of self-limiting bleeding, after scintigraphy and enteroclysis show normal findings. Bleeding at a rate of at least 0.5 ml/min is generally required in adults to demonstrate contrast extravasation; a greater rate of bleeding may be necessary to detect this finding in children.<sup>10</sup> The angiographic diagnosis is based on visualization of an anomalous artery feeding the diverticulum, the presence of dense capillary staining, and extravasation of contrast material in actively bleeding patients. Selective superior mesenteric arteriography can be

done. The arterial, capillary, and venous phases and the mucosal blush must be accurately studied.

### CONCLUSION

Imaging based diagnosis of Meckel's diverticulum is difficult. However when there is associated complications it becomes relatively easy. USG and CT are helpful in diagnosing however the single most accurate diagnostic test for a Meckel's diverticulum is scintigraphy with sodium <sup>99mTc</sup> per technetate which has the advantage of being noninvasive.

### REFERENCES

- [1] Pantongrag-Brown L, Levine MS, Buetow PC, et al. Meckel's enteroliths: clinical, radiologic, and pathologic findings. *AJR Am J Roentgenol.* Dec 1996; 167(6):1447-50.
- [2] Ariga M, Suga K, Matsunaga N, et al. Failure to detect a huge Meckel's diverticulum with abundant ectopic gastric mucosa on gastric mucosal scintigraphy with Tc-99m perchnetate. *Clin Nucl Med.* May 2001;26(5):470-1.
- [3] Ford PV, Bartold SP, Fink-Bennett DM, et al. Procedure guideline for gastrointestinal bleeding and Meckel's diverticulum scintigraphy. Society of Nuclear Medicine. *J Nucl Med.* Jul 1999;40(7):1226-32.
- [4] Groebli Y, Bertin D, Morel P. Meckel's diverticulum in adults: retrospective analysis of 119 cases and historical review. *Eur J Surg.* Jul 2001; 167(7):518-24.
- [5] Hol L, Kuipers EJ. Clinical challenges and images in GI. Meckel's diverticulum. *Gastroenterology.* Aug 2007; 133(2):392, 732.
- [6] Emamian SA, Shalaby-Rana E, Majd M. The spectrum of heterotopic gastric mucosa in children detected by Tc- 99m per technetate scintigraphy. *Clin Nucl Med.* Jun 2001; 26 (6): 529-35.
- [7] Linebarger JS, Roy ML. Focus on diagnosis: common nuclear medicine studies in pediatrics. *Pediatr Rev.* Nov 2007; 28(11):415-7.
- [8] Delle Chiaie L, Neuberger P. Early prenatal sonographic detection of an uncomplicated Meckel diverticulum. *Ultrasound Obstet Gynecol.* Oct 2007; 30(5):790-1.

## Imaging Findings in Inflamed Meckel's Diverticulum

---

- [9] Mitchell AW, Spencer J, Allison DJ, Jackson JE. Meckel's diverticulum: angiographic findings in 16 patients. *AJR Am J Roentgenol*. May 1998; 170(5):1329-33.
- [10] Navarro O, Dugougeat F, Kornecki A, et al. The impact of imaging in the management of intussusception owing to pathologic lead points in children. A review of 43 cases. *Pediatr Radiol*. Sep 2000; 30(9):594-603.
- [11] Nolan DJ. The true yield of the small-intestinal barium study. *Endoscopy*. Aug 1997; 29(6):447-53.
- [12] Omar AM, Al-Sae'd TA, Elgazzar A. Scintigraphic pattern of intestinal duplication on a Meckel's diverticulum scan. *Clin Nucl Med*. Oct 1998; 23(10):708-9.
- [13] Swaniker F, Soldes O, Hirschl RB. The utility of technetium 99m per technetate scintigraphy in the evaluation of patients with Meckel's diverticulum. *J Pediatr Surg*. May 1999; 34(5):760-4; discussion 765.

**Citation:** Dr. Shwetang Solanki, Dr. Kruti Dave. *Imaging Findings in Inflamed Meckel's Diverticulum*. *Archives of Radiology*. 2018; 1(1): 9-15.

**Copyright:** © 2018 Dr. Shwetang Solanki, Dr. Kruti Dave. This is an open access article distributed under the Creative Commons Attribution License, which permits unrestricted use, distribution, and reproduction in any medium, provided the original work is properly cited.