

Choroidal Detachment Following Femtosecond Laser Assisted Cataract Surgery : A Case Report

Dr. Prasanth Gireesh^{*1}, Dr. R. Venkatesh², Dr. Bharath Gurani³, Dr. Kirandeep Karur⁴,
Dr. Ashish Khodifad⁵

¹MS, Consultant Cataract and IOL services, Aravind eye hospital, Pondicherry, India, 605007.

²DO, DNB, CMO, Glaucoma services, Aravind eye hospital, Pondicherry, India, 605007.

³DNB, Cornea fellow, Aravind eye hospital, Pondicherry, India, 605007.

⁴DNB, Pediatric fellow, Aravind eye hospital, Pondicherry, India, 605007.

⁵DO, DNB, Retina fellow, Aravind eye hospital, Pondicherry, India, 605007.

mavric77@gmail.com

***Corresponding Author:** Dr. Prasanth Gireesh, MS, Consultant Cataract and IOL services, Aravind eye hospital, Pondicherry, India, 605007

Abstract

Femtosecond laser assisted cataract surgery (FLACS) is a novel technology for cataract surgery. There have been reports and studies regarding the various complications of FLACS. The commonly reported complications of FLACS include suction loss, capsular block, incomplete capsulotomy, pupillary miosis and vitreous loss. We report a case of serous choroidal detachment following FLACS with phacoemulsification and toric foldable intraocular lens. The choroidal detachment (CD) resolved after 1 week of conservative management. After extensive literature review, as per the best of our knowledge CD has not been reported after FLACS.

INTRODUCTION

Femtosecond laser assisted cataract surgery (FLACS) is an upcoming technology for cataract surgery. Several benefits have been reported including consistent and reproducible capsulotomy, water tight triplanar incisions, ability to correct astigmatism, limited ultrasound energy, less endothelial cell loss, and effective IOL centration¹. However, there have been few reports regarding complications of FLACS. The commonly reported complications include suction loss, capsular block, incomplete capsulotomy, capsular tags and bridges, pupillary miosis and vitreous loss². Choroidal detachment (CD), has been a reported complication following, Intracapsular cataract extraction³, manual small incision cataract surgery⁴, phacoemulsification⁵ and local anaesthesia for cataract surgery⁶. The proposed mechanisms have been hypotony and sudden decompression, intraoperative or postoperatively. We report a case of CD following FLACS.

CASE REPORT

A 69 year old woman with grade 3 nuclear sclerotic cataract in LE underwent FLACS (LenSx, Alcon laboratories) with Aurofoldable toric intraocular lens under topical anaesthesia. Her pre-op best corrected visual acuity (BCVA) was 5/60. She underwent OD cataract surgery many years back without FLACS assistance. She was a known case of diabetes, hypertension and ischemic heart disease for past 5 years and under treatment.

The intraocular pressure (IOP) pre-operatively was 26 mm Hg in OD and 24 mm Hg in OS. Gonioscopy revealed Schaffer's Grade 3 open angles in OU. The central corneal thickness was 603 microns in OD and 593 microns in OS. Fundus examination was within normal limits with cup disc ratio of 0.3 in OU. Axial length was 23.32 mm in LE, recorded by IOL master 700. Pre-operative 30 oral glycerol was advised. Incision was planned at 30 degrees with an IOL power of 22.0D with cylinder at 1.06D @ 175 degrees.

Choroidal Detachment Following Femtosecond Laser Assisted Cataract Surgery : A Case Report

SURGICAL PROCEDURE

The femtosecond laser was performed with the Alcon LenSx system. Docking was done with the soft fit contact lens. The laser procedure went uneventful. Patient underwent phacoemulsification with the Alcon centurion machine. The surgical steps were uneventful. During IOL implantation severe positive pressure was experienced. With a suspicion of Aqueous misdirection syndrome, intravenous mannitol (20%) 100ml was administered on table.

Subsequently IOL was implanted. Homatropine eye drops were instilled and pressure bandage was done.

On post operative day 1, clear cornea with well formed anterior chamber was noted. IOL was in the bag with axis at 180 degrees. Fundus examination with 90 D and indirect ophthalmoscopy showed choroidal detachment along the superior temporal arcade. Fundus, B-scan and OCT images are as shown in figures 1,2,3 and 4

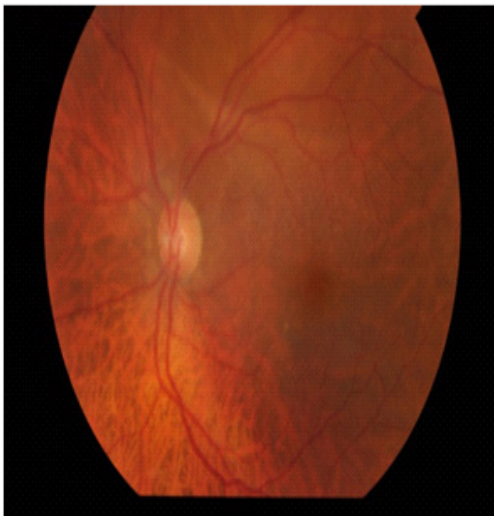

Figure 1

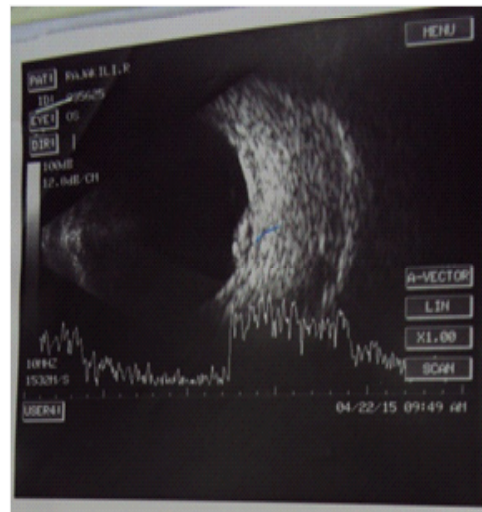


Figure 2

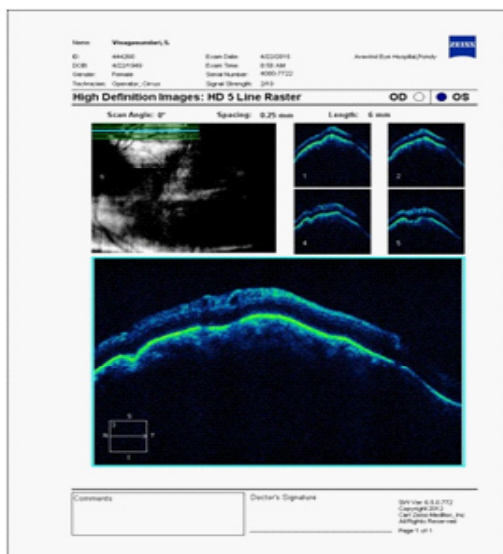


Figure 3

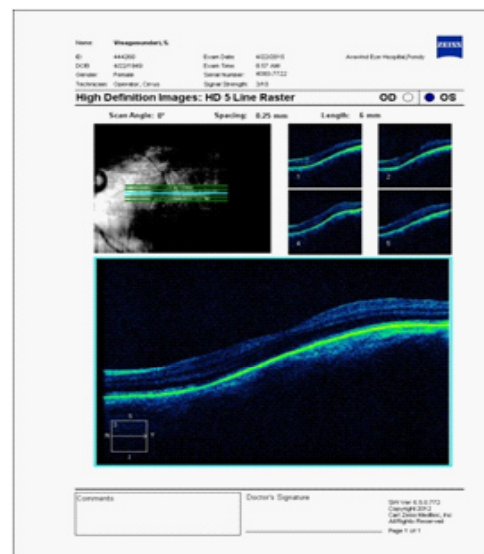


Figure 4

Topical steroids, antibiotics along with cycloplegics were started. Systemic steroid (Tablet Prednisolone (40mg) in tapering dose) was also advised. Patient

was reviewed after 1 week. One week postoperatively, choroidal detachment was seen resolving. (Figure 5,6,7).

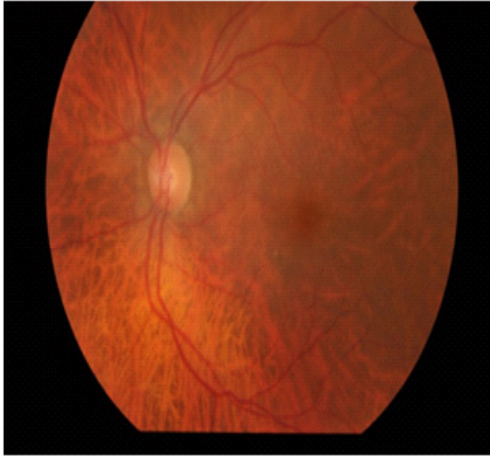


Figure 5

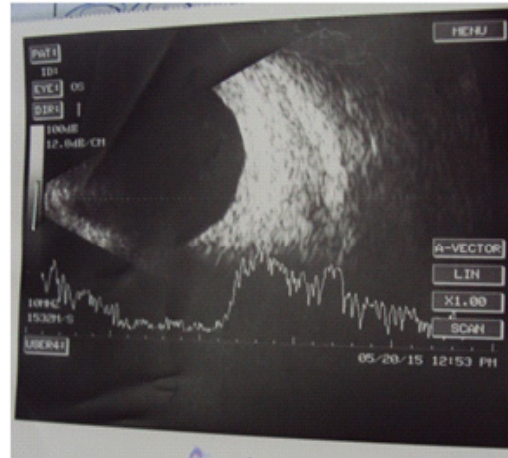


Figure 6

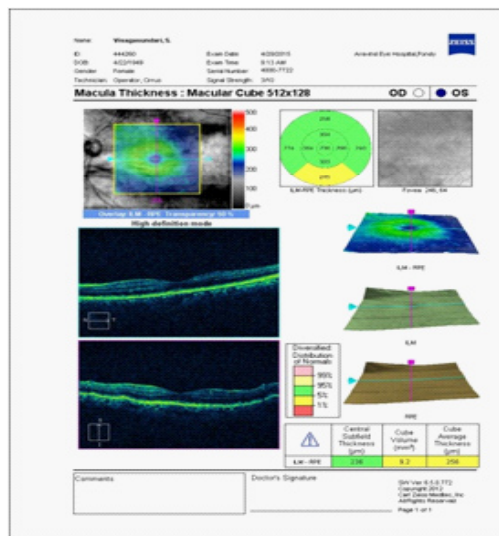


Figure 6

DISCUSSION

Choroidal Detachment has been reported following sub-Tenon's block, uneventful SICS, uneventful Phacoemulsification and YAG Capsulotomy. To the best of our knowledge till date there is no reported case of Choroidal detachment following FLACS.

The possible mechanisms for choroidal detachment include hypotony, sudden decompression, inflammation, mass lesions, nanophthalmos, drugs like acetazolamide, sulphonamides, and uveal effusion syndrome. The commonly reported underlying conditions leading to choroidal detachment following cataract surgery are sudden decompression, hypotony, wound leak, and inflammation⁷. Occurrence of choroidal detachment following local anaesthesia has been associated with increased permeability of choroidal vessels secondary to inflammation⁴.

Our case developed serous choroidal detachment following FLACS. We analysed the possible mechanisms for the same. First, the docking procedure during FLACS is known to cause a raise in IOP by 16 – 20 mmHg⁸. The rapid depressurisation of the eye from the supra-physiological to physiological range, might have caused choroidal detachment⁹. Second, another possible mechanism could be sudden lowering of intraocular pressure following keratome entry into the anterior chamber causing choroidal detachment.

Third, as discussed earlier, we encountered severe positive pressure intraoperatively, most probably due to aqueous misdirection and patient was started on intravenous mannitol on table, to reduce the intraocular pressure. The sudden decrease in pressure following administration of mannitol coupled with an open surgical wound could have caused hypotony and thus choroidal detachment¹⁰.

Choroidal Detachment Following Femtosecond Laser Assisted Cataract Surgery : A Case Report

Fourth, our patient was on tablet acetazolamide, and losartanas antihypertensivepreoperatively. Both the drugs have been reported to cause choroidal detachment post cataract surgery. This could also be a probable cause or a contributory cause in this case.

To conclude we report the first case of choroidal detachment following femtosecond laser assisted surgery in an uncomplicated case. The exact mechanism is difficult to pinpoint. It could have been caused by a single factor or a combination of multiple factors as discussed.

Financial support and sponsorship: Nil

Conflicts of interest: There are no conflicts of interest.

REFERENCES

- [1] Peiqing Chen, Yanan Zhu, and Ke Yao. Descemet membrane detachment in femtosecond laser-assisted cataract surgery: a case report. *BMC Ophthalmol.* 2017; 17: 169.
- [2] Nagy ZZ. Advanced technology IOL-s in cataract surgery: pearls for successful femtosecond cataract surgery. *Int Ophthalmol Clin.* 2012;52:103-114.
- [3] Reddy MK. Complications of cataract surgery. *Indian journal of ophthalmology.* 1995 Oct 1;43(4):201.
- [4] Suto C, Mita S, Hori S. Choroidal detachment after uncomplicated small incision cataract surgery. *Case reports in ophthalmology.* 2012;3(2):175-9.
- [5] LIESEGANG TJ. Cataracts and cataract operations (second of two parts). In *Mayo Clinic Proceedings* 1984 Sep 1 (Vol. 59, No. 9, pp. 622-632). Elsevier.
- [6] Joseph JP, McHugh JD, Franks WA, Chignell AH. Perforation of the globe--a complication of peribulbar anaesthesia. *British journal of ophthalmology.* 1991 Aug 1;75(8):504-5.
- [7] Elagouz M, Stanescu-Segall D, Jackson TL. Uveal effusion syndrome. *Survey of ophthalmology.* 2010 Mar 1;55(2):134-45.
- [8] Phillip et al. Intraocular Pressure Course During the Femtosecond Laser-Assisted Cataract Surgery in Porcine Cadaver Eyes. *Investigative Ophthalmology & Visual Science* December 2017, Vol.58, 6457-6461.
- [9] Tahir Kansu Bozkurt and Kevin M. Miller. Suprachoroidal hemorrhage during femtosecond laser assisted cataract surgery. *Am J Ophthalmol Case Rep.* 2016 Dec; 4: 45-46.
- [10] Mauger TF, Nye CN, Boyle KA. Intraocular pressure, anterior chamber depth and axial length following intravenous mannitol. *J OculPharmacolTher.* 2000 Dec;16(6):591-4.
- [11] Hayashi K, Yoshida M, Manabe SI. Prophylactic Effect of Oral Acetazolamide against Intraocular Pressure Elevation after Cataract Surgery in Eyes with Glaucoma. *Ophthalmology.* 2017 May;124(5):701-708. doi: 10.1016/j.ophtha.2016.12.027. Epub 2017 Jan 19.

Citation: Dr. Prasanth Gireesh, Dr. R. Venkatesh, et al. *Choroidal Detachment Following Femtosecond Laser Assisted Cataract Surgery : A Case Report. Archives of Ophthalmology and Optometry.* 2019; 2(2): 09-12.

Copyright: © 2019 Dr. Prasanth Gireesh, Dr. R. Venkatesh, et al. This is an open access article distributed under the Creative Commons Attribution License, which permits unrestricted use, distribution, and reproduction in any medium, provided the original work is properly cited.