

Rare Complication after Sclero-Trabeculectomy Performed in an Eye with Advanced Primary Open Angle Glaucoma Nonresponsive to Topical Medication

Ioana Madalina Iliescu, M.D^{1*}, Ozana Manuela Moraru, M.D², Simona Elena Lica M.D.³

^{1,2,3}Members of the Romanian Society of Ophthalmology and work in Oculus Eye Clinic, Bucharest, Romania.
madailiescu@yahoo.com

***Corresponding Author:** Ioana M. Iliescu, Clinica Oculus, Calea Floreasca nr. 91-111, Sector 1, Bucharest, Romania.

Abstract

We report the case of a 64 year old woman with advanced, unilateral primary open angle glaucoma for which sclerotrabeulectomy was performed without complications. Five days after surgery the bleb was flat and the intraocular pressure (IOP) was 30 mmHg. Mild massage was indicated. Two days later she presented with flat anterior chamber (AC), IOP 26 mmHg and choroidal detachment that hadn't resolved despite topical atropine and discontinuation of the massage. We suspected an opening of the subchoroidal space at the site of sclerotrabeulectomy with acces of the aqueous humor (AH) from the AC under the choroid. Drainage of the AH from the subchoroidal space was performed, but with fast reformation of the detachments. Then drainage and cryoapplications at the site of sclerotrabeulectomy were done with temporary good results. Two months later, redrainage, broader cryoapplications and phacoemulsification with IOL implantation were performed with good long term results.

Keywords: open angle glaucoma; sclero-trabeulectomy; choroidal detachments.

CASE REPORT

Open-angle glaucoma (OAG) is generally managed using a stepwise approach, beginning with medical and/or laser therapy, and followed by surgery for patients with progressive disease or an increase in intraocular pressure (IOP) to a level at which progression is likely to occur. Postoperative complications associated with trabeculectomy and tube shunt surgery are well described and occur at a low but discernible rate.^{1,2}

Several modifications or adaptations of the standard technique have been described, with some gaining more popularity than others. Anti-metabolites are currently in widespread use, and several studies are investigating the ideal concentration and route of delivery^{3,4} for these drugs.

Here we present a case involving a 64-year-old woman who presented at our clinic with a complaint of impaired vision in her right eye (RE) in February

2017. Her visual acuity (VA) was 20/25 with +0.5Dsf in RE and 20/20 without correction in the left eye (LE), while the corresponding IOP values were 32 and 13 mmHg, respectively, without any medication. Pachymetry (Topcon SP -1P Specular Microscope) revealed a value of 0.460 μ m for RE and 0.456 μ m for LE, with a normal corneal cell count. Anterior segment evaluation revealed prominent episcleral vessels in RE and mild nuclear sclerosis in both eyes, while gonioscopy showed an open angle with mild pigment dispersion in both eyes. Fundus examination showed a cup-to-disc ratio(C/D) of 0.7–0.8 with inferior rim haemorrhage in RE and a C/D of 0.6 with normal vessels and a normal rim in LE.

The patient reported no history of trauma or systemic diseases other than arterial hypertension, for which she was receiving treatment for 4 years. Considering the findings for the anterior segment of RE, a right carotid-cavernous fistula was suspected, and the patient was referred for a complete neurosurgical

Rare Complication after Sclero-Trabeculectomy Performed in an Eye with Advanced Primary Open Angle Glaucoma Nonresponsive to Topical Medication

evaluation and magnetic resonance angiography (MRA). Subsequently, she was prescribed prostaglandin (PG) eye drops (Travoprost), and a visual field (VF) examination performed the following day revealed a mild superior nasal step in VF for RE and a normal VF for LE.

Three weeks later, the patient returned, and examination revealed an IOP of 30 mmHg in RE despite use of the PG eye drops. MRA showed no abnormalities, and a carotid-cavernous fistula was ruled out. Cranial computed tomography ruled out the presence of any secondary intracranial or intraorbital cause for the prominent episcleral vessels in the anterior segment of RE. Her topical medication was switched to a fixed combination of a beta-blocker and a carbonic anhydrase inhibitor (Timolol-Dorzolamide fixed combination); however, her IOP remained elevated 3 weeks later. Considering the lack of response to the

topical medications for glaucoma, she was referred for filtering surgery.

In April 2017, sclero-trabeculectomy augmented with Mytomycin-C application (0.2mg/ml) for 2 min was performed for RE, and there was no intraoperative or immediate postoperative complication on the following day. The surgical technique was in accordance with that described by the Russian Ophthalmologists of the Fedorov Institute. As shown in Figures 1 and 2, after the superficial scleral flap was created and lifted, conventional manual trabeculectomy was performed. In addition, a small deep scleral excision was performed just posterior to the trabeculectomy site in order to expose the choroid. This technique allows both bleb formation and mild subchoroidal filtration.

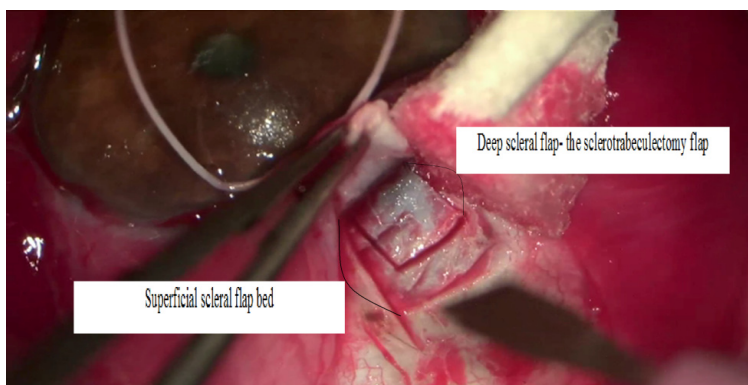


Figure 1. Sclero-trabeculectomy augmented with mytomycin-C application (0.2 mg/ml) for 2 min in the right eye of a patient with primary open-angle glaucoma refractory to topical medications, the image shows the superficial and deep scleral flaps.

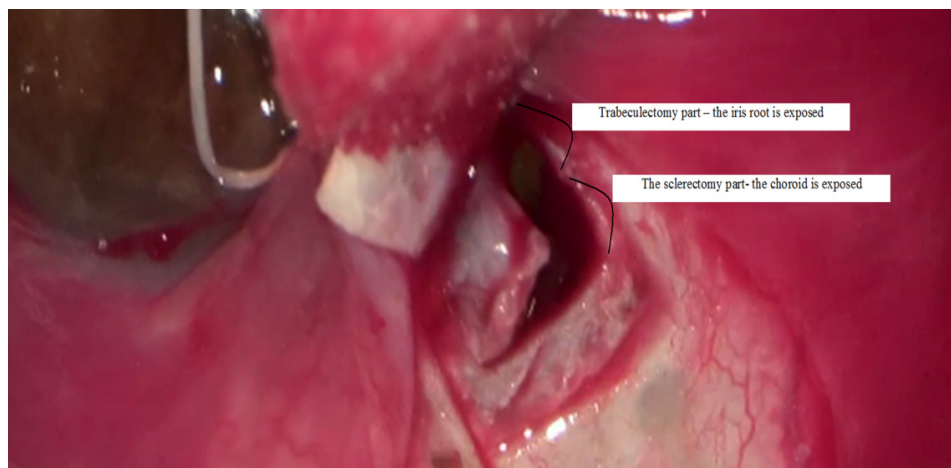


Figure 2. Sclero-trabeculectomy augmented with mytomycin-C application (0.2 mg/ml) for 2 min in the right eye of a patient with primary open-angle glaucoma refractory to topical medications, the image shows the deep scleral flap architecture with the anterior trabeculectomy part and the posterior sclerectomy part exposing the choroid.

Rare Complication after Sclero-Trabeculectomy Performed in an Eye with Advanced Primary Open Angle Glaucoma Nonresponsive to Topical Medication

The patient presented for follow-up 5 days after surgery, and examination revealed a flat bleb and an IOP of 30 mmHg; this IOP easily decreased to 20 mmHg on application of mild pressure on the eye. Accordingly, she was

instructed to gently massage her eye. However, she presented 2 days later with a flat anterior chamber (AC), an IOP of 26 mmHg, and large serous choroidal detachment on B-scan ultrasound (Figure 3).

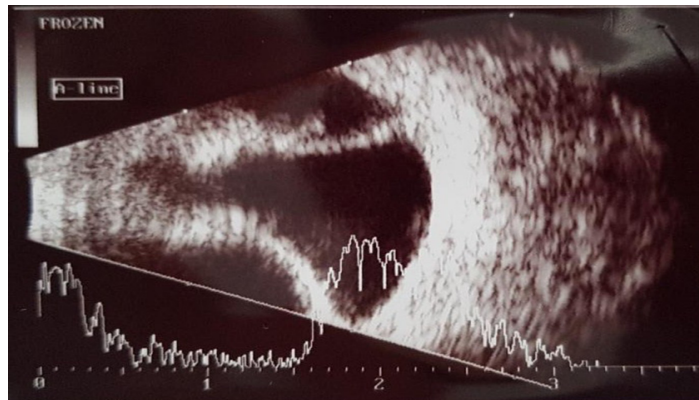


Figure 3. B-scan ultrasound findings after sclero-trabeculectomy for the right eye of a patient with primary open-angle glaucoma refractory to topical medications, a large serous choroidal detachment can be observed.

She was instructed to discontinue the massage and was prescribed topical atropine, tropicamide and phenylephrine five times a day along with oral acetazolamide 250 mg. Unfortunately, AC remained flat and the detachment did not resolve over 2 weeks.

Her IOP remained at approximately 20 mmHg with a daily 250-mg dose of oral acetazolamide. Anterior segment optical coherence tomography for RE showed a very flat AC with a convex configuration of the lens-iris diaphragm (Figure 4).

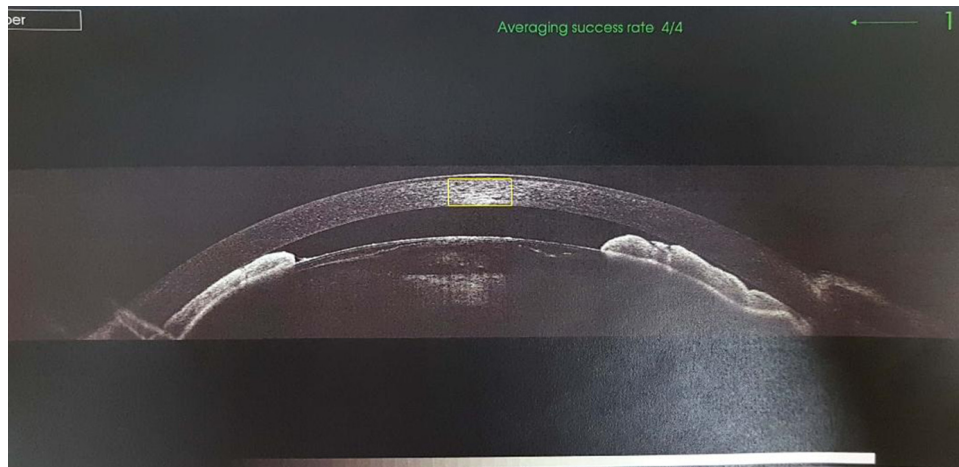


Figure 4. Optical coherence tomography findings after sclero-trabeculectomy for the right eye of a patient with primary open-angle glaucoma refractory to topical medications, a very shallow anterior chamber can be seen.

The fluid accumulated in the subchoroidal space was drained by a retinal specialist, who observed perfectly clear fluid that was very different from the transudate formed in cases of choroidal detachment induced by hypotony. On the basis of this finding, we suspected that there was an opening of the subchoroidal space at the site of the sclero-trabeculectomy, resulting in aqueous humour (AH) leakage from AC under the choroid. In our 20 years of experience, this was the

first time we observed such a complication after this particular surgical technique. Although AC formed well after drainage and the eye became soft, a shallow AC with reappearance of the detachment was observed on the second postoperative day. Re-drainage and cryoapplication at the sclero-trabeculectomy site resulted in satisfactory outcomes for approximately 1 month, following which the detachment gradually reappeared and AC became shallow again.

Rare Complication after Sclero-Trabeculectomy Performed in an Eye with Advanced Primary Open Angle Glaucoma Nonresponsive to Topical Medication

The nuclear sclerosis also continued to progress, and in June 2017, an examination of RE revealed a VA of 20/60, an IOP of 19 mmHg, and a flat AC. In September 2017, a combined surgery involving re-drainage, broader cryoapplication, and phacoemulsification with posterior chamber intraocular lens (IOL) implantation (AAB00 +22D) was performed. Before surgery, OcuScan biometry measured a very shallow AC with a depth of 0.83 mm (Figure 5).

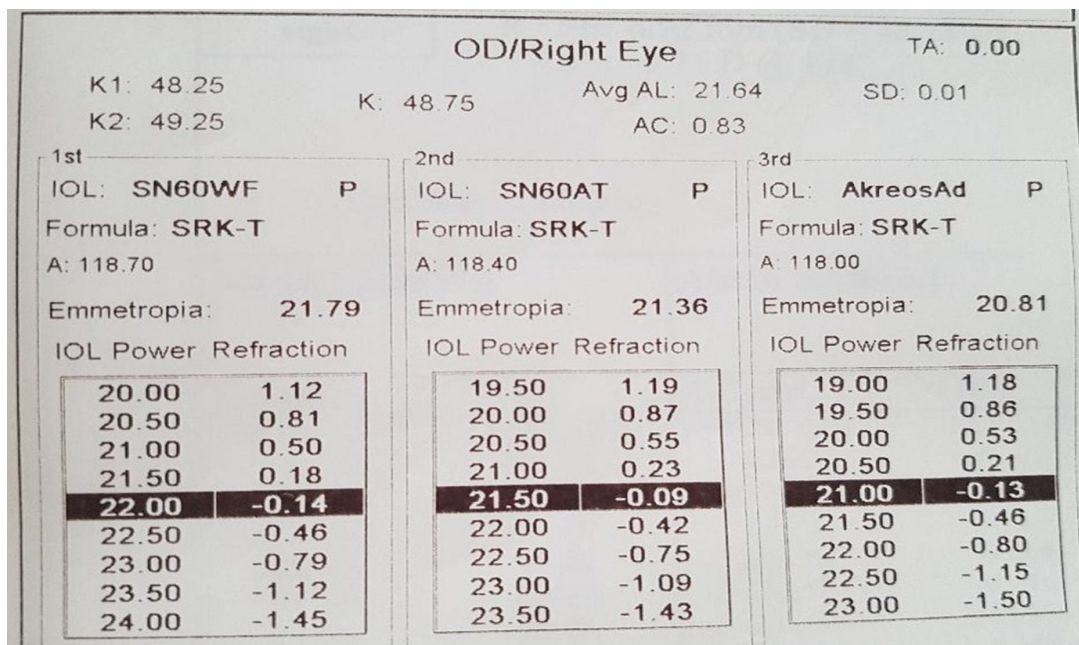


Figure 5. Preoperative OcuScan biometry for the right eye, a very shallow anterior chamber with a depth of 0.83 mm can be observed.

There were no intraoperative complications, and AC remained well formed after surgery. Moreover, her IOP remained in the normal range and the choroidal detachment did not reappear.

The patient's last follow-up visit was in August 2019, two years after the final surgery. VA for RE was 20/20 with correction, while IOP was 14 mmHg with no medication. The anterior and posterior segments were stable, and VF showed no progression of the glaucoma lesion.

DISCUSSION/CONCLUSION

Trabeculectomy can be considered when surgical risks are outweighed by the potential benefits. Risk factors for failure of trabeculectomy include previous intraocular surgery, neovascular or uveitic glaucoma, black race, and young age.⁵ In the early postoperative period, the most common complications faced by the glaucoma surgeon involve either an elevated IOP or hypotony.⁶ An elevated IOP with a deep AC indicates inadequate filtration, whereas early postoperative IOP elevation and shallow AC after trabeculectomy can be

attributed to suprachoroidal haemorrhage, pupillary block, or aqueous misdirection. The elevated IOP should be medically managed while the underlying cause is being evaluated and treated.^{7,8}

In the present case, we performed sclero-trabeculectomy. Generally, all complications and results of this modified technique resemble those of standard trabeculectomy. Our patient initially exhibited a deep AC, flat bleb formation, and a high IOP after surgery, which indicated poor filtration at the level of the superficial scleral flap. With mild massage, her IOP could be easily lowered without any changes in the AC depth. The patient may have applied greater pressure than needed while performing ocular massage at home, because of which a large serous choroidal detachment was formed.

The following points highlight the novelty of the present case: unilateral advanced glaucoma, atypical anterior segment aspect with prominent episcleral vessels without any detectable underlying cause, absolutely no response to all topical medications, and a very uncommon postoperative outcome. After an

Rare Complication after Sclero-Trabeculectomy Performed in an Eye with Advanced Primary Open Angle Glaucoma Nonresponsive to Topical Medication

uneventful surgery with no immediate postoperative complication on the following day or the next few days, the patient developed a very unusual complication, which was characterized by extensive serous choroidal detachment, an extremely flat AC, and a high IOP. The choroidal detachment, which was resistant to all medical and surgical manoeuvres applied, compelled us to look for a better technique for closure of the presumed subchoroidal space opening. We applied cryo-spots over the superior sclera, posterior to the site of trabeculectomy, not to decrease aqueous formation (which is generally the goal of cryotherapy for glaucoma), but to create a scar that would eventually block the subchoroidal drainage. This was followed by phacoemulsification, which not only resolved the nuclear sclerosis and restored the visual acuity but also corrected the opened angle by deepening AC. Thus, we improved the aqueous drainage via normal-functioning trabeculectomy and the trabecular meshwork after opening the angle.

To our knowledge, this combined surgery is the first such surgical technique described for the management of an uncommon post-glaucoma surgery complication. This novel technique successfully closed the opening of the subchoroidal space. Moreover, the postoperative visual acuity was 20/20, the AC depth remained stable, the bleb function was acceptable, IOP became stable at approximately 14–16 mmHg, and VF remained unchanged.

REFERENCES

- [1] Gedde SJ, Herndon LW, Brandt JD, et al. Postoperative complications in the Tube Versus Trabeculectomy (TVT) study during five years of follow-up. *Am J Ophthalmol* 2012; 153:804–814.
- [2] Budenz DL, Feuer WJ, Barton K, et al. Postoperative complications in the Ahmed Baerveldt Comparison Study during five years of follow-up. *Am J Ophthalmol* 2016; 163:75–82.
- [3] Lim MC, Tong MG, Brandt JD, et al. A comparison of trabeculectomy surgery outcomes with mitomycin-C applied by intra-tenon injection versus sponge method. Abstract. American Glaucoma Society 23rd Annual Meeting; 2013.
- [4] Kwong TQ, Mahroo O, Scoppettuolo E, Ansari E. Outcomes of trabeculectomy with transconjunctival application versus subconjunctival application of mitomycin C. *J*
- [5] Broadway DC and Chang L. Trabeculectomy, risk factors for failure and the preoperative state of the conjunctiva. *J Glaucoma*, 2001; 10(3): 237-49.)
- [6] Jampel HD, Musch DC, Gillespie BW, et al. Perioperative complications of trabeculectomy in the collaborative initial glaucoma treatment study (CIGTS). *Am J Ophthalmol* 2005; 140(1):16-22.
- [7] Allingham RR, Damji KF, Freedman S, et al. "Filtering surgery." *Shields' Textbook of Glaucoma*. Ed. Jonathen Pine and Joyce Murphy. Philadelphia, Pennsylvania: Lippincott Williams and Wilkins, 2005. 568-95.
- [8] Jinza K, Saika S, Kin K, et al. Relationship between formation of a filtering bleb and an intrascleral aqueous drainage route after trabeculectomy: Evaluation using ultrasound biomicroscopy. *Ophthalmic Res* 2000; 32: 240-3.

Citation: Ioana Madalina Iliescu, Ozana Manuela Moraru, Simona Elena Lica. *Rare Complication after Sclero-Trabeculectomy Performed in an Eye with Advanced Primary Open Angle Glaucoma Nonresponsive to Topical Medication. Archives of Ophthalmology and Optometry. 2019; 2(2): 01-05.*

Copyright: © 2019 Ioana Madalina Iliescu, Ozana Manuela Moraru, Simona Elena Lica. *This is an open access article distributed under the Creative Commons Attribution License, which permits unrestricted use, distribution, and reproduction in any medium, provided the original work is properly cited.*