

Pediatric Orbital Tumor in Abidjan: Epidemiological Review of 79 Cases in the Ophthalmology Department of Treichville University Hospital (Côte D'ivoire)

Berete C.R.¹, Couitchere L.², Kabran V.¹, Balde A.K.¹, Konan A.¹, Sowagnon T.³, Kouï S.⁴
Fanny Adama¹

¹Ophthalmology department of Treichville University Hospital.

²Pediatric department of Treichville University Hospital.

³Ophthalmology department of Yopougon University Hospital.

⁴Pathology department of Treichville University Hospital.

bereterokia@hotmail.fr

***Corresponding Author:** Berete Coulibaly Rokia, Ophthalmology department of Treichville University Hospital, Ivory Coast.

Abstract

Introduction: Orbital malignancies in children and teenagers are rare entities that are defined as neoplasias developed at the expense of orbit structures. When diagnosed late, the functional and vital prognosis of patients can be at stake.

In order to make an assessment and highlight their specificities, we describe the epidemiological features of orbital malignancies in children and teenagers aged 0 to 18 years.

Methods: We performed a retrospective and descriptive cross-sectional study on all cases of orbital malignancies monitored at Treichville University Hospital over a period of 5 years, from January 2012 to December 2016.

All patients aged 0 to 18 years followed at Treichville University Hospital with histopathology confirmation of malignancy of the orbit were included.

Results: We recorded 79 cases of orbital malignancies in patients aged 3 months to 18 years with an average age of 4.34 years. There was a male predominance with a sex ratio (M \ F) of 1.3. The average consultation time was 9.49 months. The majority of patients came from poor socioeconomic groups that is 70%. Exophthalmos was the main sign found during consultation in 93.67% of cases. The most common tumors in this population were retinoblastoma spread to the orbit, 51 cases (64.56%), Burkitt's lymphoma, 12 cases (15.19%) and Rhabdomyosarcoma 09 cases (11.39%) respectively.

Diagnostic and / or therapeutic management consisted of excisional biopsy in 38 cases, mutilating surgery in 28 cases and fine needle biopsy in 13 cases.

Conclusion: Orbital malignancies have a severe prognosis due to their late diagnosis. Exophthalmos remains the main sign and etiologies remain varied with at the top retinoblastoma spread to the orbit. This series reinforces the need to make early diagnosis to reduce the mortality and morbidity associated with these tumors.

Keywords: malignancy, orbit, exophthalmos, retinoblastoma spread to the orbit, Burkitt's lymphoma, Rhabdomyosarcoma, poor social conditions.

INTRODUCTION

Orbital malignancies are defined as neoplasias developed at the expense of orbital structures, primitively or secondarily [1, 2]. In subjects under

18, their prevalence is underestimated because of the very small number of studies devoted to them. They constitute a rare entity, 3% of all tumors of children and teenagers [3]. These tumors can quickly put at

Pediatric Orbital Tumor in Abidjan: Epidemiological Review of 79 Cases in the Ophthalmology Department of Treichville University Hospital (Côte D'Ivoire)

stake the functional and vital prognosis of patients involved due to their late diagnosis. In Côte d'Ivoire, to our knowledge, no statistical data on orbital malignancies are known to date. To assess their seriousness and clinical peculiarity in order to improve their management, we carried out an epidemiological study in children and teenagers from 0 to 18 years.

METHODOLOGY

Over a period of one year we collected records of patients received in the ophthalmology and pediatric oncology departments for orbital tumors from January 2012 to December 2016. In this retrospective and descriptive cross-sectional study, were included all patients aged 0 to 18 years with a histologically confirmed orbital malignancy. Orbital malignancies lacking histopathology evidence and incomplete records were not considered. The listed data included both personal and family history of cancer, socio-economic features of families, demographic data (age and gender), time and reason for consultation, clinical symptoms and signs, the results of imaging and pathology. We used the software Epi info 7 to process these data.

RESULTS

During the study period, 818 cases of children cancer were identified, including 79 cases of orbital malignancies in 69 patients that is a prevalence of 9.66% for all cancers of children and teenagers. The average annual hospital incidence of these tumors is 20.25% that is 16 new cases. However, we note a peak frequency in 2015 with 25 new cases that is 31.64% (Figure 1). The male gender was predominant with a sex ratio of 1.3 (Table 1). The average age of our patients was 4.34 years with extremes ranging

from 3 months to 18 years. The age groups under 2 years and 5 to 10 years were the most affected with 31.65% and 34, 18% of cases respectively (Table 2). Most of these patients were from low-income families (70% of cases) (Table 3), children out of school (88% of cases) and living more than 100 km away from our hospital (58% of cases). In terms of clinical data, no history of family cancer was found in 91% of cases in these patients. The consultation times observed were long. More than 85% of our patients were seen 1 month after the onset of the symptomatology and more than 48% after 6 months (Table 4). Exophthalmos was the most frequently found reason for consultation, in 74 out of 79 cases (93.7%) (Figure 2, Table 5). The mode of occurrence of the disease was progressive in the majority of cases (97.5% of cases). The tumor was bilateral in 10 cases. The right eye was involved in 36 cases and the left eye in 33 in a total of 69 patients. The fundus examination was normal in 4 patients, inaccessible in 12 and it objectified a whitish tumor in one and was unspecified in the other 52 patients. Computed tomography (CT) and magnetic resonance imaging (MRI) revealed in 98.24%, tumors with orbital location within 26.32% of cases an intracranial extension. In the diagnostic and therapeutic management, 38 tumors underwent a biopsy, 28 a mutilating surgery and 13 a fine needle biopsy. The histological diagnosis duration was long with a median of ... (Table 6). The most common tumors were successively retinoblastoma spread to the orbit with 51 cases including 40 cases observed in patients under 4 years of age, Burkitt's lymphomas with 12 cases including 10 between 5 and 10 years and rhabdomyosarcoma with 9 cases whose distribution is homogeneous in all age groups (Tables 7 and 8).

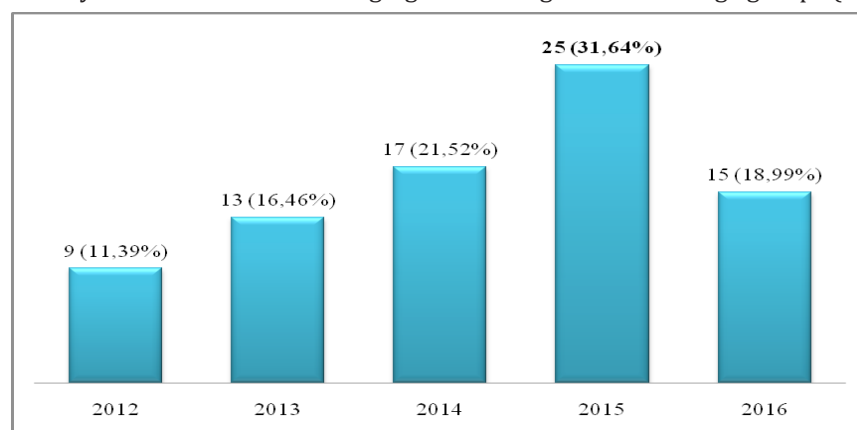


Figure 1. Distribution according to the number of cases per year

Pediatric Orbital Tumor in Abidjan: Epidemiological Review of 79 Cases in the Ophthalmology Department of Treichville University Hospital (Côte D'ivoire)

The mean annual hospital frequency of orbital malignancies was 16 (20.25%) with a peak frequency in 2015: 25 cases that is 31.64%.

Table 1. Distribution according to the gender

Gender	Number	Percentages
Female (F)	34	43.04
Male (M)	45	56.96
Total	79	100

Sex-ratio (M/F) = 1.3 in favor of the male gender (56.96%)

Table 2. Distribution according to age groups

Age group	Number	Percentages
1 month to 24 months	25	31.65
25 months to 59 months	24	30.38
5 years to 10 years	27	34.18
11 years to 18 years	3	3.80
Total	79	100

We recorded more patients between 5 and 10 years, with a minimum of 3 months and a maximum of 27 patients that is 34.18%. The average age was 4.34 years.

Table 3. Distribution according to the socio-economic conditions of the families to which the surveyed patients belong.

Socioeconomic conditions	Number	Percentages
Unfavorable	55	69.62
Average	12	15.19
Unspecified	12	15.19
Total	79	100

More than half of the families, 55 (69.62%) lived in unfavorable conditions at the time of our study. No patient lived in good socio-economic conditions.

Table 4. Distribution according to the consultation period after the discovery of the first signs by the parents

Consultation period (in months)	Number	Percentages
[0 ; 1]	4	5.06
[1 ; 3]	17	21.52
[3 ; 6]	12	15.19
[6 ; 12]	25	31.65
More than 12 months	13	16.45
Unspecified	8	10.13
Total	79	100

The mean consultation period after the discovery of the first signs was 9.49 months with a minimum time of 1 month and a maximum time of 48 months. The majority of patients 25 (31.65%) were received between 6 and 12 months.

Pediatric Orbital Tumor in Abidjan: Epidemiological Review of 79 Cases in the Ophthalmology Department of Treichville University Hospital (Côte D'ivoire)

Table 5. *Distribution according to the reason for consultation*

Reason for consultation	Yes		NO		TOTAL	
		%		%		%
Strabismus	3	3.80	76	96.20	79	100
Eye pain	4	5.06	75	94.94	79	100
Palpebral induration	5	6.33	74	93.67	79	100
Exorbitism	2	2.53	77	97.47	79	100
Redness	9	11.39	70	88.61	79	100
Headache	8	10.13	71	89.87	79	100
Exophtalmos	74	93.67	5	6.33	79	100

The most frequent reason for consultation was exophthalmos, observed in 74 patients that is 93.67%.

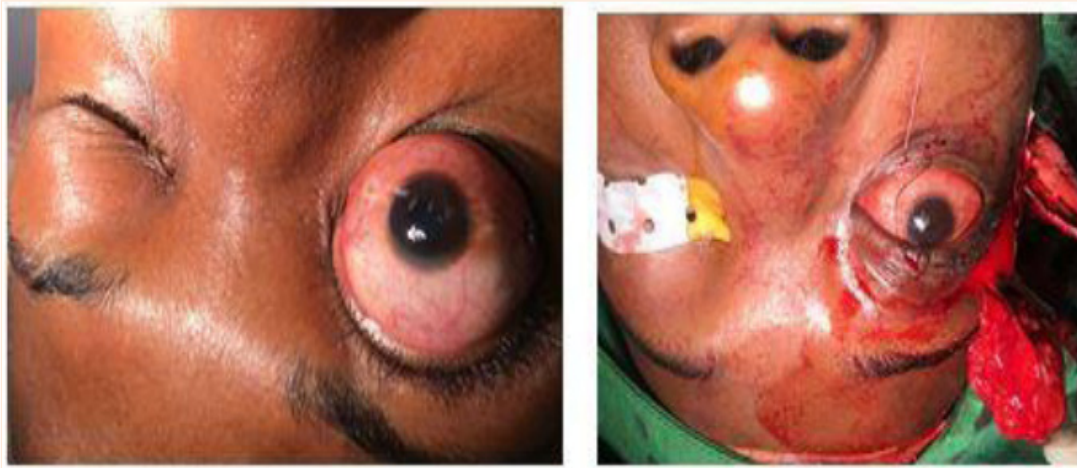

Figure 2a. *Right sided uniliateral exophthalmos* **Figure 2b.** *peroperative orbital tumor evidence of an intra orbital exophthalmos*

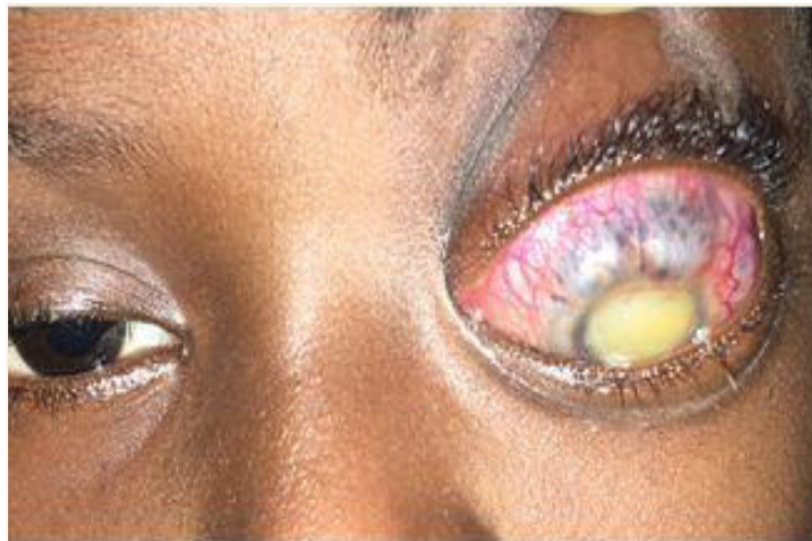

Figure 3. *Left Exophthalmos with LEUCOCORIE involve a 3 year old child who has a retinoblastoma*

Pediatric Orbital Tumor in Abidjan: Epidemiological Review of 79 Cases in the Ophthalmology Department of Treichville University Hospital (Côte D'ivoire)

Table 6. Distribution according to the duration of the histological diagnosis

* The duration of the histological diagnosis corresponds to the difference between the date of the histological diagnosis and the date of the surgery for the histological diagnosis.

Duration of the elaboration of the histological diagnosis (in days)	Number	Percentages
[0-15]	15	38.46
[15-30]	10	25.64
[30-45]	9	23.08
[45-60]	2	5.13
[60-75]	1	2.56
[105-120]	1	2.56
[180-195]	1	2.56
Total	39	100

The mean duration of the histological diagnosis was 30 months (maximum). In 38.46% of cases, the duration was 30 days with extremes of 2 days (minimum) and 6 months of the histological diagnosis was between 0 and 15 days.

Table 7. Distribution according to the histological diagnosis

Histology	Number	Percentages
Squamous cell carcinoma	2	2.53
Liposarcoma	1	1.27
Burkitt's lymphoma	12	15.19
Diffuse lymphoma with large cells	1	1.27
Lymphoblastic lymphoma	1	1.27
Neuroblastoma	2	2.53
Rétinoblastoma	51	64.56
Rhabdomyosarcoma	9	11.39
Total	79	100

Table 8. Distribution of histological diagnosis according to age groups

Histology	Age group									
	1 to 24 months		25 to 59 months		5 to 10 years		11 to 18 years		Total	
	Numb	%	Numb.	%	Numb.	%	Numb.	%	Numb .	%
Squamous cell carcinoma	1	4	0	0	1	3.7	0	0	2	2.53
Liposarcoma	0	0	0	0	1	3.7	0	0	1	1.27
Burkitt's lymphoma	0	0	2	8.33	10	37.04	0	0	12	15.19
Diffuse lymphoma with large cells	0	0	1	4.17	0	0	0	0	1	1.27
Lymphoblastic lymphoma	1	4	0	0	0	0	0	0	1	1.27
Neuroblastoma	0	0	1	4.17	1	3.7	0	0	2	2.53
Rétinoblastoma	21	84	19	79.17	10	37.04	1	33.33	51	64.56
Rhabdomyosarcoma	2	8	1	4.17	4	14.81	2	66.67	9	11.39
TOTAL	25	100	24	100	27	100	3	100	79	100

DISCUSSION

Children cancers are rare and account for about 1% of all cancers. Their particular severity, the duration of their evolution and their particularly long treatment make it a public health problem [4]. Orbital malignancies are relatively rare [5]. They are characterized by their histological diversity according to the anatomical structure on which they arise. They are most often primitive (mesenchymal, lymphoid, nerve, lachrymal, bone and vascular) and rarely secondary to distant cancer [6,7]. There is very little research on oculo-orbital pathology in Africa, however oculo-orbital tumors are the most common in tropical Africa compared to those in Europe [8].

Our study revealed that 69.6% of patients lived in poor socio-economic conditions. This observation is related

DISCUSSION

Children cancers are rare and account for about 1% of all cancers. Their particular severity, the duration of their evolution and their particularly long treatment make it a public health problem [4]. Orbital malignancies are relatively rare [5]. They are characterized by their histological diversity according to the anatomical structure on which they arise. They are most often primitive (mesenchymal, lymphoid, nerve, lachrymal, bone and vascular) and rarely secondary to distant cancer [6,7]. There is very little research on oculo-orbital pathology in Africa, however oculo-orbital tumors are the most common in tropical Africa compared to those in Europe [8].

Our study revealed that 69.6% of patients lived in poor socio-economic conditions. This observation is related to a large proportion of the population for the same period living below the poverty line, according to a study by the National Statistical Institute of Côte d'Ivoire [9]. Several other authors say the same thing and think that low incomes would constitute a brake for a global management [10; 11; 12, 13; 14].

The consultation period remains long in our study, more than 6 months for 48% of patients while the evolution was gradual in 97.4% of cases. (The delay in consultation was related to the unfavorable socio-demographic conditions of our patients. Indeed 69.6% lived in poor socio-economic conditions, with 58% of

patients living more than 100 kilometers away from the capital where the referral center is situated.

This delay in consultation was at the origin of advanced forms of tumors encountered from the first consultation as shown by the presence of exophthalmos in 93.7% of cases. Exophthalmos, master symptom of orbital pathology remains the main sign of consultation with percentages superimposable on the data of the literature that is 93.7%; 92.3%; 81% for Jibbia, Belmekki and Meriague [3; 15] respectively. In these studies as well as in ours, patients live in poor socio-economic conditions. A shorter consultation period of 2.5 months was noted in Ben's study [16]. Early consultation was related to a more favorable socio-economic level leading to better access to care. The management of orbital malignancies is based on careful interrogation and clinical examination. The presumption of the diagnosis is brought by the data of clinical examination, imagery (ultrasound, CT and MRI). Histopathology helps confirm the diagnosis [17]. CT remains the most performed exam in most studies considering the value for money. We could perform CT in 72.2% of our patients. CT, in addition to its accessibility, reveals calcifications, bone involvement and a staging of exophthalmos [1; 18; 19]. MRI remains the preference of some authors because it is harmless nature and allows a better characterization of soft tissues [19]. However, its prohibitive cost limits its indication in Africa. We could perform it only in four patients because this examination is not available in most public centers in our country in relation to a generally unfavorable socio-economic level (69.6%). The mean time for histopathology report remains long in our study that is 30 days after the first consultation with extremes ranging from 2 days to 182 days (6 months). In 38.46% of cases, the duration of the histological diagnosis was between 0 and 15 days. The long delay of histopathology report could be explained by ignorance and lack of financial means. One can also suggest the high solicitation of pathology centers with regard to a limited number of structures and specialists in pathology in Africa. Histopathology was obtained through mutilating surgery in 28 cases (35.44%), biopsy in 38 cases (48.10%) and fine needle biopsy in 13 cases (12.46%). The time of surgical management was long, between 0 to 15 days for more than half of the patients (56.41%) and this is due to the limited number of specialized centers as well as the lack of

Pediatric Orbital Tumor in Abidjan: Epidemiological Review of 79 Cases in the Ophthalmology Department of Treichville University Hospital (Côte D'ivoire)

financial means. Etiologies of children orbital tumors are varied. In our study, the most common etiology is retinoblastoma spread to the orbit (64.56%), followed by Burkitt's lymphoma (15.19%) and Rhabdomyosarcoma (11.39%). Retinoblastoma remains the most common malignant intraocular tumor in children in our context. This predominance of retinoblastoma is also observed in the work of Jibia, Zaari [3,20]. It is a tumor of neuroectodermal origin developed from the young retinal cells due to a chromosomal abnormality identified on the band 14 of the long arm of chromosome 13. This tumor spreads secondarily to the orbit in the absence of a rapid and appropriate management. Due to the long consultation period, the majority of patients presented with exophthalmos.

Other authors, such as Jibia, rather find a predominance of Burkitt's lymphoma and retinoblastoma [3], while Rahmatallah and Rayana highlighted a predominance of rhabdomyosarcoma. These authors think that rhabdomyosarcoma is the most common orbital malignancy in children [19; 21]. For Koopman, the most common orbital malignancies were lymphoma followed by rhabdomyosarcoma, basal cell carcinomas and adenocarcinomas [22]. On the other hand, lymphoproliferative diseases predominate in orbital tumors in Ting's study [23]. Burkitt's lymphoma, the second tumor after retinoblastoma spread to the orbit in this study, is thought to be the most common malignancy of children in Africa all locations considered, specifically in sub-Saharan Africa [24]. Togo et al found in their study in Mali that the orbital location is estimated at 39.3% of all Burkitt's lymphomas [25]. The main prognostic factors of orbital malignancies of children remain their late consultation, the inaccessibility of MRI, the long time for histopathology report, their histological nature and the availability of specialized centers.

CONCLUSION

Orbital malignancies are of severe prognosis and of various etiologies with at the top retinoblastoma spread to the orbit. The diagnosis of orbital tumors of children remains late due to the inaccessibility of patients to the specialized center related to their unfavorable socio-economic level, to the long histopathology diagnosis. This series reinforces the need to make early diagnosis to reduce the mortality

and morbidity associated with these tumors. The early diagnosis of the disease involves public awareness, equipping the centers and training of specialists.

REFERENCES

- [1] Mejdoubi M, Arne JL, Sevely A. Tumeurs orbitaires chez l'enfant : Revue iconographique en TDM et IRM. In Jour Rad 2007 Déc; 88(12): 1855-64.
- [2] Appelmans MN, Guzik A, Sels JH. Tumeur congénitale de l'orbite avec méningo-encephalocèle. Bull Soc Belge Ophtalmol 1965; 141: 632-31.
- [3] Tacyldiz N, Ozyroruk D, Yavuz G, et al. Rare childhood tumors in a Turkish pediatric oncology center. Indian J Med Paediatr Oncol 2013 Oct-Dec; 34(4): 264-69.
- [4] Steliarova-Foucher E, Stiller C, Kaatsh P, et al. Geographical patterns and time trends of cancers incidence and survival among children and adolescents in Europe since the 1970s (the ACCISproject): an epidemiological study. Lancet 2004; 36(9451): 2097-105.
- [5] Chadan N, Martin D, Ba-Zizen MT, Cabano EA, Chailloux E. Processus expansifs intra orbitaires. A propos de 917 études rétrospectives d'un registre neuro-ophtalmologique de 6354 cas. Ophtalmologie 1992; 6: 39-42.
- [6] Margo CE, Muller ZD. Malignant tumors of the orbit. Analysis of the Florida cancers registry. Ophthalmology 1998; 105: 185-190.
- [7] Shields JA, Shields CL, Scarlozzi R. Survey of 1264 patients with orbital tumors and simulating lesions. Ophthalmology 2004; 111: 997-1006.
- [8] Discamps G, Doury JC, Chovet M. Contribution à l'étude statistique des cancers oculo-orbitaires en Afrique. A propos de 460 observations. Med Trop 1972 ; 32 : 385-401.
- [9] Institut National de la Statistique. Enquête sur le niveau de vie des ménages en Côte d'Ivoire (ENV2015). 2015. 3,49.
- [10] Segbena A, Kueviakue M, Vovor A, Tatagan-Agbi K, Assimadi K, Napo-Koura G et al. Le lymphome de Burkitt au Togo : Aspects épidémiologique, clinique, thérapeutique et évolutif. Med Afr Noir. 1997 ; 44 (3).

Pediatric Orbital Tumor in Abidjan: Epidemiological Review of 79 Cases in the Ophthalmology Department of Treichville University Hospital (Côte D'ivoire)

- [11] Seck S, Agoton G, Gueye N, Diop J, Seck C, Lam A. Aspects épidémiologiques et cliniques des cancers oculaires primitifs du mélanoderme : notre expérience à propos de 111 cas. Dans : *JFO*. 2015 ; 38 : 41-5.
- [12] Kaya G, Makita Bagamboula C, Silou J-F, Manvouri L, Lyaba I, Pintart D. Profil des affections orbitaires au Centre Hospitalier et Universitaire de Brazzaville, Congo. *JFO*. 2006 ; 29 (3) : 281-8.
- [13] Poso M, Mwanza J., Kayembe D. Les tumeurs malignes de l'œil et ses annexes au Congo-kinshasa. *JFO*. 2000 ; 23 (4) :327-32.
- [14] Togo B, Keita M, Medefo D, Traore F, Sidibe T. Le Lymphome de Burkitt à localisation maxillo-faciale en milieu pédiatrique au CHU Gabriel Touré, Bamako, Mali : à propos de 24 cas. *Med Trop*. 2008; 68: 600-2.
- [15] Belmekki M, El Bakkali M, Abdellah H, Benchrifa F, Berraho A. Épidémiologie des processus orbitaires chez l'enfant : A propos de 54 cas. *JFO*. 1999; 22 (3): 394-8.
- [16] Ben Rayana N, Ben Hadj Hamida F, Hamdi R, Ammari H, Krifa F, El Aoumari K, Knani L, Yaakoubi S. Le rhabdomyosarcome orbitaire : une urgence diagnostique et thérapeutique. *JFO*. Avr 2007 ;30 (2) : 181.
- [17] Morax S, Desjardins L. Urgences tumorales orbitaires pédiatriques. *J Fr Ophtalmol* 2009 Mai ; 32(5) : 357-67.
- [18] Doz F, Khalfaoui F, Mosseri V. The role of chemotherapy in orbital involvement of retinoblastoma. The experience of single institution with 33 patients. *Cancer*. 1994 ; 74 : 722-32.
- [19] Rahmatallah K, Mimouni I, Moussali N, El Benna N, Gharbi A, Abdelouafi A. Les exophtalmies tumorales malignes de l'enfant à propos de 14 cas. *Jr Fr Radiol*. Oct 2010.
- [20] Zaari J, Noha. Les tumeurs orbitaires de l'enfant : étude épidémiologique à propos de 449 cas. Thèse Med. Casablanca 2002.
- [21] Ben Rayana N, Ben Hadj Hamida F, Hamdi R, Ammari H, Krifa F, El Aoumari K, Knani L, Yaakoubi S. Le rhabdomyosarcome orbitaire : une urgence diagnostique et thérapeutique. *JFO*. Avr 2007 ; 30 (2) : 181.
- [22] Koopman JH, Van der Heiden-van der Loo M, Van Dijk MR, Bijlsma WR. Incidence of primary malignant orbital tumours in the Netherlands. *Eye* 2011; 25: 461-465.
- [23] Ting DSJ, Perez-lopez M, Chew NJ, Clarke L, Dickinson AJ, Neoh C. A 10-year review of orbital biopsy: the Newcastle Eye Center Study. *Eye* 2015; 29: 1162-1166.
- [24] Koffi K, Bosson N, Aka-Adjo M, Diop S, N'dhatz E, Ahmedou O, et al. Résultats du traitement du lymphome de Burkitt africain. Expérience du service d'hématologie clinique du CHU de Yopougon (Abidjan). *Med Afr Noire* 1997 ; 44(2) : 635-9.
- [25] Togo B, Keita M, Medefo D, Traoré F, Sidibé T. Le lymphome de Burkitt à localisation maxillo-faciale en milieu pédiatrique au CHU Gabriel Touré, Bamako, Mali: a propos de 24 cas. *Med Trop* 2008 ; 68 : 600-2.

Citation: Berete C.R, Couitchere L, et al. *Pediatric Orbital Tumor in Abidjan: Epidemiological Review of 79 Cases in the Ophthalmology Department of Treichville University Hospital (Côte D'ivoire)*. *Archives of Ophthalmology and Optometry*. 2018; 1(2): 24-31.

Copyright: © 2018 Berete C.R, Couitchere L, et al. This is an open access article distributed under the Creative Commons Attribution License, which permits unrestricted use, distribution, and reproduction in any medium, provided the original work is properly cited.