

# Primary Cutaneous and Subcutaneous Neuroectodermal Tumor/Ewing's Sarcoma: Long-Term Survival after Local Excision

Maite López Deogracias\*, Francisco Martínez García\*, Karmele Mugika\*\*, Iñaki Arias-Camison\*\*\*

\*Department of General Surgery. Clínica Asunción. Tolosa. Guipúzcoa.

\*\*Department of Medical Oncology. Onkologikoa. Donostia. Guipúzcoa.

\*\*\*Department of Pathology. Clínica Asunción. Tolosa. Guipúzcoa.

\*lopezdeogracias@gmail.com

**\*Corresponding Author:** Maite López Deogracias, Cirugía General y del Aparato Digestivo, Clínica Asunción, 20400 Tolosa, Guipúzcoa (España).

## Abstract

Primitive neuroectodermal tumor/Ewing's sarcoma (PNET/ES) is an uncommon type of small blue cell neoplasms; it rarely originates and develops in cutaneous and subcutaneous tissue and this characteristic seems to be linked to a better prognosis. However, there is no consensus on the treatment and combined therapies are the most extended choice, either chemotherapy and surgery, or radiotherapy and surgery. Further studies are needed to conclude if we should treat Primary Cutaneous Ewing Sarcoma as we treat Ewing Sarcoma. We present two cases of PNET, treated exclusively with surgical excision with negative margins, who are free of local or extended disease 13 and 26 years after surgery.

**Keywords:** Ewing's Sarcoma, PNET, malignant primitive neuroectodermal tumor, cutaneous, surgery.

## INTRODUCTION

Ewing's sarcoma was first described by James Ewing<sup>1</sup> in 1921 and it was initially distinguished from the peripheral neuroectodermal tumor (PNET) as a different entity. However, both of them share a very similar histology and the same immunohistochemical profile and genetic translocations, so today they are considered as two ends of a morphologic spectrum of the same biologic entity.

The Ewing's sarcoma family includes extraosseous Ewing's sarcoma, PNET, Askin tumor and atypical Ewing's sarcoma.

Although the majority of extraskeletal ES/PNET are located in the deep soft tissues, rare cases of primary cutaneous ES/PNET have been described. This atypical location is associated with a better prognosis, as it presents a slow course with reported survival rates of 91% in 10 years<sup>2,3,4</sup>.

Clinically, primary cutaneous and subcutaneous Ewing's sarcoma affects children and young adults, and it appears as a superficial and well defined node,

with soft consistency, mobile and slightly painful<sup>3</sup>.

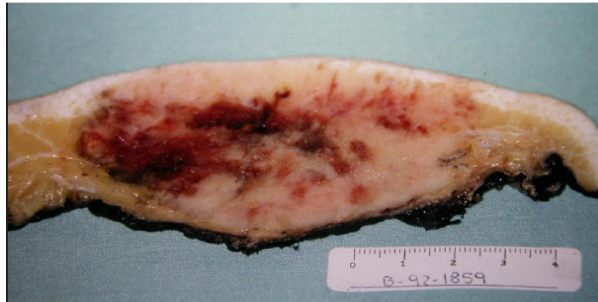Histologically, Ewing's sarcoma is formed by small round cells with prominent fibrovascular septa and typical Homer-Wright rosettes.

Differential diagnosis must be done with other neoplasms composed of small round cells, both primary neoplasms and cutaneous metastases. Definitive diagnoses may be achieved with histochemical stains, immunohistochemistry, electron microscopy, cytogenetics and molecular genetics of translocations.

Treatment is usually composed of combined therapies, including surgery and chemotherapy or radiotherapy. However, there are progressively more reports suggesting to consider surgical excision without adjuvant therapy in selected cases of cutaneous and subcutaneous ES<sup>4</sup>. More studies are needed to reach solid conclusions, but we present two cases of cutaneous and subcutaneous ES treated with surgical excision, who are disease-free 13 and 26 years after surgery.

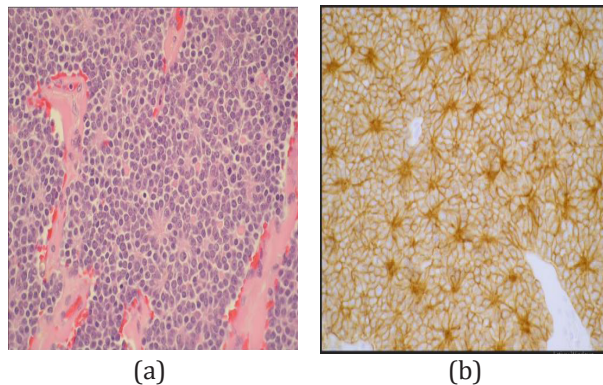
### CASE REPORT 1

We describe a 22 year-old male, allergic to penicilin, with a slowly growing mass of 8cm diameter size, located in the subcutaneous tissue of the right lumbar paravertebral region, well defined, mobile and with mild-soft consistency. An incisional biopsy was performed to establish diagnosis, where a small cell neoplasm was found (figure 1). The patient underwent to wide surgical resection.



**Fig. 1.** Macroscopic aspect of the node excised in Case report 1

Histological examination revealed a small round blue cell tumour composed of uniform, small to medium round cells containing small nuclei with granular chromatin and ill-defined nucleoli; cytoplasm was scanty. Neoplastic undifferentiated cells were aggregated into nodules and strands and also interposed between collagen bundles. Homer-Wright rosettes were identified (fig.2).



**Fig. 2.** Homer-Wright rosettes observed in H-E staining (a) and CD99 (b)

Final diagnosis was malignant primitive neuroectodermal tumor (MPNET).

Complementary studies showed absence of metastases.

No adjuvant therapy was administered.

The patient is disease-free 26 years after surgery.

### CASE REPORT 2

A 16 year-old male consulted in our Hospital in 2005 with a right paravertebral mass of 3cm diameter, with soft consistency, slightly painful. An excisional surgery was performed with wide margins. Histologically it was composed of malignant cells located only in the deep dermis, with clear margins and occasional cluster disposition. Neoplastic cells contained small nuclei, regular chromatin and frequent mitosis.

Immunohistochemistry markers were membrane positive for CD99 and vimentine and most of the cells were also positive for keratins AE1-AE3 and EMA. LCA, S100 and CD34 were negative. Most of the cellularity showed enolase +.

A wide margin resection was performed in a second surgical procedure. There were no pathological findings in the second specimen.

No complementary treatment was administered.

13 years after surgery, the patient remains free of local or distant disease.

### DISCUSSION

Primitive neuroectodermal tumor and Ewing sarcoma are two entities of the so called "small blue cell tumors" family. Although they are morphologically similar, there are several clinical and immunohistochemical differences. After James Ewing discovered Ewing Sarcoma in 1921, Angerwall et al reported in 1975 the first cases of extraskeletal location of the ES<sup>5,6</sup>; most of them affected deep soft tissues, thoracic wall, paraspinal region and low limbs<sup>7</sup>. Less frequently, ES can affect kidneys, pancreas and subcutaneous tissue.

Further immunohistochemical, electromicroscopy and cytogenetic studies are needed to assess the correct diagnosis.

There are very few reports in literature about ES located in subcutaneous tissue. It predominates in children and young adults at a very large spectrum of age which ranges from 2 months to 81 years

The term primitive neuroectodermal tumor alludes to a differentiation observed towards neural tissues, affecting either central or peripheral nervous system.

From a genetic point of view it shares translocation t(11;22) with the ES.

## Primary Cutaneous and Subcutaneous Neuroectodermal Tumor/Ewing's Sarcoma: Long-Term Survival after Local Excision

Histologically, Ewing sarcoma is characterized by small round cells placed in strands, lobes or nests; in 10-20% of the cases they can adopt a fusiform pattern<sup>8</sup>. Cells have round hyperchromatic nuclei and a single nucleolus. The cytoplasm is poorly defined, scarce, of clear coloration and with irregular vacuoles resulting from intracellular deposits of glycogen<sup>3</sup>. There are frequent microcystic or pseudovascular spaces and occasionally Homer-Wright rosettes can be identified. High mitotic activity is usually found.

Immunohistochemical analysis usually shows vimentine +, 2-microglobuline+, CD 99+, and neural markers (S-100 protein, Leu-7, neurofilaments, especific neuronal enolase, sinaptofisine and PGP 9,5) positive.

Differential diagnosis is done with primary neoplasms such as: Merkel cell carcinoma, eccrine spiradenoma, lymphomas, clear cell sarcoma, rhabdomyosarcoma, malignant rhabdoid tumor, myoepithelial carcinoma, angiomatoid fibrous histiocytoma, poorly differentiated adnexal tumors and granulocytic sarcoma. Cutaneous metastases may derive from: osseous Ewing sarcoma, large cell neuroendocrine carcinoma, small cell lung carcinoma and neuroblastoma<sup>9</sup>.

Due to the variability of presentation and the lack of reported cases of cutaneous-subcutaneous Ewing Sarcoma, treatment still remains unclear. Most of the cases described in literature are treated as the rest of the ES tumors, with surgery when possible and combination with chemo or radiotherapy<sup>8,10,11</sup>. However, there is some evidence that shows a better prognosis of the cutaneous-subcutaneous ES compared to the ES, what makes us ask ourselves if we should do surgical resection without complementary therapies in selected patients. We present two cases treated only with wide margin resection surgery who are free of the disease 13 and 26 years after surgery.

### REFERENCES

- [1] Ewing J. Diffuse endothelioma of bone. Proc n Y Pathol Soc 1921;21:17.
- [2] Cash T, McIlvaine E, Segal MR, et al: Comparison of clinical features and outcomes in patientes with extraskelatal versus skeletal localized Ewing sarcoma: A report from the Children's Oncology Group. *Pediatr Blood Cancer* 63 (10):1771-9, 2016.
- [3] Jaime de Oliveira Filho, Ana Rita ferrante Mitidieri de Oliveira, Natalie Haddad, Ana Carolina franco Tebet, Kassila Nasser. Primary Cutaneous Ewing sarcoma-Case report. *Ann Bras dermatol*.2014;89(3):501-3.
- [4] M.Delaplace, C.Lhommet, G. De pinieux, B. Vergier, A. De Muret, L. Mchet. Primary cutaneous Ewing Sarcoma. *Br J of Dermatol*. 2012;166(4): 721-726.
- [5] Angervall L, Enzinger FM. Extraskelatal neoplasm resembling Ewing's sarcoma. *Cancer* 1975;36:240-51.
- [6] Edward Chow, Thomas E.Merchant, Alberto Pappo, Jesse J.Jenkins, Amit B. Shah and Larry E. Kun. *Int J.radiation Oncology* 2000; 46(2): 433-438
- [7] Susan L.Hasegawa, Jon M Davison, Arno Rutten, Jonathan A Fletcher and Christopher D.M. Fletcher. Primary cutaneous Ewing's sarcoma. Immunophenotypic and mmoleculat cytogenetic evaluation of five cases. *Am J Surg Pathol* 1998; 22(3):310-318.
- [8] R.Cabrera, P.Sánchez, M.A. Rodríguez. Tumor subcutáneo neuroectodérmico primitivo periférico. A propósito de un caso. *Actas Dermosifiliogr*.2008;99:555-9.
- [9] Machado I, Llombart B, Calabuig-Fariñas S, Llombart-Bosch A. Superficial Ewing's sarcoma family of tumors: a clinocopathological study with differential diagnoses. *J Cutan Pathol*. 2011;38:636-43.
- [10] Banrjee SS, Agbamu DA, Eyd BP. Clinicopathological characteristics of peripheral primitive neuroectodermal tumour of skin and subcutaneous tissue. *Histopathology*.1997;31:355-66.
- [11] Kourda M, Chatti S, Sfia M, Kraiem W, Ben Brahim E. Primary cutaneous extraskelatal Ewing's sarcoma. *Ann de Dermatol et Venereol* 2005; 132:986-9.

**Citation:** Maite López Deogracias, Francisco Martínez García, Karmele Mugika, Iñaki Arias-Camison. *Primary Cutaneous and Subcutaneous Neuroectodermal Tumor/Ewing's Sarcoma: Long-Term Survival after Local Excision. Archives of Oncology and Cancer Therapy*. 2018; 1(1): 26-28.

**Copyright:** © 2018 Maite López Deogracias, Francisco Martínez García, Karmele Mugika, Iñaki Arias-Camison. This is an open access article distributed under the Creative Commons Attribution License, which permits unrestricted use, distribution, and reproduction in any medium, provided the original work is properly cited.