

The Acute Renal Involvement in the Metabolic Syndrome

Gioacchino Li Cavoli, Pietro Tralongo, Giacomo Ferrantelli, Tancredi Vincenzo Li Cavoli, Mattia Palmeri, Angelo Ferrantelli, Franca Servillo, Angelo Tralongo

Nephrology Dialysis and Renal Transplantation Department, Civico and Di Cristina Hospital, Palermo Italy.

***Corresponding Author:** Gioacchino Li Cavoli, Nephrology Dialysis and Renal Transplantation Department, Civico and Di Cristina Hospital, Palermo Italy.

Abstract

The Metabolic Syndrome (MS) encompasses many metabolic abnormalities and the insulin resistance is the most significant denominator. The chronic kidney disease (CKD) is an emerging health problem but only few patients will reach the end stage renal disease. It exists an increasing strong association between MS and CKD but up to now the link between MS and CKD is unclear and there are few studies regarding the renal histology in MS. We describe an acute tubulointerstitial nephritis case, due to both infective and pharmacological aetiology, overlapping relevant histological changes (FSG, hyaline arteriosclerosis) in a patient with MS and previously normal renal function. Despite the severe vascular finding (elevated renal arterial resistive index), the patient recovered a normal renal function. We reviewed the kidney pathological studies in Metabolic Syndrome and we analyzed the principal renal histological pictures: glomerulomegaly, segmental glomerulosclerosis, obesity-related glomerulopathy. Despite the strong association, the renal involvement in MS has not been proven. A greater knowledge of the combination of histological renal changes in MS can help in the understanding of pathophysiological mechanisms of MS.

Keywords: Acute kidney injury, Metabolic Syndrome, Obesity.

INTRODUCTION

In USA the two thirds of adult population are suffering of overweight and one third are obese.(1) According the epidemiologic studies in other parts of the world the obesity is a public health problem. The Metabolic Syndrome (MS) encompasses many metabolic abnormalities. Triglyceride and high-density lipoprotein cholesterol high levels, fasting hyperglycemia, abdominal obesity and high blood pressure are the leading criteria and the insulin resistance is the most significant denominator of MS. (2) The chronic kidney disease (CKD) is an emerging health problem. Arterial Hypertension and Diabetes Mellitus are the most predictive factors of CKD but only few patients will reach the end stage renal disease.(3-4) Up to now it exists an increasing strong association between MS and CKD but the pathogenetic mechanisms inducing the renal involvement in MS are for the most part unknown. Whereas there are many studies regarding the link between MS and renal cell carcinoma, there are few studies regarding the renal histology in MS. (5) We describe a case of acute

tubulointerstitial nephropathy overlapping early diabetic nephropathy in a patient with MS and we review the kidney pathological studies in MS.

CASE DESCRIPTION

A 69-year-old Caucasian male, with previous normal renal function, suffering from Diabetes Mellitus, Obesity (BMI= 38 kg/m²), hypercholesterolemia, hypertension and Coronary Artery Disease started haemodialysis because of severe acute renal failure (oliguria, dyspnoea, Creatinine 10,3 mg/dL). His recent medical history revealed toothache, fever, myalgia and intake of non steroidal anti-inflammatory drugs. Renal ultrasonography showed no hydronephrosis, normal size and echogenicity but elevated renal arterial resistive index (RI=1). Instrumental and laboratory examinations detected pneumonia with bacteraemia from Staphylococcus Aureus. Immunological tests and other microbiological investigations were negative. Proteinuria was 1.2 g/24 h. Treatment included volume repletion, antibiotics and a 3-days course of corticosteroid therapy, with significant improvement

The Acute Renal Involvement in the Metabolic Syndrome

in his symptoms. Renal biopsy: among 22 glomeruli we detected focal segmental glomerulosclerosis (FSG) and glomerulomegaly (Fig. 1), arteriolar hyalinosis and severe interstitial inflammation (Figs. 2-3) without evidence for other causes of acute kidney injury. The immunofluorescence microscopy highlighted linear

staining for albumin and IgG along the glomerular basement membranes (Fig. 4). We diagnosed an acute tubulointerstitial nephropathy overlapping early diabetic nephropathy. The patient underwent to haemodialysis for two months up to recover of renal function (creatinine: 1,2 mg/dL, proteinuria 0.6 g/24 h).

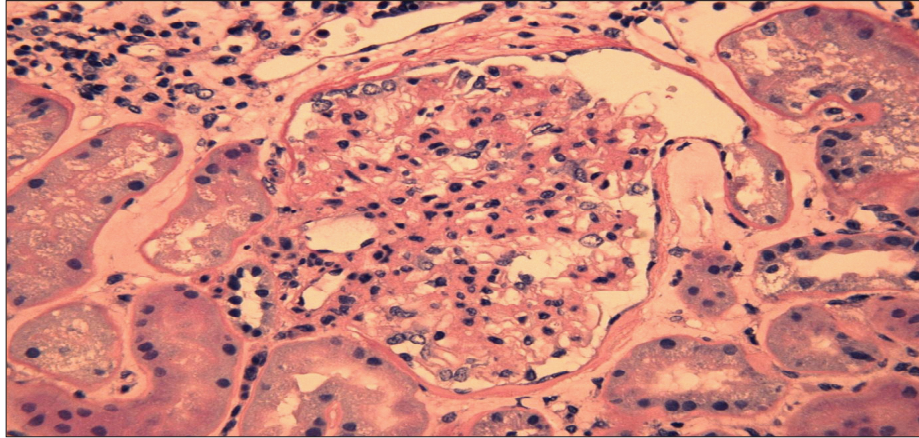


Fig1. Renal biopsy. Light microscopic: glomerulomegaly with arteriolar hyalinosis and a perihilar segmental sclerosis with synechiae formation and diffuse thickening of capillary basement membranes (H&E stain, x 40).

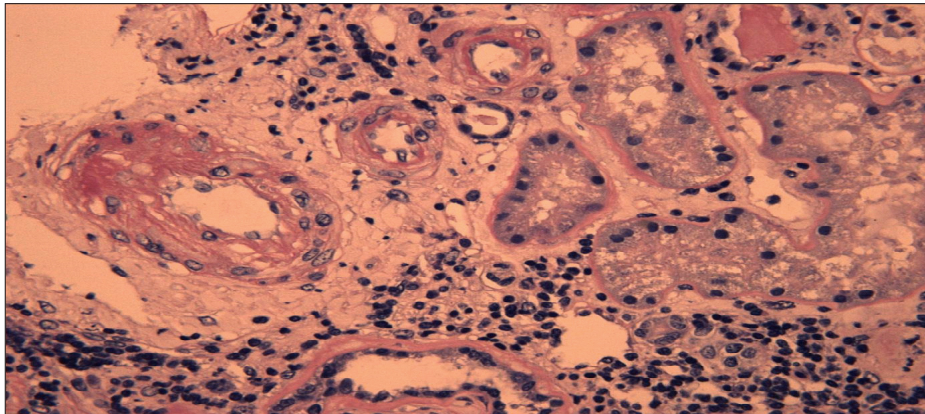


Fig2. Renal biopsy. Light microscopic: hyalinosis and marked thickening of medium and small arteries wall, due to intimal fibrosis with narrowing of the lumen, and inflammatory interstitial infiltrates with evidence of tubulitis (H&E stain, x 40).

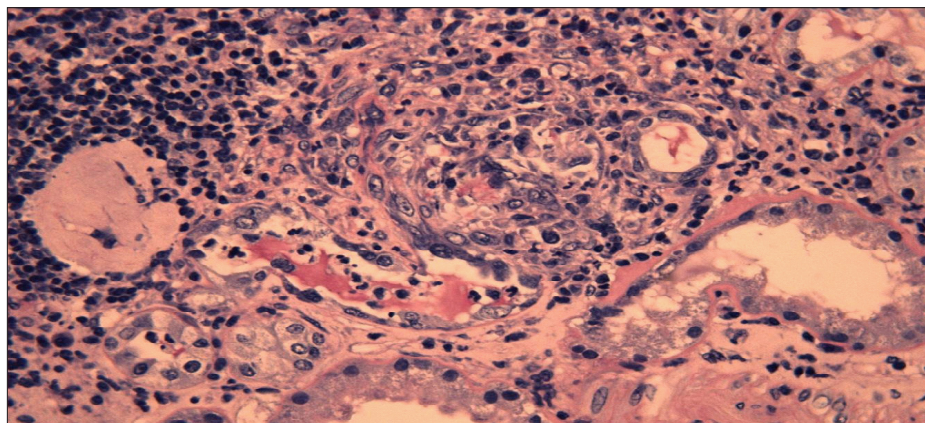


Fig3. Renal biopsy. Light microscopic: interstitial patchy granulomas (epithelioid histiocytes) with tubulitis (intramural and intraluminal neutrophils). (H&E stain, x 40).

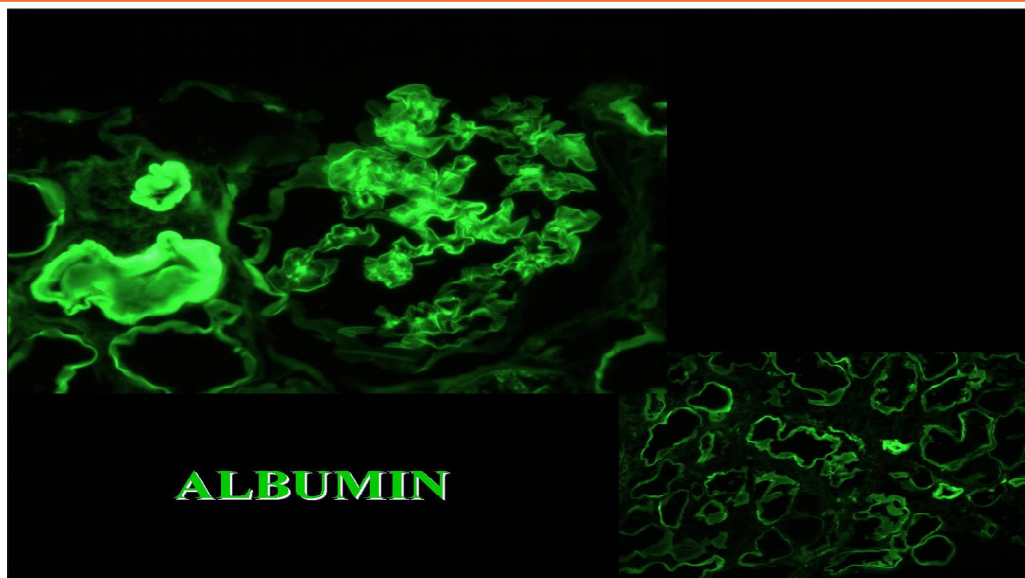


Fig4. Renal biopsy. Immunofluorescence: IgG and albumin in glomerular basement membranes.

DISCUSSION

The link between kidney disease and the MS is investigated by experimental and human histopathology. The study of Nagase M. indicated the podocyte injury as early key manifestation in a rat model of MS and nephropathy.(6) Experimental studies revealed an increase of glomerular size, a podocyte injury, expansion and sclerosis of the mesangium in genetically obese rats.(7) Longitudinal clinical studies in humans highlighted that glomerulomegaly is the histological characteristic change in glomerular hyperfiltration and the increase of albuminuria is the first clinical manifestation. In human pathology the obesity is associated with CKD; the glomerulomegaly, the proteinuria and the FSG define the obesity-related glomerulopathy (ORG). However, the pathophysiology of ORG and glomerulosclerosis is incompletely understood.(8-9) Since 1974 the glomerulomegaly and the FSG have been associated to severe obesity.(10) Later it became evident that ORG encompasses a continuum from glomerulomegaly to glomerulosclerosis.(11) On kidney biopsy the patients with massive obesity develop glomerulomegaly. In 95 obese patients with a mean BMI of 52 kg/m², the kidney biopsies reported a greater prevalence of glomerulomegaly, podocyte hypertrophy, mesangial cell proliferation and increase of mesangial matrix.(12) In 49 obese renal donors, compared to 41 non-obese controls, Rea DJ reported a larger glomerular planar surface area; the urinary microalbumin excretion and the patient weight correlated with this finding

but the obese renal donors did not show evidence of glomerulosclerosis.(13) Alexander MP examined 146 patients undergone to elective nephrectomy for renal cell carcinoma. Twelve of these had also MS. The tubular atrophy, the interstitial fibrosis, the arterial sclerosis, the global glomerulosclerosis and the segmental glomerulosclerosis, had a higher prevalence in these patients with MS compared with healthy subjects, suggesting evidence of vascular damage but the glomerular volume was not different between MS-patients and controls. (14) Kambham N. compared 71 patients with ORG and 50 patients with Idiopathic-FSG (I-FSG) without ORG. The Author detected FSG with glomerulomegaly in 57 and glomerulomegaly alone in 14 of ORG-patients and highlighted the significant overlap in clinical and pathologic features between ORG and I-FSG. (15) In the present case, we detected an acute tubulointerstitial nephritis, due to both infective and pharmacological aetiology, overlapping relevant histological changes (FSG, hyaline arteriosclerosis) in a patient with MS and previously normal renal function. Despite a severe vascular damage (elevated renal arterial resistive index), the patient recovered a normal renal function.

CONCLUSION

The relationship between MS and nephropathy is complex. Despite the strong epidemiologic association, the renal involvement in MS has not been proven. A greater knowledge of the combination of FSG and glomerulomegaly in MS can help in the understanding of pathophysiological mechanisms of this new emergency.

The Acute Renal Involvement in the Metabolic Syndrome

REFERENCES

- [1] Yanovski SZ, Yanovski JA. Obesity prevalence in the United States--up, down, or sideways? *N Engl J Med.* 2011; 364:987-9. doi: 10.1056
- [2] Grundy SM, Cleeman JI, Daniels SR, Donato KA, Eckel RH, Franklin BA et Al. Diagnosis and management of the metabolic syndrome: an American Heart Association/National Heart, Lung, and Blood Institute Scientific Statement. *Circulation.* 2005;112:2735-52.
- [3] Meguid El Nahas A, Bello AK. Chronic kidney disease: the global challenge. *Lancet.* 2005; 365:331-40.
- [4] Lameire N, Jager K, Van Biesen W, de Bacquer D, Vanholder R. Chronic kidney disease: a European perspective. *Kidney Int* 2005; 99:S30-8.
- [5] Zhang GM, Zhu Y, Ye DW. Metabolic syndrome and renal cell carcinoma. *World J Surg Oncol.* 2014;12: 236. doi: 10.1186/1477-7819-12-236.
- [6] Nagase M, Yoshida S, Shibata S, Nagase T, Gotoda T, Ando K et Al. Enhanced aldosterone signaling in the early nephropathy of rats with metabolic syndrome: possible contribution of fat-derived factors. *J Am Soc Nephrol.* 2006; 17:3438- 46.
- [7] O'Donnell MP, Kasiske BL, Cleary MP, Keane WF. Effects of genetic obesity on renal structure and function in the Zucker rat. II. Micropuncture studies. *J Lab Clin Med.* 1985;106: 605-10.
- [8] Hollenberg NK. Obesity and the kidney: why is the kidney at risk? *Kidney Int.* 2007; 71:187-8.
- [9] Hall JE, Kuo JJ, da Silva AA, de Paula RB, Liu J, Tallam L. Obesity-associated hypertension and kidney disease. *Curr Opin Nephrol Hypertens.* 2003 ;12:195-200.
- [10] Weisinger JR, Kempson RL, Eldridge FL, Swenson RS. The nephrotic syndrome: a complication of massive obesity. *Ann Intern Med.* 1974;81:440-7.
- [11] Eknoyan G. Obesity and chronic kidney disease. *Nefrologia.* 2011;31:397-403. doi: 10.3265/Nefrologia.pre2011.May.10963.
- [12] Serra A, Romero R, Lopez D, Navarro M, Esteve A, Perez N, Alastrue A, Ariza A. Renal injury in the extremely obese patients with normal renal function. *Kidney Int.* 2008;73:947-55. doi: 10.1038/sj.ki.5002796.
- [13] Rea DJ, Heimbach JK, Grande JP, Textor SC, Taler SJ, Prieto M et Al. Glomerular volume and renal histology in obese and non-obese living kidney donors. *Kidney Int.* 2006;70:1636-41.
- [14] Alexander MP, Patel TV, Farag YM, Florez A, Rennke HG, Singh AK. Kidney pathological changes in metabolic syndrome: a cross-sectional study. *Am J Kidney Dis.* 2009;53:751-9. doi: 10.1053/j.ajkd.2009.01.255.
- [15] Kambham N, Markowitz GS, Valeri AM, Lin J, D'Agati VD. Obesity-related glomerulopathy: an emerging epidemic. *Kidney Int.* 2001;59:1498-509.

Citation: Gioacchino Li Cavoli, Pietro Tralongo, Giacomo Ferrantelli, et.al. *The Acute Renal Involvement in the Metabolic Syndrome. Archives of Emergency Medicine and Intensive Care.* 2020; 2(2): 12-15.

Copyright: © 2020 Gioacchino Li Cavoli, Pietro Tralongo, Giacomo Ferrantelli, et.al. This is an open access article distributed under the Creative Commons Attribution License, which permits unrestricted use, distribution, and reproduction in any medium, provided the original work is properly cited.