

Z- Plasty: An Esthetic Approach for Maxillary Labial Frenum

Kriti Mehrotra¹, Satish Saswat Majhi^{1*}, Triveni M.G², D S Mehta²

¹Postgraduate student, Department of Periodontics, Bapuji Dental College and Hospital, Davangere, Karnataka.

²Professor, Department of Periodontics, Bapuji Dental College and Hospital, Davangere, Karnataka, India.

saswatmajhi02@gmail.com

***Corresponding Author:** Satish Saswat Majhi, Postgraduate student, Department of Periodontics, Bapuji Dental College and Hospital, Davangere, Karnataka, India.

Abstract

An aberrant frenum causes aesthetic and functional problems such as gingival recession both due to interference in the plaque control or due to a muscle pull, can cause midline diastema, which presents an aesthetic problem, compromise the orthodontic treatment and may lead to recurrence after the treatment. Loss of sulcus depth and ankyloglossia also lead to problems with speech articulation and swallowing. The management of such an aberrant frenum is accomplished by performing a frenectomy.

The present case report shows the removal of the abnormal maxillary labial frenum in a 25-year-old female patient through the Z-plasty technique.

Key words: Frenum, frenectomy, Z- plasty, hypertrophied frenum.

INTRODUCTION

A frenum is a mucous membrane fold comprises of connective tissue fibers that attach the lip and the cheek to the alveolar mucosa, the gingiva and the underlying periosteum.³The function of a maxillary frenulum is to provide stability to the upper lip. The maxillary labial frenum develops as a post-eruptive remnant of the ectolabial bands which connect the tubercle of the upper lip to the palatine papilla.⁴When the two central incisors erupt wide apart, bone can't be deposited inferior to the frenum, leads to a V-shaped bony cleft between the two central incisors and results in abnormal frenum attachment.⁵The frenum may jeopardize the gingival health when they are attached too closely to the gingival margin, either due to a muscle pull or due to interference in the plaque control which may lead to pocket formation and periodontal tissue destruction.

The labial frenal attachments have been classified by Placek et al in 1974 into

- 1) Mucosal – when the frenal fibres are attached up to the mucogingival junction.
- 2) Gingival – when the fibres are inserted within the attached gingiva.

3) Papillary – when the fibres are extending into the interdental papilla.

4) Papilla penetrating – when the frenal fibres cross the alveolar process and extend up to the palatine papilla.⁶

Prevalence of various frenal attachments includes, mucosal attachment - 46.5%, gingival attachment- 34.3%, papillary attachment-3.1%, papilla penetrating attachment - 16.1%.⁶

Hyperplastic frenum arise when there is a thick fibrous tissue attachment between the upper incisors and are often associated with a midline diastema, gingival recession, speech problems and other periodontal problems. The aberrant frena can be treated either by frenectomy or frenotomy. Frenectomy is the complete removal of the frenum, including it's attachment to the underlying bone, while frenotomy is the incision and the relocation of the frenal attachment.

Frenectomy can be accomplished either by the routine scalpel technique, electro-surgery or by using lasers. Both laser and electrosurgery are popular in soft tissue surgical procedures and recommended in patients with bleeding disorders as they offer advantage of minimal procedural bleeding and no need of suturing.

Z-Plasty: An Esthetic Approach for Maxillary Labial Frenum

Hence patient experiences less discomfort with minimal complications.

Conventional scalpel technique is preferred over laser and electrosurgery, where precise incision, flap reflection and mobilization are indicated.¹² Several surgical procedures have been implemented to treat abnormal frenum which include simple excision, Millers technique, V-Y plasty, Z-plasty, paralleling technique etc.^{4,14}

However frenectomy procedures frequently fail due to a hypertrophic scarring and high risk of recurrence. The risk of failure can be eliminated by using a technique known as Z-frenuloplasty/frenectomy, which is a soft tissue surgery used to lengthen a frenulum. It is an excellent procedure for both lengthening of contracted scars and/or changing the direction of scars for improved cosmetic effect.¹ It is a common tool of plastic surgeons. It works best when used for

hypertrophic thick frenula with a low insertion and a shallow sulcus.³

CASE PRESENTATION

A 25 years male patient was reported to the department of Periodontics, Bapuji Dental College & Hospital with a chief complaint of increasing midline space between two upper central incisors. The patient was systemically healthy. On intra oral examination it was found that there was a thick aberrant upper labial frenum extending into the interdental papilla between upper central incisors with short vestibule. (Fig-a) Tension test was found to be positive. (Fig-b) Case was considered for Z-plasty frenectomy. The patient was explained about the treatment procedure. Routine blood investigations were carried out and written consent for the procedure was obtained from the patient.³

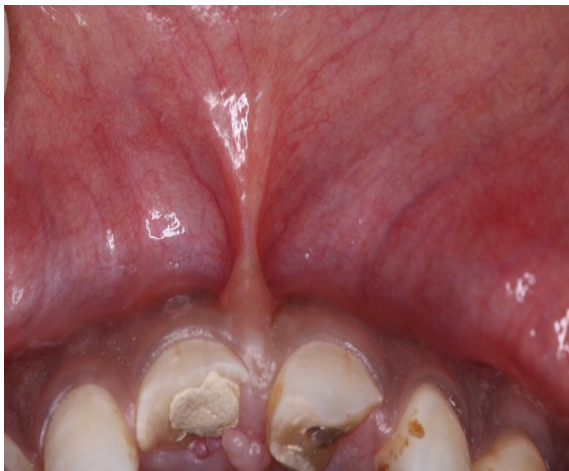

Fig-a

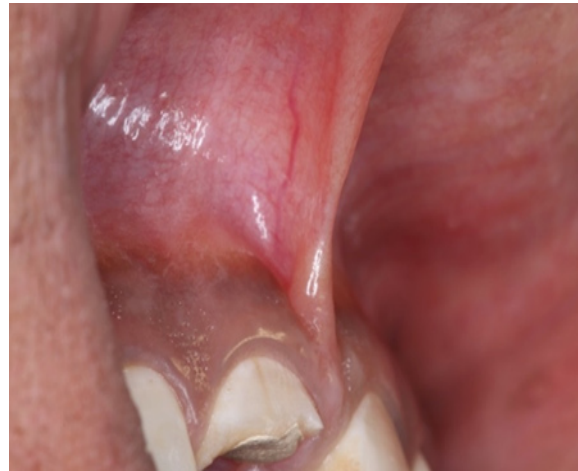

Fig-b

SURGICAL PROCEDURE

Phase-I periodontal therapy was carried out 1-week prior to the surgical procedure. Surgery was performed under aseptic conditions. Following administration of local anesthesia (2% Lignocaine with 1:80000 adrenaline) frenum and the surrounding area were assessed for adequate anesthesia. Surgical marker pen was used to mark the 'Z' shaped outline.⁷ (Fig-c) A vertical incision was given over the maxillary labial frenum using a 15c blade. (fig-2) Two lateral horizontal incisions of same length (approximately 1-2 cm) were placed at the coronal and apical end of vertical incision at an angle of 60° to the vertical incision (in opposite

direction), creating two triangular flaps of equal size and shape.⁷ (Fig-1, Fig-2) Adequate undermining of the surrounding tissues was performed to achieve proper mobilisation of the flaps. The two triangular flaps were then rotated and transposed to the opposite side of the apex of each flap (fig-3). Flaps were stabilized in the new position by interrupted sutures with (5-0) trulon suture material.³ (Fig-4, Fig-d) Post-operative instructions for wound care were given. Analgesics were prescribed as required and patient was advised 0.2% chlorhexidine gluconate mouth-rinse twice daily for 2 weeks. The sutures were removed after 1 week postoperative visit. (Fig-e)

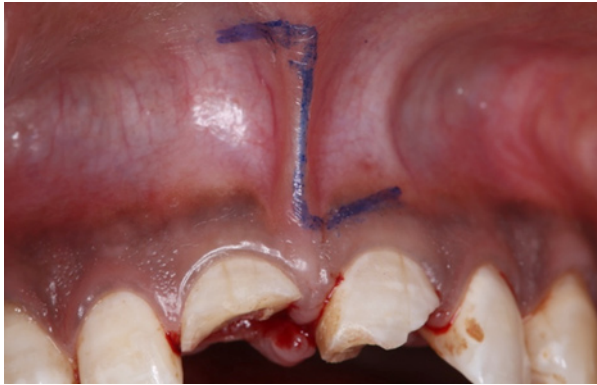

Fig-c

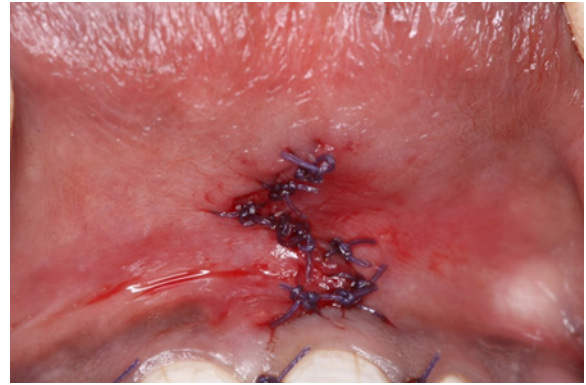


Fig-d

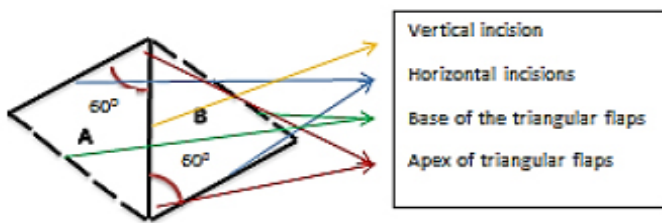


Fig-1 Design of triangular flap

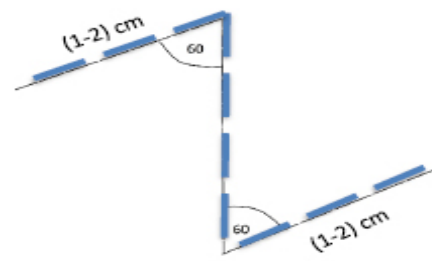


Fig-2 Incision lines

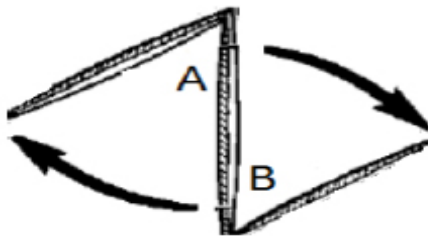


Fig-3 Transposition of flaps

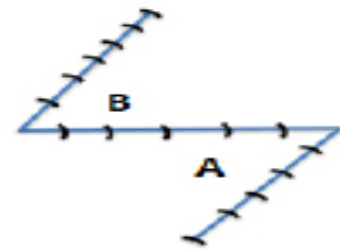


Fig-4 Final suture lines

POST-OPERATIVE FOLLOW-UP

One month postoperative healing was uneventful with no hypertrophic scar formation. (Fig-f)

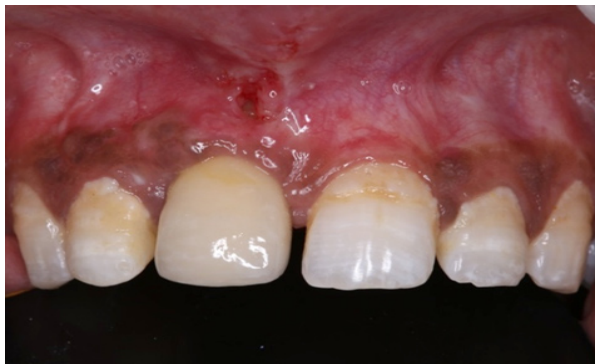

Fig-e

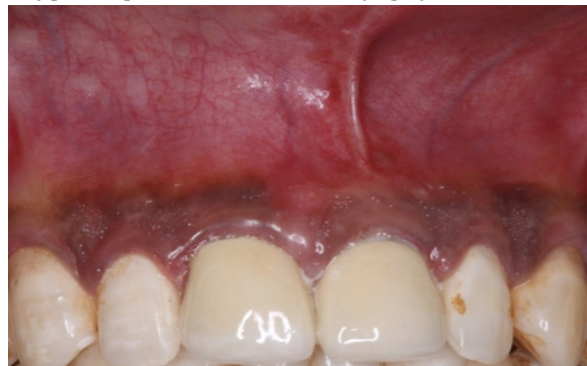

Fig-f

DISCUSSION

Various surgical techniques have been proposed for the correction of an aberrant labial frenum depending upon the type of frenal attachment. Among the commonly employed techniques include, the Miller's technique which was advocated by Miller PD in 1985 and proposed for the post-orthodontic diastema cases. Similarly V-Y plasty can be used for lengthening the localized area, like the broad frenum in the premolar-molar area. Another surgical technique given by Morselli et al. showed less tissue contracture, less scar formation and less healing time but it is a technique sensitive procedure. Similarly Bagga's technique provides a minimal scar tissue formation but it can be performed in patients with adequate attached gingiva.^{15, 16} However some of these techniques produce unsatisfactory results in case of broad thick hypertrophied frenum, for example a simple frenectomy by 'V' shaped incision leaves longitudinal surgical incision and scarring. This may lead to periodontal problems because of the damaged gingiva and an unaesthetic appearance.

The unique Z-plasty technique is indicated in broad, thick hypertrophic frenum associated with midline diastema and a short vestibule.

The basic idea of the z-plasty was best described by Limberg.¹⁰

The main objectives of the z-plasty are ¹⁰

1. Elongate tissue, usually along a to release tension and enable mobility
2. Narrow a scar in its transverse direction
3. Rearrange the direction of a scar, favourably along pre-existing relaxed skin tension lines
4. Disperse scar tissue in favor of cosmesis
5. Soften and thin scar tissue

This procedure enables the clinician to remove the fibrous band of frenum as well as helps in vertical lengthening of the vestibule. The Z pattern is effective as it promotes the redistribution of tension on the skin as well as the wound and helps in healing along the skin lines. It helps in minimising scar formation and has a camouflaging effect.² While doing Z-plasty, the original scar is used as the common diagonal. From each end of this common diagonal, two arms of same length (in order to avoid puckering) are extended in

opposite directions. An angle of 60° is formed between the arm and the common diagonal.⁹

Two components determine the performance and tissue lengthening of Z-plasty.^{8,13}

1. The size of the angle
2. The length of the centre line of 'Z', called as the common diagonal (common limb or common member).⁸

This angle determines the degree of lengthening of the tissue, the larger the angle, the greater the length gain. Classic 60° Z-plasty lengthens scars by 75% and scar direction changes to 90°. Similarly 45° lengthens the scar by 50%, 30° lengthens scars by 25%, angle of 75° by 100% and an angle of 90° by 125%. Reason for taking 60° Z-plasty is because of easier transposition of triangular flaps with less tension to the flaps. Angle more than 60° is avoided as it increases the tension during the transposition and closure of flaps. An angle < 60° though easier to transpose. So the Z-plasty procedure avoids the poor results that are associated with tissue scarring and permits better redistribution of the scar contracture lines.^{8,13}

CONCLUSION

The technique presented here provides many advantages, such as minimal scar formation, excellent color matching, reducing the risk of tissue contractures and healing by primary intention. This technique is reliable, easy to perform and provides excellent esthetic result. Overall the Z-plasty procedure is considered to be safe, Cost effective and results in better functional and aesthetic appearance.

REFERENCE

- [1] Burke M. Z-plasty. How, when and why. Australian family physician. 1997; 26(9):1027-9.
- [2] Sinha J, Kumar V, Tripathi AK, Saimbi CS. Untangle lip through Z-plasty. BMJ Case Rep. 2014; 2014.
- [3] Bagchi SS, Sarkar P, Bandyopadhyay P. Management of Aberrant Frenum: series of cases. Annals of Applied Bio-Sciences. 2016; 3(2):C34-39.
- [4] DeviShree SK, Shubhashini PV. Frenectomy: A review with the reports of surgical techniques. J Clin Diagn Res. 2012; 6(9):1587.
- [5] Huang WJ, Creath CJ. The midline diastema: a review of its etiology and treatment. Pediatric dentistry. 1995; 17:171-171.

Z-Plasty: An Esthetic Approach for Maxillary Labial Frenum

- [6] Mirko P, Miroslav S, Lubor M. Significance of the labial frenum attachment in periodontal disease in man. Part 1. Classification and epidemiology of the labial frenum attachment. J periodontol. 1974; 45(12):891-894.
- [7] Dusara K, Mohammed A, Nasser NA. Z-frenuloplasty: A better way to 'untangle'lip and tongue ties. J Dent Oral Disord Ther. 2014; 2(1):4.
- [8] Garg S, Dahiya N, Gupta S. Surgical scar revision: an overview. Journal of cutaneous and aesthetic surgery. 2014; 7(1):3.
- [9] Saiani GA, Janki P, Amin. Am FÜIU Phyician. 2003; 67:2329-32.
- [10] Hundeshagen G, Zapata-Sirvent R, Goverman J, Branski LK. Tissue Rearrangements: The Power of the Z-Plasty. Clinics in plastic surgery. 2017 Oct 1; 44(4):805-12.
- [11] Cunha RF, Silva JZ, Faria MD. A clinical approach of ankyloglossia in babies: a report of two cases. J Clin Pediatr Dent 2008; 32:277-82.
- [12] Gontijo I, Navarro RS, Naypek P, Ciamponi AL, Haddad AE. The application of diode and Er:YAG lasers in labial frenectomies in infants. J Dent Child 2005; 72(1):10-5.
- [13] Matsumoto, E. A., Liang, H., Mahadevan, L. Topology, Geometry, and Mechanics of Z -Plasty. Physical Review Letters, 2018; 120(6).
- [14] Abullais SS, Dani N, Ningappa P, Golvankar K, Chavan A, Malgaonkar N, Gore A. Paralleling technique for frenectomy and oral hygiene evaluation after frenectomy. J Indian Soc Periodontol. 2016; 20(1):28.
- [15] Morselli P, Vecchiet F, Marini I. Frenuloplasty by triangular flap. Oral Surg Oral Med Oral Pathol Oral Radiol Endod 1999; 87(2): 142-144.
- [16] Bagga S, Bhat M, Bhat GS, Thomas BS. Esthetic management of the upper labial frenum: A novel frenectomy technique. Quintessence Int 2006; 37(10): 819-823.

Citation: Kriti Mehrotra, Satish Saswat Majhi, Triveni M.G, D S Mehta. Z-Plasty: An Esthetic Approach for Maxillary Labial Frenum. Archives of Dentistry and Oral Health. 2018; 1(2): 13-17.

Copyright: © 2018 Kriti Mehrotra, Satish Saswat Majhi, Triveni M.G, D S Mehta. This is an open access article distributed under the Creative Commons Attribution License, which permits unrestricted use, distribution, and reproduction in any medium, provided the original work is properly cited.