

# What has Changed in the Diagnostic Approach to Arrhythmogenic Cardiomyopathy after Ecg Amplitude Criteria in Lead AvR and V1?

Stefan Peters

St. Elisabeth Hospital gGmbH Salzburg, Germany.

H.u.S.Peters@t-online.de

**\*Corresponding Author:** Prof. Dr. med. Stefan Peters, Chief Cardiologist, St. Elisabeth Hospital gGmbH, Liebenhaller Salzburg, Germany.

## Abstract

In 2016 most relevant ECG criteria for the diagnosis of arrhythmogenic cardiomyopathy has been published. The amplitude of inverted T-waves in lead aVR (1) and V1 (2) for the evaluation of arrhythmogenic cardiomyopathy was published and contributed to the ECG diagnosis of arrhythmogenic cardiomyopathy significantly.

In 2017 both amplitude criteria were taken together for optimisation of ECG diagnosis even in cases without right ventricular enlargement and aneurysms (3, 4).

For exclusion of arrhythmogenic cardiomyopathy the ECG morphology of lead aVR (5) and the amplitude of inverted T-waves of 2mm or less are extremely helpful.

**Keywords:** Arrhythmogenic cardiomyopathy; cardiac sarcoidosis; cardiac MRI; lead aVR; lead V1; syncope

## CASE REPORT NO. 1

A 19-year old male patient was admitted to hospital because of a syncope.

The standard ECG revealed sinus rhythm, localized right precordial QRS prolongation and an epsilon wave in lead V1 and V2. In lead aVR a large Q wave of 4mm, a R wave of 3mm, and a inverted T-wave with an amplitude of 3mm was striking. Right precordial T-wave inversion could be excluded (figure 1).

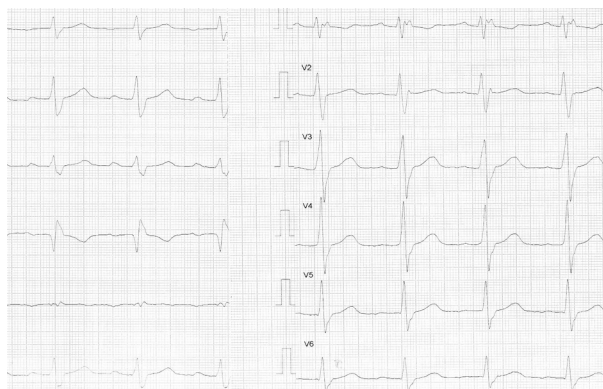


Figure 1. 12-channel ECG suggesting cardiac sarcoidosis

Coronary arteries were normal, the left ventricle revealed apical akinesia, and the right ventricle was dilated and showed outpouchings at the triangle of dysplasia – in the inferior, apical and RVOT segment. The diagnosis of arrhythmogenic biventricular cardiomyopathy was made.

Holter monitoring revealed a short complete atrioventricular block for some seconds, but no ventricular tachycardia. An event recorder was implanted.

Further examinations to proof cardiac sarcoidosis could not be done, as the patient left the hospital by his own request.

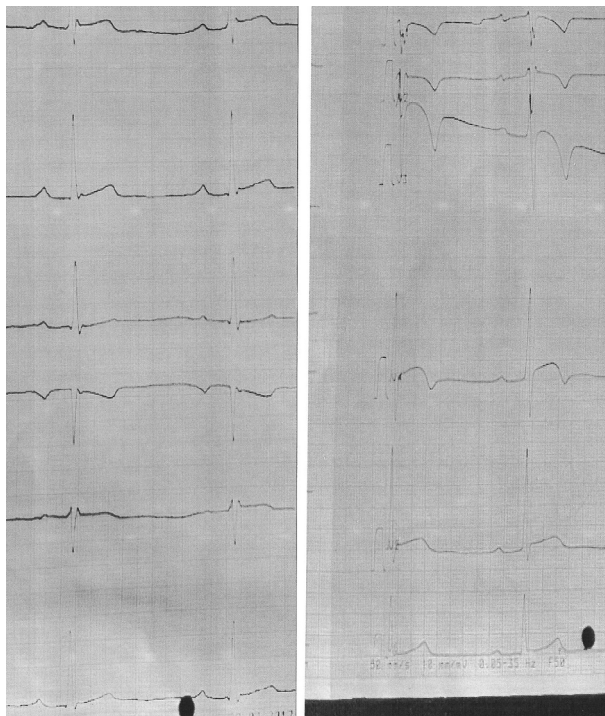
## CASE REPORT NO. 2

A 21-year old male professional soccer player from Ivory coast was admitted to hospital because of a syncope during soccer playing.

The standard ECG revealed sinus rhythm, localized right precordial QRS prolongation, right precordial T-wave inversions, and epsilon waves in lead V1 and

## What has Changed in the Diagnostic Approach to Arrhythmogenic Cardiomyopathy after Ecg Amplitude Criteria in Lead AvR and V1?

V2. In lead aVR a large Q wave of 4mm, a R wave of 2mm, and inverted T-wave with an amplitude of 2mm were found (figure 2).



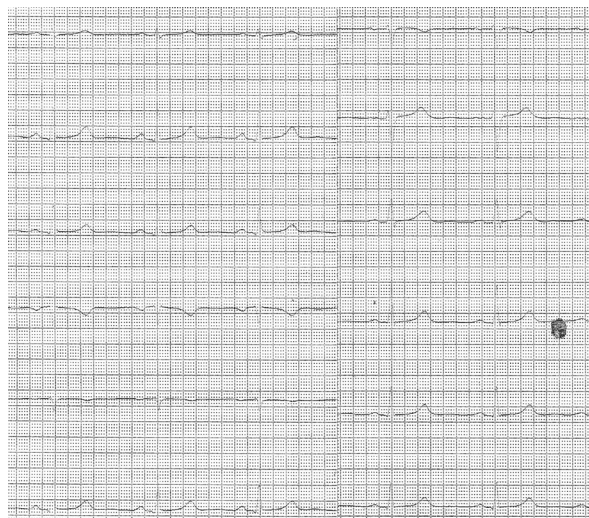**Figure 2.** Typical ECG in arrhythmogenic cardiomyopathy proven by cardiac MRI

A cardiac MRI was performed 1 year ago. The left ventricle was not dilated and normally contracting. The right ventricle was dilated with hypokinesia of inferior and apical region. A late enhancement could be found in the inferior segment of the left ventricle, thus perimyocarditis was assumed.

### CASE REPORT NO.3

A 26-year old female patient, member of a large Italo-german family with known arrhythmogenic cardiomyopathy caused by transforming growth factor beta 3, was tested genotype-positive, but was phenotype-negative. Her ECG revealed no T-wave inversions and no epsilon waves in right precordial leads and no terminal activation delay which could be demonstrated in the other family members who were genotype- and phenotype-positive.

In lead aVR the amplitude of Q wave was 4mm, the amplitude of R wave 2mm and the amplitude of inverted T waves in lead aVR was 2mm. The amplitude of inverted T-wave in lead V1 was 1mm (figure 3).



**Figure 3.** Typical changes in lead aVR and negative T-wave in lead V1 in a phenotype-negative female patient

### DISCUSSION

Arrhythmogenic cardiomyopathy and cardiac sarcoidosis are not easy to differentiate. In the case no. 1 the diagnosis of arrhythmogenic biventricular cardiomyopathy was made, but the appearance of lead aVR excludes the diagnosis. The fact that there was a short complete atrioventricular block for some seconds in holter monitoring is in favour of cardiac sarcoidosis often requiring pacemaker implantation. The patient was lost for event recorder controlling and was controlled otherwise. In many scenarios arrhythmogenic cardiomyopathy can be excluded and the diagnosis of lung embolism (6), coronary heart disease (7) and cardiac sarcoidosis (8) can be made although localized right precordial QRS prolongation, right precordial T-wave inversion and right precordial epsilon waves are reported.

In case no.2 perimyocarditis was the diagnosis analyzed by cardiac MRI one year ago during the first event of syncope. The analysis of lead aVR, however, shows that arrhythmogenic cardiomyopathy actually is the right diagnosis. Late enhancement of the inferior segment of the left ventricle is a sign of arrhythmogenic cardiomyopathy with inferior left ventricular involvement. A diffuse late enhancement of the left ventricle as in perimyocarditis was not described. The patient was asked not to perform professional soccer for half a year. A primarily prophylactic ICD implantation was not performed.

## What has Changed in the Diagnostic Approach to Arrhythmogenic Cardiomyopathy after Ecg Amplitude Criteria in Lead AvR and V1?

In case no.3 the young female patient had positive ECG findings in lead aVR and possibly in lead V1, genotypically confirming the diagnosis of arrhythmogenic cardiomyopathy without any symptoms. She is still at risk of sudden cardiac death although other ECG criteria are missing.

With the help the amplitude criteria of inverted T-waves in lead aVR and V1 arrhythmogenic cardiomyopathy can be excluded as in case no.1 and confirmed as shown in case no.2 and no.3 with therapeutic options.

Localized right precordial QRS prolongation, terminal activation delay, right precordial T-wave inversions and right precordial epsilon waves do not confirm in all cases arrhythmogenic cardiomyopathy, but amplitude criteria in lead aVR and V1 provide better approval of arrhythmogenic cardiomyopathy in some cases. The importance of lead aVR and the role of bipolar ECG in lead V1 in the diagnosis of arrhythmogenic cardiomyopathy was documented elsewhere (9, 10).

### REFERENCES

- [1] Peters S. Low amplitude of inverted T-waves in lead aVR characterise patients with arrhythmogenic cardiomyopathy. *Int J Cardiol* 2016; 220: 201
- [2] Peters S. Electrocardiographic morphology in right precordial T waves in arrhythmogenic right ventricular cardiomyopathy: *Int J Cardiol* 2016; 214: 228
- [3] Peters S. The role of lead aVR and lead V1 in the diagnosis of arrhythmogenic cardiomyopathy in apparently normal hearts. *Multidisc Cardiovasc Annal* 2017; 8: e11078
- [4] Peters S. Amplitude of inverted T-waves in arrhythmogenic cardiomyopathy in special right ventricular leads. *SM J Cardiovasc Dis.* 2017; 2: 1009
- [5] Peters S. Clinical importance of lead aVR in arrhythmogenic cardiomyopathy. *Int J Cardiol* 2014; 176: 508 - 9
- [6] Peters S. Confusion with the diagnosis of acute pulmonary embolism and arrhythmogenic right ventricular cardiomyopathy. *Int J Cardiol* 2016; 203: 317
- [7] Peters S. Electrocardiography not always confirm arrhythmogenic right ventricular cardiomyopathy – the value of lead aVR. *Int J Cardiol* 2014; 172: e34 - 5
- [8] Peters S. Differential diagnosis of arrhythmogenic right ventricular cardiomyopathy and granulomatous myocarditis by advanced ECG analysis. *Int J Cardiol* 2016; 209: 255 - 7
- [9] Nunes de Alencar Neto J, Baranchuk A, Bayes-Genis A, Bayes de Luna A. Arrhythmogenic right ventricular dysplasia/cardiomyopathy: an electrocardiogram-based review. *Europace* 2017; 0: 1 - 10
- [10] Batchvarov VN, Bastiaenen R, Posterna PG, Clark EN, Macfarlane PW, Wilde AA, Behr ER. Novel electrocardiographic criteria for the diagnosis of arrhythmogenic right ventricular cardiomyopathy. *Europace* 2016; 18: 1420 - 6

**Citation:** Stefan Peters. *What has Changed in the Diagnostic Approach to Arrhythmogenic Cardiomyopathy after Ecg Amplitude Criteria in Lead AvR and V1?*. *Archives of Cardiology and Cardiovascular Diseases.* 2018; 1(1): 29-31.

**Copyright:** © 2018 Stefan Peters. This is an open access article distributed under the Creative Commons Attribution License, which permits unrestricted use, distribution, and reproduction in any medium, provided the original work is properly cited.