

Successful Stent Implantation in a Marginal Branch of the Circumflex Artery via Right Internal Mammary Artery in Transradial Technique

Stefan Peters

St. Elisabeth Hospital gGmbH Salzgitter, Germany.

H.u.S.Peters@t-online.de

***Corresponding Author:** Prof. Dr. med. Stefan Peters, Chief Cardiologist, St. Elisabeth Hospital gGmbH, Liebenhaller Salzgitter, Germany.

Abstract

Intervention of peripheral branches via right internal mammary artery in transradial approach is often difficult. The choice of a perfect guiding catheter is a matter of success. Here we describe a successful drug eluting stent implantation into a marginal branch via right internal mammary artery with a Shepherd's Crook guiding catheter.

Key words: Transradial approach, marginal branch, drug-eluting stent, circumflex artery

A 76-year male patient suffered from unstable angina pectoris after bypass operation 11 years ago. Troponin value was positive, ECG without ST elevation, but with ST decrease in left ventricular hypertrophy.

11 years ago left internal mammary artery was adapted to left anterior descending coronary artery, right internal mammary artery to a second marginal branch and venous grafts to diagonal and a first marginal branch. Right coronary artery developed proximal high grade stenosis 6 years ago and was stented successfully. 2 years later the stent in the right coronary artery developed in-stent restenosis at the upper part of the stent and an additional stent was implanted. During coronary artery catheterization 2015 both venous grafts were occluded. In a transfemoral approach both left and right internal mammary arteries were reached non-selectively with a vague appearance.

By right and left transradial approach left internal mammary to left anterior descending coronary artery had no stenoses, and right coronary artery had a good result after double stent implantation. Right internal mammary to the second marginal branch was reached semi-selectively and revealed subtotal stenosis of the native marginal branch.

In a second attempt several guiding catheters were tried: IMA catheter, IMA-D catheter, AL-1 catheter and

multipurpose catheter. Only a Shepherd's Crook 3,5 catheter was inserted distally from the origin of right internal mammary artery, counterclockwise rotated and tied back with selective intubation of the origin.

A Galeo F guide wire was inserted behind high grade stenosis and drug eluting stent implantation was done successfully.

DISCUSSION

Several transfemoral and transradial attempts were reported in the literature (1, 2) in order to reach right internal mammary artery for dilatation and stent implantation in coronary arteries.

In this case it was possible in a former attempt to reach left anterior descending coronary artery and marginal branch of the circumflex artery only non-selectively in a transfemoral approach.

By right and left transradial approach it was possible to reach left anterior descending coronary artery via left internal mammary artery selectively and marginal branch non-selectively via right internal mammary artery.

Only a Shepherd's Crook 3,5 guiding catheter was able to reach selectively the origin of the right internal mammary artery after counterclockwise rotation and

Successful Stent Implantation in a Marginal Branch of the Circumflex Artery via Right Internal Mammary Artery in Transradial Technique

pull back. Without any complications drug eluting stent could be implanted.

In 1999 a successful stent implantation in a marginal branch via right internal mammary artery with a Shepherd's Crook guiding catheter was described (1). Now a successful drug eluting stent implantation in transradial technique with the same guiding catheter is reported. Not in all patients a standardized procedure

is able to reach right internal mammary artery. Due to patients' characteristics the approach differs to a high degree.

With diverse techniques – transradial, transbrachial (3) and transfemoral – in nearly all patients the goal of successful stent implantation can be reached with different guiding catheter equipment.

LEGENDS

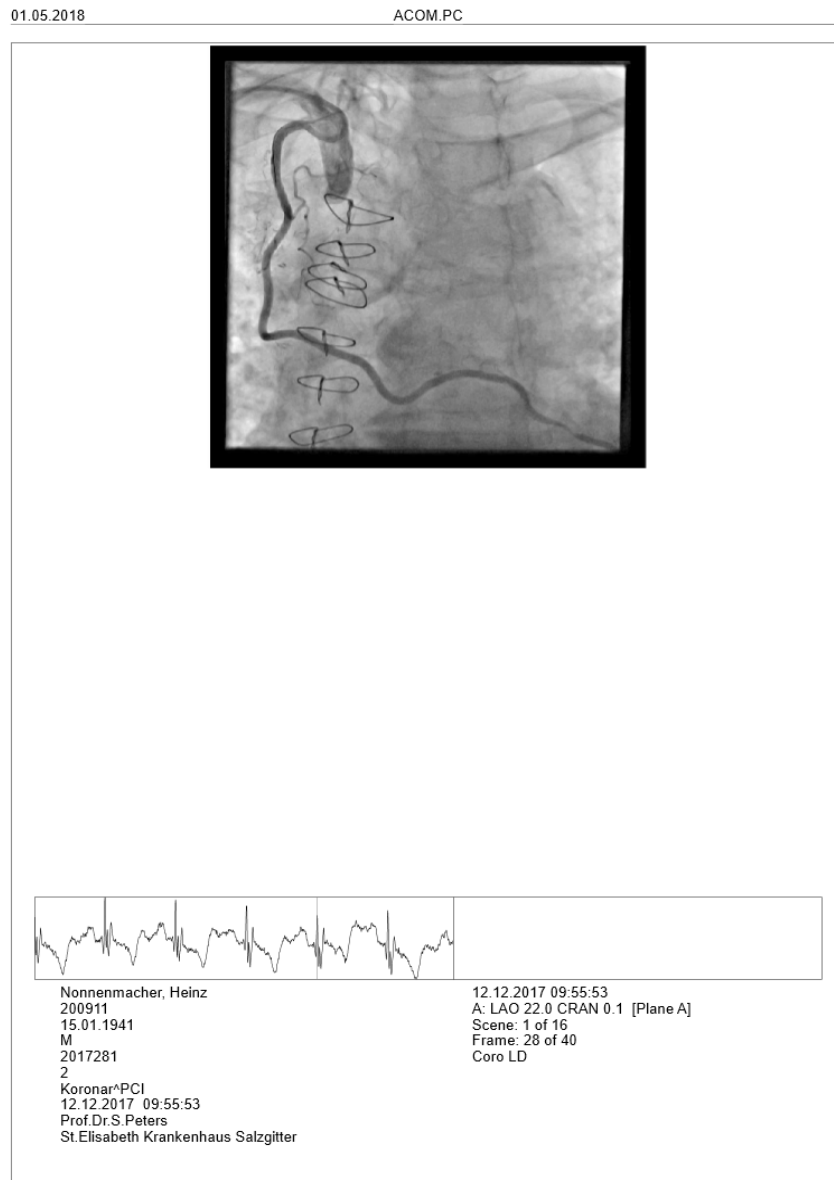


Figure 1. Selective positioning of the Shepherd's Crook guiding catheter in the ostium of the right mammary artery

Successful Stent Implantation in a Marginal Branch of the Circumflex Artery via Right Internal Mammary Artery in Transradial Technique

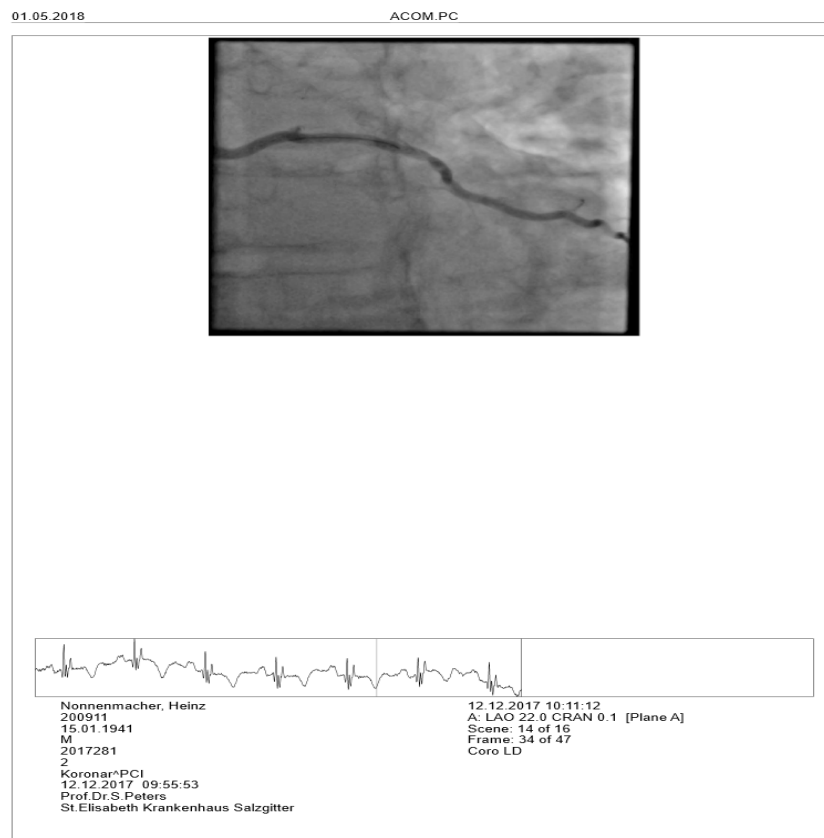


Figure 2. Final result after everolimus drug-eluting stent implantation in the marginal branch of the circumflex artery

REFERENCES

- [1] Peters S, Trümmel M, Steffen H, Götting B. Successful direct stent implantation into a marginal branch of the circumflex artery via the right internal mammary artery in a transfemoral approach. *J Invasive Cardiol* 1999; 11: 75 – 8
- [2] Kim MH, Cha KS, Kim HJ, Kim JS. Bilateral selective interal mammary artery angiography via right radial approach: clinical experience with the newly designed Yumiko catheter. *Catheter Cardiovasc Interv* 2001; 54: 19 – 24
- [3] The YUMIKO catheter: a useful tool for angiography of the right internal mammary artery via a right brachial approach.

Citation: Stefan Peters. Successful Stent Implantation in a Marginal Branch of the Circumflex Artery via Right Internal Mammary Artery in Transradial Technique. *Archives of Cardiology and Cardiovascular Diseases*. 2018; 1(1): 11-13.

Copyright: © 2018 Stefan Peters. This is an open access article distributed under the Creative Commons Attribution License, which permits unrestricted use, distribution, and reproduction in any medium, provided the original work is properly cited.